

Endovascular Treatment of Type II Endoleak Following Thoracic Endovascular Aortic Repair for Thoracic Aortic Aneurysm: Case Report of Squeeze Technique to Reach the Aneurysmal Sac¹

흉부 대동맥류의 혈관 내 동맥류 재건술(Thoracic Endovascular Aortic Repair) 후 발생한 Type II Endoleak에 대한 혈관 내 치료: Squeeze Technique을 이용한 동맥류 접근방법¹

Hyun Jung Kang, MD¹, Chang Won Kim, MD¹, Tae Hong Lee, MD¹, Seung Hwan Song, MD², Chung Won Lee, MD², Sung Woon Chung, MD²

Departments of ¹Radiology, ²Thoracic and Cardiovascular Surgery, Pusan National University Hospital, School of Medicine, Pusan National University, Busan, Korea

Type II endoleaks are common after thoracic endovascular aortic repair (TEVAR). Various strategies are introduced to manage type II endoleaks, such as the use of coils, plugs, or liquid embolic agents (histoacryl, thrombin, onyx, etc.) through a transarterial approach or a direct puncture of the aneurysmal sac. We herein report a case of a type II endoleak caused by reverse blood flow through intercostal artery after TEVAR which was successfully treated with n-butyl cyanoacrylate (histoacryl)-lipiodol mixture by a squeeze technique to reach the aneurysmal sac using a microcatheter.

Index terms

Thoracic Aortic Aneurysm

Thoracic Endovascular Aortic Repair

Type II Endoleak

INTRODUCTION

Thoracic endovascular aortic repair (TEVAR) has been accepted as an alternative to open surgical repair in certain groups of patients (1). A potential complication caused by persistent or recurrent flow into the aneurysm sac is known as endoleak which can be classified to four types (2). Complex type II endoleaks occur due to persistent reverse blood flow through branch vessels (3). Common sites of type II endoleaks are the left subclavian artery and intercostal arteries with occasionally bronchial arteries (4). Arterial pressure in type II endoleaks is transmitted to the aneurysm sac, causing sac expansion. In this situation, patients remain at risk of aneurysm rupture (3). Treatment of type II endoleaks requires elimination of blood flow through branch vessels to relieve the aneurysm sac from sys-

temic pressure (3). Various methods are introduced to manage type II endoleaks, such as the use of coils, plugs, or liquid embolic agents (histoacryl, thrombin, onyx, etc.) through a transarterial approach or a direct puncture of the aneurysmal sac. We herein present a case of type II endoleak caused by reverse blood flow from the intercostal artery after TEVAR which was successfully treated with the use of histoacryl-lipiodol mixture by a squeeze technique to reach the aneurysmal sac using a microcatheter.

CASE REPORT

A 77-year-old woman who was admitted to our hospital due to coronary artery occlusive disease presented diffused abdominal and chest pain. A 6.5-cm saccular aneurysm with discontin-

Received June 27, 2014; Accepted October 11, 2014

Corresponding author: Chang Won Kim, MD

Department of Radiology, Pusan National University Hospital, School of Medicine, Pusan National University, 179 Gudeok-ro, Seo-gu, Busan 602-739, Korea.

Tel. 82-51-240-7354 Fax. 82-51-244-7534

E-mail: radkim@nate.com

This is an Open Access article distributed under the terms of the Creative Commons Attribution Non-Commercial License (<http://creativecommons.org/licenses/by-nc/3.0>) which permits unrestricted non-commercial use, distribution, and reproduction in any medium, provided the original work is properly cited.

uous intimal calcification of the descending thoracic aorta was found. She had increased C-reactive protein level at 19.02 mg/dL and leukocytosis ($19.34 \times 10^3/\mu\text{L}$), suggesting mycotic aneurysm (Fig. 1A). Broad-spectrum antibiotic therapy was started immediately. Due to her underlying disease and refusal to open surgery, TEVAR was performed with 30 mm diameter and 117 mm length stent-grafts (Valiant Captivia Medtronic, Minneapolis, MN, USA). After stent-graft placement, delayed filling of aneurysmal sac with reverse blood flow from the left seventh intercostal artery was found, suggesting type II endoleak (Fig. 1B, C). Follow-up postprocedural CT revealed the same findings (Fig. 1D). A secondary intervention was planned for this patient. One week after TEVAR, the patient had small amounts of hemoptysis. There was no definite increase in aneurysm size. Small amounts of hemoptysis suggested fistula between the aneurysm and the bronchus without underlying lung disease. Thus, thoracic aortography was performed. Thoracic aortography showed persistent type II endoleak related to retrograde filling of the aneurysmal sac with reverse blood flow from the left seventh intercostal artery (Fig. 2A). A small triangular space (free graft skirt) between a distal free graft wall of the stent-graft and the aorta was selected by a 5.0-Fr Davis-Berenstein catheter (Cook Incorporated, Bloomington, IL, USA) and a 0.35-inch hydrophilic J-tip wire (Terumo, Tokyo, Japan). The 5.0 F Davis-Berenstein catheter (Cook Incorporated, Bloomington, IL, USA) was then exchanged with a 5.0-Fr Straight catheter (Cook Incorporated, Bloomington, IL, USA) to keep a secure position during a microcatheter manipulation. A 2.0-Fr microcatheter (Progreat®; Terumo, Tokyo, Japan) with a 0.18-inch guide wire (Transend®; Boston Scientific, Boston, MA, USA) were advanced into the aneurysmal sac between the distal end of the stent-graft and the aortic wall by squeezing the very narrow space (Fig. 3). Cavitogram revealed opacification of the aneurysmal sac and efferent intercostal arteries (Fig. 2B, C). The aneurysmal sac was successfully embolized with a mixture of histoacryl (3 mL) and lipiodol (9 mL) at a dilution of 1:3 without selecting intercostal arteries (Fig. 2D). Postembolization angiography showed complete resolution of the endoleak (Fig. 2E). Follow-up CT angiography taken at 9 days after embolization showed that the size of the saccular aneurysm of the descending thoracic aorta was unchanged, but the endoleak was resolved (Fig. 2F, G). The patient did not complain of hemoptysis.

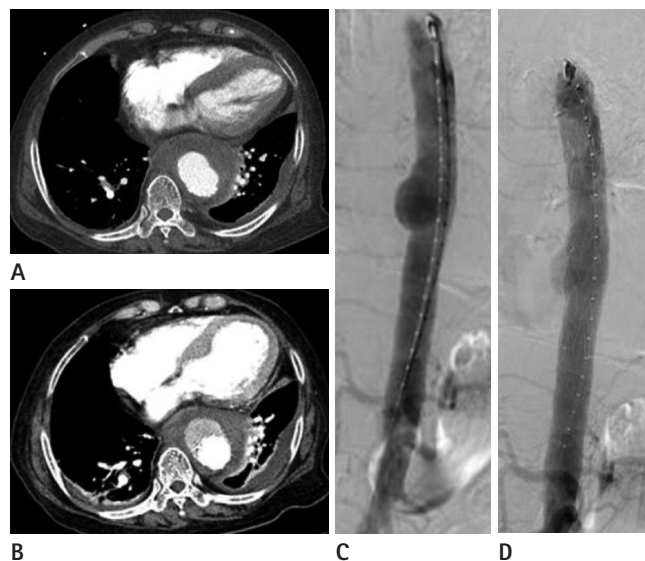


Fig. 1. A-77-year-old woman with thoracic aortic aneurysm. **A.** CT angiography (CTA) image shows a 6.5-cm saccular aneurysm with discontinuous intima calcification in the descending thoracic aorta. **B.** Thoracic aortogram shows a 6.5-cm saccular aneurysm at the mid-thoracic level. **C.** Thoracic aortogram following thoracic endovascular aortic repair shows a delayed filling of the aneurysmal sac with blood flow from the left seventh intercostal artery, suggesting a type II endoleak. **D.** CTA shows an endoleak anterior to the stent-graft.

DISCUSSION

Endoleak is a significant predictive factor for outcome of thoracic aortic aneurysms treated by TEVAR (5). The incidence of endoleak after TEVAR ranges from 5% to 20%, which is similar to that after endovascular abdominal aortic aneurysm repair (EVAR) (1). Type II endoleaks are most commonly seen after EVAR. Type I and II endoleaks occur at similar rates after TEVAR (6). An accepted management method is aggressive endovascular repair of type I and III endoleaks along with observation for type II endoleaks (7). Collateral circulation in the chest involving the thoracic aorta is not so well developed compared to collateral vessels in the abdomen, making transarterial embolization of thoracic endoleaks quite difficult (6). To our knowledge, there is no consensus treatment option for type II endoleaks. There have been some reports on embolization of intercostal artery caused type II endoleaks by percutaneous sac puncture through lung parenchyma. However, a direct thoracic approach may involve transgression of the pleura and lung, which has a high risk of complications (6). In our case, embolization with a

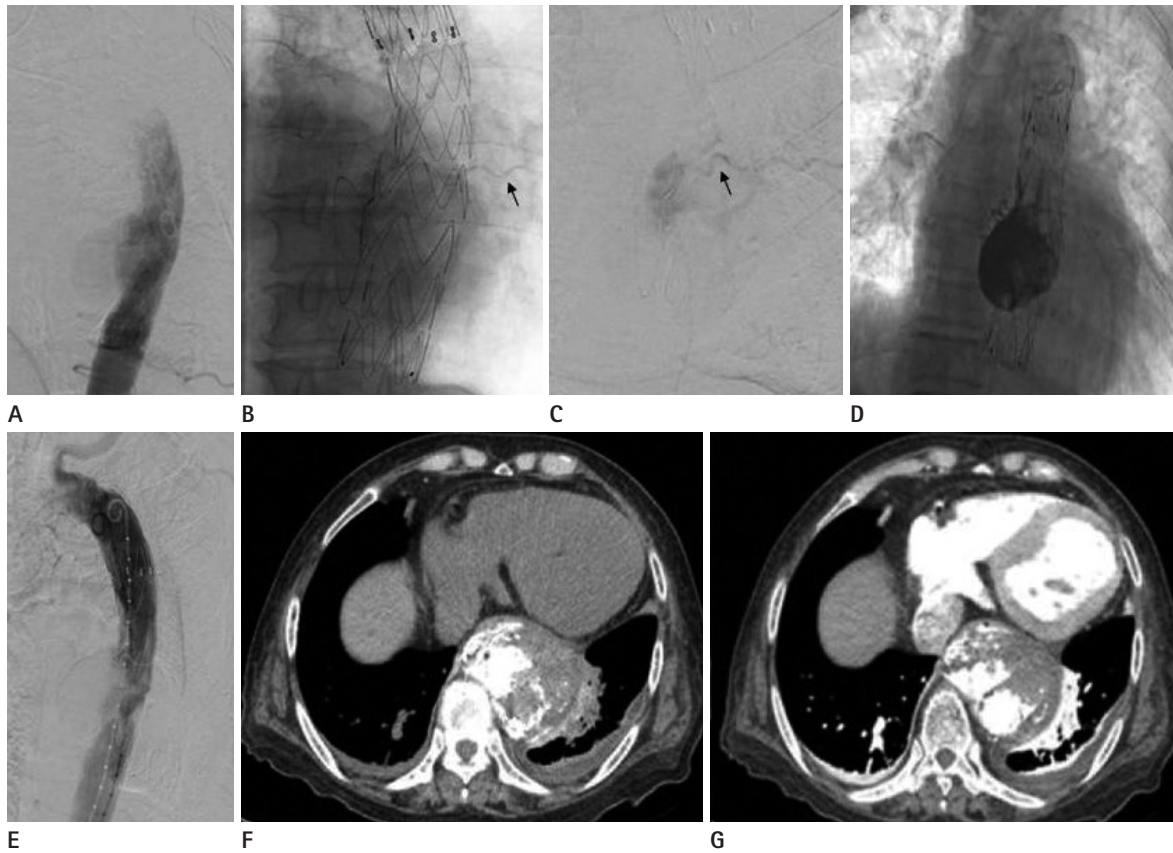


Fig. 2. Type II endoleak after thoracic endovascular aortic repair treated by histoacryl embolization.

A. Thoracic angiogram shows a type II endoleak due to retrograde filling of the aneurysmal sac with blood flow from the left seventh intercostal artery.

B, C. Cavitogram shows opacification of an aneurysmal sac and an efferent intercostal artery (black arrows).

D. The aneurysmal sac and intercostal arteries was embolized with a mixture of histoacryl (3 mL) and lipiodol (9 mL).

E. Postembolization angiogram shows a complete resolution of the endoleak.

F, G. An unchanged saccular aneurysm and a complete resolution of the endoleak are seen on noncontrast (**F**) and contrast-enhanced (**G**) CT scans.

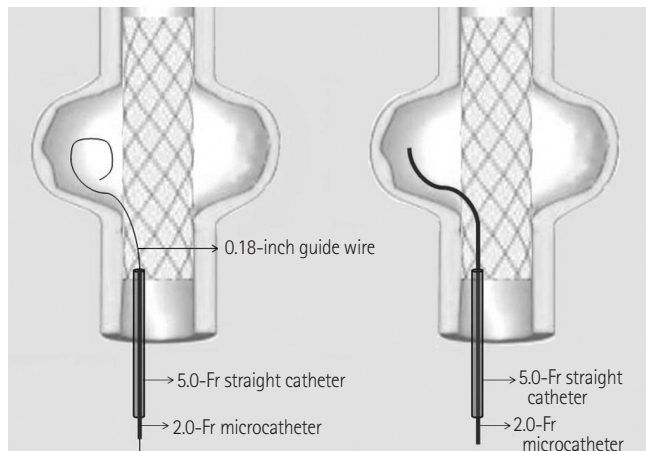


Fig. 3. The diagram shows a 2.0-Fr microcatheter (Progreat; Terumo, Tokyo, Japan) with a 0.18-inch guide wire (Transend; Boston Scientific, Boston, MA, USA), advanced into the aneurysmal sac between the distal end of the stent-graft and the aortic wall by squeezing the very narrow space.

mixture of histoacryl (3 mL) and lipiodol (9 mL) was successfully performed with a transarterial approach in type II endoleak caused by reverse blood flow from the left intercostal artery. We placed a microcatheter in the aneurysmal sac between the distal end of the stent-graft and the aortic wall. This procedure may be difficult and unfeasible for some patients with anatomic limitations. Although there have been a few reports on transarterial embolization with liquid embolic agents for type II endoleaks after EVAR (8), there is no reported case like ours in the literature. The risk of spinal infarction and neurologic deficits may contribute to this trend. Despite these drawbacks, we used liquid embolic materials to fill the aneurysmal sac and achieved successful embolization. Follow-up CT angiography confirmed the resolution of the type II endoleak caused by reverse blood flow from the left intercostal artery. This transarterial approach

may be challenging but highly effective because the durability of endoleak embolization using the approach can be increased by selecting an actual endoleak with a microcatheter.

In conclusion, this is a report on successful transarterial embolization with hystoacryl in type II endoleak caused by reverse blood flow from the intercostal artery after TEVAR. Since there is no definite guideline for treating type II endoleaks after TEVAR, close and regular follow-up is needed for optimal treatment and good clinical outcome.

REFERENCES

1. Parmer SS, Carpenter JP, Stavropoulos SW, Fairman RM, Pochettino A, Woo EY, et al. Endoleaks after endovascular repair of thoracic aortic aneurysms. *J Vasc Surg* 2006;44:447-452
2. Tanasontornrerk A, Wasinrat J, Siriapisith T, Slisatkorn W. CT angiography evaluation of endoleak after thoracic endovascular aortic repair in thoracic aortic aneurysm. *J Med Assoc Thai* 2010;93:1050-1057
3. Sucandy I, Kim H, Sullivan TR. Endovascular management of the patent inferior mesenteric artery in two cases of uncontrolled type II endoleak after endovascular aneurysm repair. *N Am J Med Sci* 2011;3:387-390
4. Morales JP, Greenberg RK, Lu Q, Cury M, Hernandez AV, Mohabbat W, et al. Endoleaks following endovascular repair of thoracic aortic aneurysm: etiology and outcomes. *J Endovasc Ther* 2008;15:631-638
5. Shah A, Stavropoulos SW. Treatment strategies for Type 2 endoleaks after endovascular aneurysm repair. *Acta Chir Belg* 2007;107:356-360
6. Stavropoulos SW, Tucker J, Carpenter JP. Thoracic endoleak embolization using a direct percutaneous puncture of the endoleak through lung parenchyma. *J Vasc Interv Radiol* 2009;20:1248-1251
7. Alsac JM, Khantalin I, Julia P, Achouh P, Farahmand P, Capdevila C, et al. The significance of endoleaks in thoracic endovascular aneurysm repair. *Ann Vasc Surg* 2011;25:345-351
8. Wilmot A, Stavropoulos SW. Embolization of a Recurrent Type 2 Endoleak Using the Liquid Embolic n-Butyl Cyanoacrylate. *Semin Intervent Radiol* 2007;24:38-42

흉부 대동맥류의 혈관 내 동맥류 재건술(Thoracic Endovascular Aortic Repair) 후 발생한 Type II Endoleak에 대한 혈관 내 치료: Squeeze Technique을 이용한 동맥류 접근방법¹

강현정¹ · 김창원¹ · 이태홍¹ · 송승환² · 이충원² · 정성운²

흉부 대동맥류의 혈관 내 동맥류재건술(thoracic endovascular aortic repair; 이하 TEVAR) 후 type II endoleak은 드물지 않은 합병증의 하나이다. 동맥통과 접근법 혹은 직접 sac을 천자하여 coils, plug 혹은 액상의 색전물질(histoacryl, thrombin, onyx) 등을 주입하는 다양한 방법이 type II endoleak의 치료에 이용되어 왔다. 본 저자 등은 histoacryl-lipiodol 혼합물을 이용해 TEVAR 이후 늑간동맥에 의해 발생한 type II endoleak에 대하여 squeeze technique이라 명명한 이식편과 동맥벽 사이의 접근을 통해 색전에 성공한 경우를 경험하였기에 문헌고찰과 함께 보고하는 바이다.

부산대학교 의과대학 부산대학교병원 ¹영상의학과학교실, ²흉부외과학교실