

Left Circumflex Coronary Artery Fistula Connected to the Right Bronchial Artery Associated with Bronchiectasis: Multidetector CT and Coronary Angiography Findings

기관지확장증에 동반된 좌선회지 관상동맥과 기관지동맥 사이의 혈관루:
Multidetector CT 및 관상동맥 조영술 소견

Kyung Jin Nam, MD, Ki Seok Choo, MD

Department of Radiology, Medical Research Institute, Pusan National University Yangsan Hospital, Pusan National University School of Medicine, Yangsan, Korea

Coronary to bronchial artery fistula is a rare vascular anomaly secondary to enlargement of pre-existing vascular anastomosis between the coronary and bronchial arteries. This occurs when there is a constant disturbance of the pressure equilibrium involving either coronary or broncho-pulmonary disorder. Localized bronchiectasis is the most common related condition in patients with a coronary to bronchial artery fistula. Herein, we report on a case of a large left circumflex coronary artery to right bronchial artery fistula associated with bronchiectasis.

Index terms

Multidetector CT
Fistula
Coronary Artery

Received January 10, 2013; Accepted February 15, 2013

Corresponding author: Ki Seok Choo, MD

Department of Radiology, Medical Research Institute, Pusan National University Yangsan Hospital, Pusan National University School of Medicine, 20 Geumo-ro, Mulgeum-eup, Yangsan 626-770, Korea.
Tel. 82-55-360-1840 Fax. 82-55-360-1848
E-mail: kschoo0618@naver.com

This is an Open Access article distributed under the terms of the Creative Commons Attribution Non-Commercial License (<http://creativecommons.org/licenses/by-nc/3.0>) which permits unrestricted non-commercial use, distribution, and reproduction in any medium, provided the original work is properly cited.

INTRODUCTION

Coronary artery fistulas are rare, congenital diseases, which have anomalous terminations of the coronary arteries (1). Coronary artery fistulas are usually asymptomatic. However, if the patient has a coronary steal phenomenon, it can cause dyspnea and chest pain. Coronary artery fistula with coronary steal phenomenon is currently treated with endovascular embolization or surgical ligation (2). Particularly in the case of a coronary artery to bronchial artery fistula, development of hemoptysis can occur and urgent treatment would be needed (3). Multidetector computed tomography (MDCT) technology had facilitated the diagnosis of coronary artery fistula to the bronchial artery, as well as bronchiectasis which is the cause of coronary artery fistula (4). Our case involved a large and tortuously coursed fistula, between the left circumflex artery and the right bronchial artery

that could be visualized on both MDCT and coronary angiography (CAG). In addition, extensive bronchiectasis, which was ascribed to the cause of the fistula, was observed on MDCT.

CASE REPORT

A 63-year-old female visited our hospital for the evaluation of atypical chest pain and intermittent cough that had been ongoing for 3 months. The patient had no history of cardiac disease, such as myocardial infarction. Our Institutional Review Board granted an exemption for us to report this case.

MDCT examinations were performed from lung apex to base, including the heart, on a dual-source 128-slice CT (Definition Flash, Siemens Medical Solution, Forchheim, Germany) with a rotation time of 280 msec, slice collimation of $2 \times 128 \times 0.6$ mm, using a continuous helical scan with the electrocardiography

(ECG)-dependent maximum tube current modulation technique. The CT scan was triggered automatically by the arrival of the main contrast bolus (automatic bolus tracking). A region of interest was placed at the ascending aorta, and image acquisition began 5 s after the signal density level reached the predefined threshold of 100 Hounsfield units. For CT examinations, a dual-head power injector (Stellant D; Medrad, Indianola, PA, USA) was used for administration of a dual-phase bolus at a rate of 5 mL per second. First, 70 mL of iopromide (Ultravist 370, Bayer Healthcare, Berlin, Germany) was administered. Thereafter, 20 mL of an 80%-to-20% mix of contrast material and saline was administered. Retrospective ECG-gating was used in combination with prospective ECG pulsing with maximum tube current output during 60-80% of the R-R interval. Outside this window, 4% of the reference tube current was used. A tube voltage (kVp) of 120 kVp was selected based on patient's body habitus. MDCT showed that the tortuous vessel ran through the mediastinum, toward the heart, and the volume-rendered image showed an abnormal, tortuous vascular structure originating from the proximal left circumflex artery (Fig. 1A). CAG was performed using standard techniques and at least 2 views in different planes were obtained for each coronary artery. CAG showed that the fistula originated from the left proximal circumflex artery. The fistula went upward, running toward the inferior, and tapered to supply the right lung (Fig. 1B). For further evaluation of the distal anastomotic site and other pulmonary parenchymal abnormality, MDCT was reconstructed with a wide field of view, including both lung fields. MDCT clearly showed the entire course of the

fistula as revealed in the coronary angiography, and the anastomotic site between the fistula and the right bronchial artery was identified (Fig. 1C). Therefore, the fistulous connection originated from the left proximal circumflex artery, passed through the pericardium, and communicated with the right bronchial artery. MDCT showed extensive bronchiectasis in the right middle lobe and both lower lobes (Fig. 1D), which included the corresponding area supplied by the coronary bronchial artery fistula. The patient remained asymptomatic throughout subsequent follow-up visits.

DISCUSSION

Coronary artery fistula is defined as an abnormal vascular communication between any coronary artery and any cardiac chamber or great vessel (1). Most patients with coronary artery fistulas are asymptomatic. However, development of cardiovascular symptoms, such as continuous machinery murmur, angina due to the coronary steal phenomenon, congestive heart failure, and ruptured aneurysmal fistula, may occur and because of massive hemoptysis, coronary artery to bronchial artery fistula caused by bronchiectasis could be a fatal condition (3, 4). Recently, according to the development of MDCT technology, coronary artery to bronchial artery fistula was found incidentally on cardiac CT (5). Anastomoses located between coronary arteries and bronchial vascular beds are usually small, with minimal or no hemodynamic significance, and are presumably congenital. The coronary to bronchial artery fistula will transform

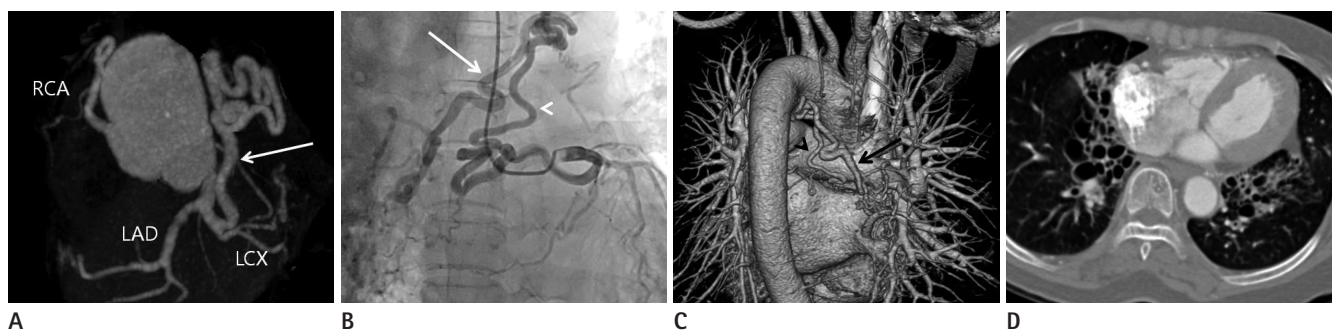


Fig. 1. A 65-year-female visited due to atypical chest pain and coughing for three months.

A. Vessel view shows an abnormally enlarged and tortuous vessel (arrow) arising from the left circumflex artery.

B. Coronary angiography shows that the fistula (arrowhead) originated from the left proximal circumflex artery, going upward and the hypertrophied bronchial artery (arrow), running toward the inferior to supply the right lung.

C. Volume-rendered image (posterior view) shows a hypertrophied bronchial artery (arrow) caused by the fistula (arrowhead) supplying the right lung.

D. Extensive bronchiectasis is seen in both middle lobes on MDCT.

Note.—LAD = left coronary anterior descending artery, LCX = left circumflex artery, MDCT = multidetector CT, RCA = right coronary artery

into the large functional vessels when a pressure gradient exists between the coronary artery and bronchial arterial circulation (6, 7). The flow direction of the fistula is determined by the relative pressure gradient between the coronary artery and the bronchial vascular beds. The steal phenomenon of the myocardium occurs either under increased coronary artery pressure, as in patients with supraaortic stenosis, or under decreased bronchial artery pressure, as in patients with pulmonary atresia, Takayasu's arteritis, or chronic pulmonary inflammatory disease (8, 9). In bronchiectasis, persistent bronchial wall infections and inflammation cause abnormal dilatation of the bronchial vessel, resulting in retrograde filling of the pulmonary artery via the precapillary bronchial-pulmonary artery anastomoses. Although cardiac catheterization has been the best diagnostic method for identification of such communications, it is an invasive procedure with risk of 1.5% morbidity and 0.15% mortality (10). Although MDCT is inferior in temporal resolution to conventional coronary angiography, its 3-dimensional images permit visualization of a complex lesion and its adjacent structures. The use of MDCT as an alternative for evaluation of coronary artery anatomy has become increasingly frequent: an increasing number of articles have been reported for identification of anatomic anomalies of the coronary arteries, such as aberrant arterial origins and coronary fistulas (4, 5). In our case report, there were 2 unique aspects. First, the fistula originated from the left circumflex artery to the right bronchial artery, resulting in a long and tortuous course. Second, despite a hypertrophied right bronchial artery, development of hemoptysis did not occur. In conclusion, bronchiectasis is a cause of coronary artery to bronchial artery fistula and ECG-gated MDCT can provide anatomical information regarding coronary artery to bronchial artery, as well as bronchiectasis.

REFERENCES

1. Papadopoulos DP, Perakis A, Votreas V, Anagnostopoulou S. Bilateral fistulas: a rare cause of chest pain. Case report with literature review. *Hellenic J Cardiol* 2008;49:111-113
2. Cho J, Shin T, Jun K, Ryoo J, Choi H, Choi B, et al. Transcatheter embolization of bronchial artery arising from left circumflex coronary artery in a patient with massive hemoptysis. *Cardiovasc Intervent Radiol* 2010;33:169-172
3. Lee WS, Lee SA, Chee HK, Hwang JJ, Park JB, Lee JH. Coronary-bronchial artery fistula manifested by hemoptysis and myocardial ischemia in a patient with bronchiectasis. *Korean J Thorac Cardiovasc Surg* 2012;45:49-52
4. Bas S, Yiginer O, Atalay M, Uz O, Feray H. Coronary-to-bronchial artery fistula with conventional and multi-detector computed tomography angiographic images. *Hellenic J Cardiol* 2010;51:164-165
5. Lee ST, Kim SY, Hur G, Hwang YJ, Kim YH, Seo JW, et al. Coronary-to-bronchial artery fistula: demonstration by 64-multidetector computed tomography with retrospective electrocardiogram-gated reconstructions. *J Comput Assist Tomogr* 2008;32:444-447
6. Smith SC, Adams DF, Herman MV, Paulin S. Coronary-to-bronchial anastomoses: an in vivo demonstration by selective coronary arteriography. *Radiology* 1972;104:289-290
7. Levin DC, Fellows KE, Abrams HL. Hemodynamically significant primary anomalies of the coronary arteries. Angiographic aspects. *Circulation* 1978;58:25-34
8. Björk L. Anastomoses between the coronary and bronchial arteries. *Acta Radiol Diagn (Stockh)* 1966;4:93-96
9. Chan MS, Chan IY, Fung KH, Lee G, Tsui KL, Leung TC. Demonstration of complex coronary-pulmonary artery fistula by MDCT and correlation with coronary angiography. *AJR Am J Roentgenol* 2005;184(3 Suppl):S28-S32
10. Schmitt R, Froehner S, Brunn J, Wagner M, Brunner H, Cherevaty O, et al. Congenital anomalies of the coronary arteries: imaging with contrast-enhanced, multidetector computed tomography. *Eur Radiol* 2005;15:1110-1121

1. Papadopoulos DP, Perakis A, Votreas V, Anagnostopoulou

기관지확장증에 동반된 좌선회지 관상동맥과 기관지동맥 사이의 혈관루: Multidetector CT 및 관상동맥 조영술 소견

남경진 · 추기석

관상동맥과 기관지동맥 간의 혈관루는 흔하지 않은 선천성 기형으로 잠재적으로 개통되어 있던 두 혈관 사이의 연결이 관상동맥의 이상 또는 기관지 폐 이상 등에 의해 비정상적으로 커지는 것이다. 국소적 기관지 확장증이 가장 흔한 원인 중에 하나이다. 우리는 기관지확장증에 의해 유발된 것으로 보이는 좌선회지 관상동맥과 오른쪽 기관지동맥 사이의 크고 긴 혈관루의 CT와 혈관촬영술소견을 보고한다.

부산대학교 의과대학 양산부산대학교병원 영상의학과