

Usefulness of Reformatted CT Rib Series in Patients with Thoracic Trauma¹흉부 외상 환자에 있어서 Reformatted CT Rib Series의 유용성 평가¹Sung-Nam Moon, MD¹, Seong Hoon Park, MD¹, Dong-Ho Bang, MD², Na-Hyung Kim, PhD¹,
Seon-Kwan Juhng, MD¹, Kwon-Ha Yoon, MD¹¹Department of Radiology and Institute for Radiological Imaging Science, Wonkwang University School of Medicine, Iksan, Korea²Department of Radiology, Aerospace Medical Center, Cheongwon, Korea**Purpose:** To assess the value of adding a reformatted computed tomography (CT) rib series to transversely reconstructed CT imaging in the evaluation of rib fractures in patients with suspected traumatic thoracic injuries.**Materials and Methods:** One hundred consecutive patients with suspected traumatic thoracic injuries underwent 128-section multi-detector row CT. Transverse CT images with 5-mm-thick sections were reconstructed and rib series were reformatted using isotropic voxel data. Three independent radiologists, who were blinded to the data, interpreted the CT scans at 2 sessions with a 4-week interval between the sessions. Only transverse CT images were reviewed at the first session. At the second session, the CT images were reviewed along with the reformatted CT rib series. The following parameters were analyzed: receiver operating characteristic (ROC) curve, pairwise comparisons of ROC curves, sensitivity, specificity, positive predictive value, and negative predictive value.**Results:** There were 153 rib fractures in 29 patients. The level of the area under the ROC curve, A_z improved for all observers. The diagnostic sensitivity and specificity of each observer tended to improve in the second session. The mean confidence scores for all observers of patients with rib fractures improved significantly in the second session.**Conclusion:** A reformatted CT rib series together with transverse CT scan is useful for the evaluation of rib fracture.**Index terms**Reformatted CT Rib Series
Virtual CT Rib Series
Rib Fracture
Chest CT
Traumatic Thoracic Injuries

Received September 28, 2012; Accepted October 20, 2012

Corresponding author: Seong Hoon Park, MD
Department of Radiology and Institute for Radiological
Imaging Science, Wonkwang University School of
Medicine, 895 Muwang-ro, Iksan 570-711, Korea.
Tel. 82-63-859-1920 Fax. 82-63-851-4749
E-mail: shpark99@wonkwang.ac.kr

This paper was supported by Wonkwang University in 2010.

Copyrights © 2013 The Korean Society of Radiology

INTRODUCTION

Blunt thoracic trauma is a common reason for emergency room visits. Although the use of initial routine chest computed tomography (CT) is controversial, it is increasingly used for patients with traumatic injury, and has a higher diagnostic performance than that of plain radiographs (1-5).

Chest CT is useful for the evaluation of rib fractures. However, rib fractures can be missed by chest CT when there is no related change due to rib fracture and the fracture line is parallel to the CT section plane. The evaluation of ribs is particularly difficult due to their peripheral location. It is problematic for

many radiologists when describing the fracture site in patients with rib fracture. Some clinicians use additional plain chest radiographs to overcome the limitations of CT in symptomatic patients; however, the patients are exposed to additional radiation during this process (6, 7). Three-dimensional reformation of the chest CT is helpful, but it takes more time for the radiologist to read the CT images (6, 8).

Recently, reformatting techniques have been used in many fields of radiology. These reformatting techniques make interpreting CT images more convenient and improve diagnostic performance because they provide additional information about the lesion (6, 9, 10). The reformatted images reflect the data with iso-

tropic voxel and do not require additional radiation.

The purpose of our study was to assess the value of adding a reformatted CT rib series to transversely reconstructed CT images for the evaluation of rib fractures in patients with suspected traumatic thoracic injuries.

MATERIALS AND METHODS

Patient Population

From November 2009 to January 2010, a total of 100 consecutive patients with suspected traumatic thoracic injuries underwent chest CT. The patients included 66 men and 34 women, and the mean age was 54.7 years (age range from 15 to 93 years). Our retrospective evaluation of patient image data was approved by the local ethics committee.

CT Scanning

CT was performed using a 128-section multi-detector row CT scanner (Somatom Definition Flash; Siemens Medical Solutions, Forchheim, Germany). Patients were placed in the supine position on the table. A non-enhanced scan of the chest was acquired from the jugular fossa to the middle of the abdomen during an inspiratory breath hold. The detector configuration was 128×0.6 mm and the tube potential was 120 kVp. Automatic current modulation was used with CARE dose 4D (Siemens Medical Solutions, Erlangen, Germany). The gantry rotation speed was 0.5 s per rotation and the pitch was 1.1.

After performing the non-enhanced scan, an enhanced scan of the same region of the chest was acquired 80 seconds after an intravenous injection of nonionic contrast agent (1.8 mL/kg body weight, Pamiray 370; Iopamidol; Dongkook Pharm., Seoul, Korea). The non-enhanced and enhanced CT images were transversely reconstructed at 5-mm intervals and with 5-mm-thick slices. In addition, non-enhanced CT images with 0.6-mm-thick slices were reconstructed at 0.6-mm slice intervals, and were used to reformat the CT rib series.

Reformatting Technique

The reconstructed CT images were transferred to a three-dimensional (3D) workstation (Aquarius iNtuition; TeraRecon, Inc., San Mateo, CA, USA). Volume-rendered images were reformatted and reformatted data was affected by the gradient ef-

fect. Linear ramp-up with a window width of 400 Hounsfield units, a window center of 350 Hounsfield units, and 0.08 opacity were used for the gradient effect. According to this graph, the reformatted volume-rendered color image was converted to a black-and-white image with a gray-scaled gradient, similar to a plain radiograph (Fig. 1). The anteroposterior, sternal lateral, and oblique views were then captured. The images obtained by reformatting were similar to a rib series. These reformatted images were termed the "reformatted CT rib series." All of these processes were performed by one observer (S. N. M.) who was blinded to the purpose of this study.

Imaging Analysis

Three independent observers (S. K. J., with 23 years of experience in radiology; S. H. P., with 12 years of experience in radiology; and D. H. B., with 4 years of experience in radiology) retrospectively reviewed the images and were blinded to patient information and any other imaging results. The only patient information was provided from the patient's hospital number. Image reading occurred in 2 sessions. To reduce recall bias, the sessions were separated by a 4-week interval. During the first session, the 3 observers interpreted only the transverse CT images in separate rooms. During the second session, the observers interpreted each transverse image along with the reformatted CT rib series in separate rooms. For the second session, the 3 observers were provided a rearranged patient list, assembled by another radiologist S. N. M., which blinded the 3 observers to reduce recall bias. The recorded findings were classified by each patient and summarized. Together, the 3 observers then interpreted the 3D reformatted images generated by the 3D workstation and confirmed rib fractures by consensus.

Imaging findings included rib fracture and other injuries (hemothorax, pneumothorax, hydrothorax, parenchymal injury, chest wall swelling, intramuscular hematoma, aortic injury, mediastinal hematoma, airway injury, and abdominal visceral organ injury). A confidence score was obtained for each rib fracture, on a scale of 1-5 (1, definitely absent; 2, probably absent; 3, cannot determine; 4, probably present; and 5, definitely present).

Statistical Analysis

Receiver operating characteristic (ROC) curve analysis was used to estimate the diagnostic performance of each observer

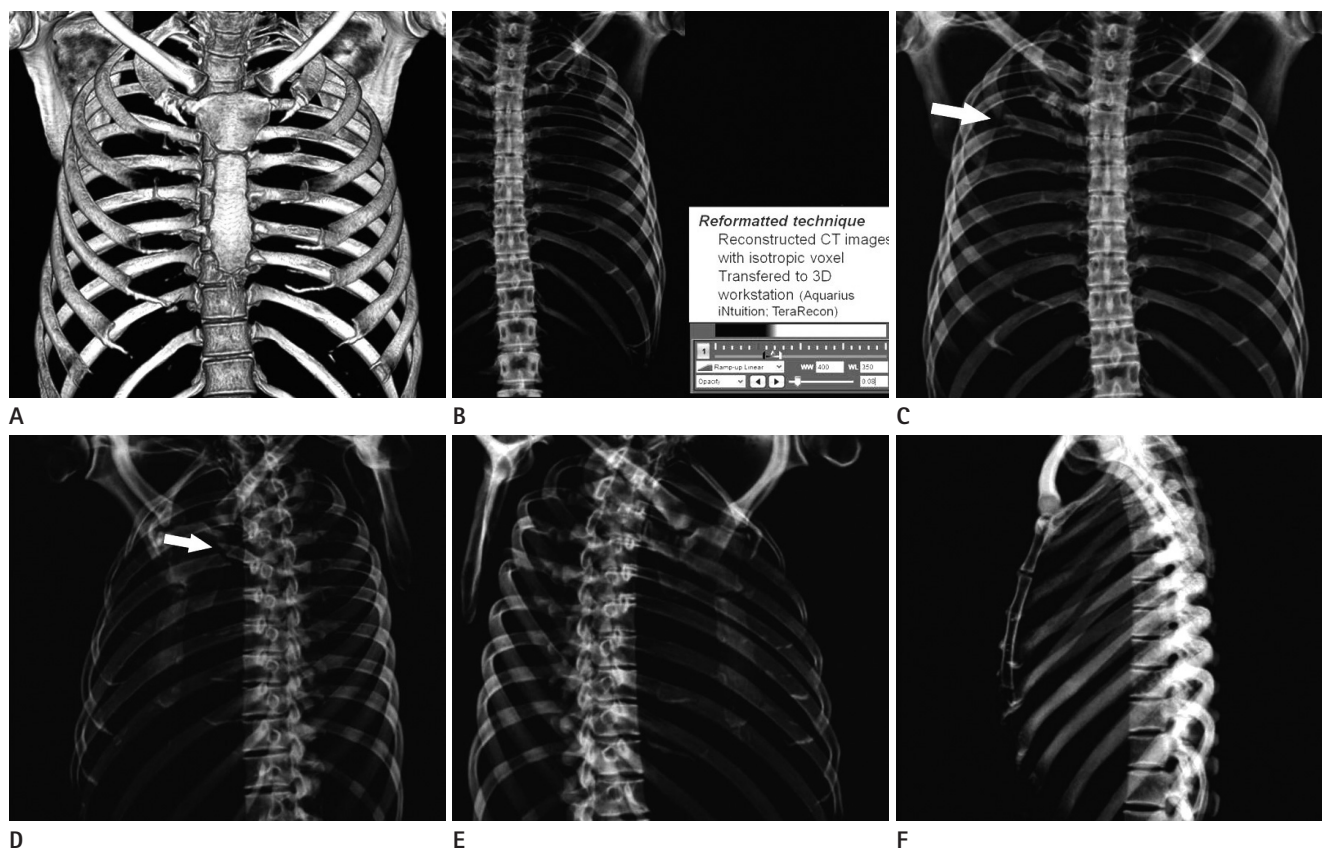


Fig. 1. A reformatted virtual rib series using a three-dimensional workstation. The volume-rendered image was reformatted (A). The reformatted volume-rendered image was influenced by the gradient effect (B). For this gradient effect, a linear ramp-up with a window width of 400 Hounsfield units, a window center of 350 Hounsfield units, and 0.08 opacity was applied. The reformatted rib series resembled a true rib series (C-F). An anteroposterior view (C), right oblique view (D), left oblique view (E), and lateral sternal view (F) were obtained. In this patient, right 5th rib fractures were detected in the reformatted rib series only. Arrows indicate rib fracture (C, D).

and the area under the ROC curve (A_z) was calculated. To compare the diagnostic performance between the 2 sessions, pairwise comparisons of the ROC curves were performed and 95% confidence intervals were used to express the statistical precision of the results.

Based on the assumption that a confidence level of 4 or greater was positive for the diagnosis of rib fracture, diagnostic sensitivity, specificity, positive predictive value, and negative predictive value were calculated for the 3 observers and the McNemar test was used to compare sensitivity and specificity between the 2 sessions.

At each session, interobserver agreement was determined using the weighted κ statistic. A κ value of less than 0.20 indicated poor agreement, 0.21-0.40 indicated fair agreement, 0.41-0.60 indicated moderate agreement, 0.61-0.80 indicated good agreement, and greater than 0.81 indicated an excellent agreement.

Differences in the mean confidence ratings of each observer

for patients with or without rib fractures were determined by the Wilcoxon signed rank test. p -values less than 0.05 were considered to indicate statistically significant differences. Statistics were calculated using SPSS 18.0 statistical software for Windows (SPSS Inc., Chicago, IL, USA).

RESULTS

We found 153 rib fractures in 29 out of 100 patients with suspected thoracic trauma. The area under the ROC curve improved for each observer when comparing the first and second session. Observer 1 improved from 0.918 to 0.960 ($p < 0.001$), observer 2 from 0.823 to 0.937 ($p < 0.001$), and observer 3 from 0.725 to 0.834 ($p < 0.001$) (Table 1). The diagnostic sensitivity of the 3 reviewers significantly improved in the second session ($p < 0.001$). The diagnostic specificity of observers 2 and 3 significantly improved in the second session ($p = 0.012$ for observer

Table 1. Comparison of the Diagnostic Capability of Transverse CT Alone to Transverse CT with a Reformatted CT Rib Series for the Evaluation of Rib Fractures

Type of Imaging and Observer	Az Value*	Sensitivity (%)	Specificity (%)	PPV (%)	NPV (%)
Transverse CT images					
Observer 1	0.918 (0.883, 0.952)	58.8 (90/153)	99.9 (2246/2247)	98.9 (90/91)	97.3 (2246/2309)
Observer 2	0.823 (0.776, 0.870)	83.0 (127/153)	99.7 (2241/2247)	95.5 (127/133)	98.9 (2241/2267)
Observer 3	0.725 (0.673, 0.777)	44.4 (68/153)	99.9 (2244/2247)	95.8 (127/133)	96.4 (2244/2329)
Transverse CT images with VRS					
Observer 1	0.960 (0.935, 0.984)	85.0 (130/153)	99.7 (2240/2247)	94.9 (130/137)	99.0 (2240/2263)
Observer 2	0.937 (0.906, 0.968)	91.5 (140/153)	99.7 (2240/2247)	95.2 (140/147)	99.4 (2240/2253)
Observer 3	0.834 (0.789, 0.880)	63.4 (97/153)	99.6 (2238/2247)	91.5 (97/106)	97.6 (2238/2294)
<i>p</i> -value [†]					
Observer 1	< 0.001	< 0.001	> 0.99	-	-
Observer 2	< 0.001	< 0.001	0.012	-	-
Observer 3	< 0.001	< 0.001	0.013	-	-

Unless otherwise indicated, numbers shown in parentheses are raw data. Sensitivity, specificity, PPV, and NPV were calculated according to the assumption that a confidence score of 4 or higher was a positive diagnosis of rib fracture.

Note. —*Data shown in parentheses are 95% confidence intervals.

[†]*p*-values for Az values are from pairwise comparisons of ROC curves. *p*-values for sensitivity and specificity were calculated using the McNemar test.

NPV = negative predictive value, PPV = positive predictive value, ROC = receiver operating characteristic, VRS = volume-reformatted CT rib series

Table 2. Interobserver Agreement for Rib Fracture Diagnoses

Observer Combination	Transverse Alone	Combined Reformatted CT Rib Series and Transverse Scan
Observer 1 and 2	0.705	0.817
Observer 2 and 3	0.530	0.615
Observer 1 and 3	0.580	0.611

Table 3. Mean Confidence Score of Each Reviewer for Patients with Rib Fractures

	Transverse Alone	Combined Reformatted CT Rib Series and Transverse Scan	<i>p</i> -Value
Observer 1	2.70 (1.36)	3.48 (1.03)	< 0.001
Observer 2	3.42 (1.12)	3.70 (0.84)	< 0.001
Observer 3	2.27 (1.44)	2.78 (2.34)	< 0.001

Table 4. Mean Confidence Scores of Each Reviewer for Patients without Rib Fractures

	Transverse Alone	Combined Reformatted CT Rib Series and Transverse Scan	<i>p</i> -Value
Observer 1	1.00 (0.05)	1.01 (0.14)	0.005
Observer 2	1.01 (0.12)	1.01 (0.15)	0.427
Observer 3	1.00 (0.07)	1.01 (0.17)	0.012

2; *p* = 0.013 for observer 3) (Table 1). Interobserver agreement also improved in the second session (Table 2). The mean confidence scores of all observers for patients with rib fractures improved significantly in the second session (Table 3). The mean confidence scores of 2 observers (observer 1 and 3) for patients

without rib fractures significantly improved in the second session, but that of the other observer (observer 2) did not improve significantly (Table 4).

DISCUSSION

In general, a rib fracture is considered a minor problem that only requires conservative therapy. However, rib fractures can cause serious conditions (11-13). It is difficult to detect rib fractures using transverse CT imaging alone, particularly if the related change is not combined and the fracture line is parallel to the slice plane.

To overcome this limitation of transverse CT images, slice thickness and intervals thinner than 5 mm, or 3D evaluation of chest CT data can be used. In the reformatted CT images, coronal, and sagittal image resolution is similar that of the transverse images. However, it takes a great deal of time for a radiologist to read. In contrast, a plain radiographic rib series can also be used. However, more radiation is required to obtain the images. Therefore, we found another method to detect rib fractures without the additional radiation dosage.

When we added a reformatted CT rib series to the transverse CT images, the following scores increased: sensitivity, interobserver agreement, and mean confidence. This suggests that the reformatted CT rib series allows for easier detection of rib frac-

tures. In addition, for radiologists with less experience, their diagnostic performance can be improved using the reformatted CT rib series, compared to transverse CT images alone. In addition, although we did not measure reading time, interpretation using the reformatted CT rib series supports easier identification of the fractured rib site than using the transverse CT image alone.

The reformatted CT rib series was called a reformatted CT rib series; however, it is not same as a conventional rib series. Both images are 2 dimensional. The reformatted CT rib series was reformatted chest CT images, and their attenuation does not differ according to the distance from the tube. However, a conventional rib series is obtained by projection of an X-ray with one direction, and their attenuation differs according to the distance from the tube. In our study, stepladder artifacts mimicking rib fractures were rare because of the fast acquisition of CT scanning. Furthermore, this artifact can be differentiated from true fractures by noting their bilaterality and the continuing line abutting the fracture line.

Our study has some limitations. First, our study group was relatively small; however, there were 2400 ribs in our 100 patients. Second, only 3 radiologists participated in our study. Two of the reviewers were professors with more than 10 years of experience in radiology, and the other reviewer was a resident with 4 years of experience in radiology. Although they had different detection abilities, these differences were not statistically significant. Third, interpretation time was not recorded in this study. Therefore, we do not know exactly how much time was saved using the reformatted CT rib series compared to the 3D assessment of thoracic fractures. However, the interpretation time might be shorter when a reformatted CT rib series was added, because only 4 images were included in the series. In addition, we did not need to count the fractured rib. Finally, 3D thoracic assessment was used as the standard method for diagnosis of a thoracic fracture. Confirmation of thoracic fracture can be helped by a follow-up chest CT or bone scan. Although these examinations were not performed, some reports have shown that the 3D evaluation can improve diagnostic performance (14).

In conclusion, when compared to the use of a transverse CT scan only, the addition of a reformatted CT rib series was useful for the evaluation of patients with suspected traumatic injuries.

REFERENCES

1. Downing SW, Sperling JS, Mirvis SE, Cardarelli MG, Gilbert TB, Scalea TM, et al. Experience with spiral computed tomography as the sole diagnostic method for traumatic aortic rupture. *Ann Thorac Surg* 2001;72:495-501; discussion 501-502
2. Exadaktylos AK, Sclabas G, Schmid SW, Schaller B, Zimmermann H. Do we really need routine computed tomographic scanning in the primary evaluation of blunt chest trauma in patients with "normal" chest radiograph? *J Trauma* 2001;51:1173-1176
3. Guerrero-López F, Vázquez-Mata G, Alcázar-Romero PP, Fernández-Mondéjar E, Aguayo-Hoyos E, Linde-Valverde CM. Evaluation of the utility of computed tomography in the initial assessment of the critical care patient with chest trauma. *Crit Care Med* 2000;28:1370-1375
4. Omert L, Yeane WW, Protetch J. Efficacy of thoracic computerized tomography in blunt chest trauma. *Am Surg* 2001;67:660-664
5. Smejkal R, O'Malley KF, David E, Cernaianu AC, Ross SE. Routine initial computed tomography of the chest in blunt torso trauma. *Chest* 1991;100:667-669
6. Kaewlai R, Avery LL, Asrani AV, Novelline RA. Multidetector CT of blunt thoracic trauma. *Radiographics* 2008;28:1555-1570
7. Huggett JM, Roszler MH. CT findings of sternal fracture. *Injury* 1998;29:623-626
8. Kehdy F, Richardson JD. The utility of 3-D CT scan in the diagnosis and evaluation of sternal fractures. *J Trauma* 2006;60:635-636
9. Larici AR, Gotway MB, Litt HI, Reddy GP, Webb WR, Gotway CA, et al. Helical CT with sagittal and coronal reconstructions: accuracy for detection of diaphragmatic injury. *AJR Am J Roentgenol* 2002;179:451-457
10. Sangster GP, González-Beicos A, Carbo AI, Heldmann MG, Ibrahim H, Carrascosa P, et al. Blunt traumatic injuries of the lung parenchyma, pleura, thoracic wall, and intrathoracic airways: multidetector computer tomography imaging findings. *Emerg Radiol* 2007;14:297-310
11. Wanek S, Mayberry JC. Blunt thoracic trauma: flail chest, pulmonary contusion, and blast injury. *Crit Care Clin* 2004;

- 20:71-81
12. Collins J. Chest wall trauma. *J Thorac Imaging* 2000;15: 112-119
13. Mayberry JC. Imaging in thoracic trauma: the trauma surgeon's perspective. *J Thorac Imaging* 2000;15:76-86
14. Rydberg J, Sandrasegaran K, Tarver RD, Frank MS, Conces DJ, Choplin RH. Routine isotropic computed tomography scanning of chest: value of coronal and sagittal reformations. *Invest Radiol* 2007;42:23-28

흉부 외상 환자에 있어서 Reformatted CT Rib Series의 유용성 평가¹

문성남¹ · 박성훈¹ · 방동호² · 김나형¹ · 정선관¹ · 윤권하¹

목적: 외상성 손상이 의심되는 환자들의 늑골 골절 영상 소견시, 횡으로 재건된 CT 영상과 재구성한 CT rib series를 함께 평가하는 것이 유용한지를 조사하였다.

대상과 방법: 흉부의 외상성 손상이 의심되는 100명의 환자들에 대해 128-다중채널 CT를 시행하였다. 5 mm 두께의 횡축 CT 영상을 재건하였고, 등방성 복셀 데이터를 사용하여 영상을 재구성하였다. 세 명의 독립적인 판독자들이 임상정보를 배제하고 4주 간격으로 두 차례 CT 영상을 5점 척도를 사용하여 판독하였다. 삼차원 재구성 CT를 기준으로, 1차에서는 횡축 CT 영상만을 판독하였고 2차에서는 횡축 CT 영상과 재구성한 CT rib series를 함께 판독하였다. 진단도 예측을 위한 receiver operating characteristic (ROC) 곡선분석과 두 군 간 진단도 비교를 위한 ROC 곡선의 쌍별 비교법을 시행하였고, 민감도, 특이도, 양성예측도, 음성예측도를 측정하였다.

결과: 29명에서 153개의 늑골 골절이 진단되었다. 모든 판독자에서 ROC 곡선 아래의 면적이 1차보다 2차에서 향상되었다. 진단 민감도는 1차보다 2차에서 유의하게 높았고, 진단 특이도는 두명의 판독자에서 2차에서 유의성 있게 높았다($p = 0.012$, 판독자 2; $p = 0.013$, 판독자 3). 관찰자 간 합의는 2차에서 더 높았고, 늑골 골절이 있는 환자들에 대한 평균 신뢰값은 2차 판독에서 모두 향상되었다.

결론: 횡축 CT 영상만을 이용하는 것보다 재구성 CT rib series를 추가로 참조하여 판독하는 것이 흉부 외상성 손상의 의심되는 환자 평가에 유용하다.

¹원광대학교 의과대학 영상의학과학교실 방사선영상과학연구소, ²항공우주의료원 영상의학과