

Retrieval Airway Stent Placement for Stoma Stricture after Anterior Mediastinal Tracheostomy: Case Report¹

앞가슴세로칸 기관절개술 후 발생한 스토마 협착 치료를 위한 제거 가능한 기도 스텐트 삽입: 증례 보고¹

Jae-Yeon Hwang, MD¹, Ji Hoon Shin, MD¹, Yong Hee Kim, MD², Yeoun Joo Lee, MD³,
Ho-Young Song, MD¹, Jin Hyoun Kim, MD¹

¹Department of Radiology and Research Institute of Radiology, ²Department of Thoracic and Cardiovascular Surgery, University of Ulsan College of Medicine, Asan Medical Center, Seoul, Korea

³Department of Pediatrics, Pusan National University Children's Hospital, Yangsan, Korea

Anterior mediastinal tracheostomy (AMT) is performed to establish an airway after resection of advanced tumors in the cervicothoracic region. We report a case of successful placement of a covered retrievable self-expandable nitinol stent for a stoma stricture that developed after AMT in a patient with adenoid cystic carcinoma of the trachea. Two stent placements and removals, at two and three months after their initial placement, were performed due to loosening of the stents. Although we did not achieve long-term results as the patient died of massive hemorrhage, the stent placement was both feasible and safe, thus suggesting that temporary stent placement may be a valuable option for treating stoma stricture occurring after AMT.

Index terms

Anterior Mediastinal Tracheostomy

Stoma Stricture

Stent Placement

Received February 22, 2013; Accepted February 27, 2013

Corresponding author: Ji Hoon Shin, MD

Department of Radiology and Research Institute of Radiology University of Ulsan College of Medicine, Asan Medical Center, 88 Olympic-ro 43-gil, Songpa-gu, Seoul 138-736, Korea.

Tel. 82-2-3010-4380 Fax. 82-2-476-0090

E-mail: jhshin@amc.seoul.kr

This is an Open Access article distributed under the terms of the Creative Commons Attribution Non-Commercial License (<http://creativecommons.org/licenses/by-nc/3.0>) which permits unrestricted non-commercial use, distribution, and reproduction in any medium, provided the original work is properly cited.

We thank Bonnie Hami, MA, Department of Radiology, University Hospitals of Cleveland, Ohio, for her editorial assistance in the preparation of the manuscript.

INTRODUCTION

Anterior mediastinal tracheostomy (AMT) is the construction of a tracheostomy stoma within the intrathoracic trachea. This procedure was developed to establish an airway after resection of advanced laryngotracheal carcinomas or stomal recurrences after laryngectomy for carcinoma (1).

Stricture of the tracheal stoma is uncommon, although when it occurs, it may cause severe respiratory distress (2). We describe a case of stent placement for stricture of the AMT, performed due to the extensive resection preventing anastomosis of the residual trachea.

CASE REPORT

A 32-year-old female presented with verbal disturbance and

hoarseness of one month's duration. Computed tomography (CT) scans showed a lobulated and heterogeneously enhancing soft tissue mass in the proximal trachea, which was infiltrating along the trachea wall and had invaded the esophagus. On bronchoscopic biopsy, the mass was confirmed as adenoid cystic carcinoma of the trachea. The patient underwent tracheal resection and anastomosis. The total resection length was 2 cm, and the proximal and distal resection margins were seen to be invaded by the tumor on histologic examination. Six days later, repeat surgery was performed to resect the tumor and to completely repair the anastomotic dehiscence. However, the remaining tracheal length was too short for an end-to-end anastomosis. AMT was chosen to overcome the shortness of the trachea, after which local flap surgery was performed to cover the soft tissue defect in the neck. The stoma of the AMT was constructed to be inferi-

or to the brachiocephalic artery.

Seventy days after the AMT, the patient was re-admitted due to dyspnea. On the CT scans, the AMT tract showed stricture due to granulation tissue formation (Fig. 1A, B). An adult bronchoscope (6 mm in external diameter) could be barely passed through the stricture at the entrance of the stoma of the AMT. In a multi-disciplinary conference, it was decided to perform stent placement. A 12-mm-diameter, 3-cm-long, covered retrievable self-expandable nitinol stent (S&G Biotech, Seongnam, Korea) was inserted under fluoroscopic guidance (Fig. 1C). The

most proximal portion of the stent was exposed outside the skin (Fig. 1D). On the post-procedure bronchoscopy, the proximal portion of the stent was seen to be located at the carina (Fig. 1E). Radiotherapy was started two weeks before stent placement and continued for a total of six weeks with a total dose of 6600 cGy. There was no episode of dyspnea while the stent was in place. Loosening of the stent was noted two months after placement, thus suggesting successful remodeling of the stricture. The stent was easily removed by manually grasping and pulling it; it had been in place for two months. The CT scans obtained

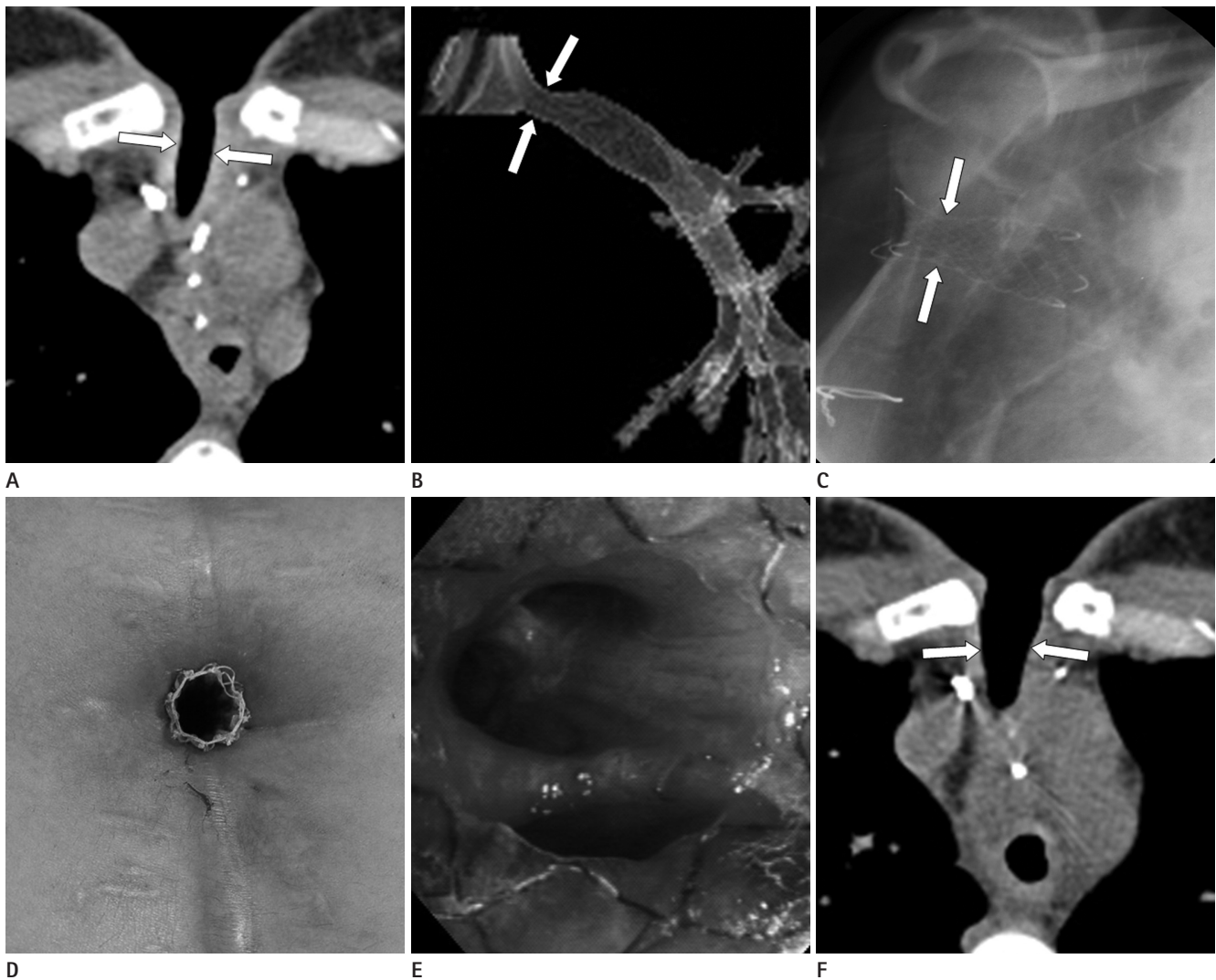


Fig. 1. Temporary stent placement for the stricture of the stoma after anterior mediastinal tracheostomy for adenoid cystic carcinoma. **A, B.** Axial and reconstructed CT images show a tight stricture (arrows) at the ostium of the anterior mediastinal tracheostomy. **C.** A 12-mm-diameter, 3 cm-long, covered retrievable self-expandable nitinol stent was placed under fluoroscopic guidance to treat the stricture. There is a waist formation (arrows) of the stent at the stricture. **D.** The proximal end of the stent was exposed outside the skin. **E.** On bronchoscopy obtained after stent placement, the distal end of the stent lies at the carina level. **F.** A CT scan obtained after two months following the temporary stent placement, shows substantial widening of the previous stricture (arrows).

immediately following stent removal showed a much-dilated state of the ostium of the AMT (Fig. 1F).

The patient re-visited the hospital with restenosis of the ostium of the AMT due to desiccated sputum and re-stricture occurred two weeks following stent removal. Under fluoroscopic guidance, we placed a 12-mm-diameter, 3-cm-long, covered retrievable self-expandable nitinol stent. Three months later, stent loosening was noted, and the stent was easily removed using the same method as in the first stent removal.

Five weeks after the second stent removal, the granulation tissue in the left main bronchus, which had been causing intermittent dyspnea, was removed using a laser excision technique. One week later, however, she died from abrupt and massive bleeding at the tracheostomy at an outside hospital. As autopsy was not performed, the exact source of hemorrhage was not verified.

DISCUSSION

Stricture in the AMT stoma may result from the surgical technique, an infection or from preoperative, or postoperative radiotherapy to the neck (2). Although there are only limited reports on stoma stricture occurring following AMT, it could occur due to similar etiologies to those of stricture in the tracheostomy stoma. Furthermore, the sternum at the entrance of the stoma of the AMT could be the narrowest part of the reconstructed airway, although in our patient, the narrowest portion was at the sternum and just distal to it. In our patient, radiotherapy seemed to contribute to the formation of granulation tissue and stricture by inducing inflammation.

AMT is a complicated procedure, and postoperative care requires concerted efforts (1, 3). Desiccated sputum is easily formed due to the shortened airway, as was the case in our study patient, and therefore requires frequent cleaning. When a stricture occurs, only non-surgical management such as dilatation, tracheostomy tube or stent placement, can solve the problem (1).

In our patient, placement and removal of a covered stent was easy and successful. A covered stent should be used if stent removal is expected, as ingrowth of hyperplastic tissue into the stent mesh will occur if uncovered stents are used. In our patient, stent placement was not difficult under fluoroscopic guidance. As the bifurcation into the right and left main bronchus was visible under fluoroscopic guidance, exact deployment of the stent

was possible. Stent removal was also easy as the proximal end of the stent was seen outside of the stoma in the current case.

The first attempt of temporary stent placement for two months failed in our patient although dyspnea was resolved while the stent was in place. We believe that in our patient, continued radiotherapy after stent placement and the tight space through the sternum made it difficult to successfully remodel the stricture. Although we did not achieve final, successful treatment due to the formation of granulation tissue and the patient's unexpected death, we believe that there is still the potential of successful, temporary stent placement to treat benign airway stricture (4).

Late brachiocephalic hemorrhage is a serious complication encountered in AMT, caused by tracheobrachiocephalic artery fistula or erosion of the brachiocephalic artery (1, 3, 5, 6). Other causes include exposure of the artery secondary to failure of healing of the skin and abetted by prior radiotherapy. Pressure erosion caused by a cannula, surrounding structure, or excessive tension at the stoma also may result in bleeding (6, 7). In our patient, late bleeding occurred about 4.5 months after the second stent placement and 6 weeks after removal of the stent. It could be related to the brachiocephalic artery, although an autopsy was not performed. Although there is no report describing brachiocephalic artery hemorrhage associated with stent placement for stomal stricture, it may be that long-standing excessive pressure due to expanded stent can cause necrosis of surrounding tissue and fistula to the brachiocephalic artery.

Decision of the optimal stent diameter as well as indwelling period is essential to prevent pressure necrosis. For this reason, we placed retrievable stent and tried to remove the stent as soon as possible when the stoma seemed remodeled sufficiently. Omental coverage of the stoma site or ligation of brachiocephalic artery can also reduce the risk of bleeding during constructing AMT (6). In our patient, stomal stricture was effectively managed with the stent for more than 6 months before the late bleeding even with an episode of re-stricture and removal of the granulation tissue. There was no bleeding while the stent was being placed. We conclude that stent placement can be a feasible conservative and ancillary solution of stricture after AMT, especially in the terminal cancer patients regarding the risk of bleeding.

In conclusion, in our patient, stent placement and removal was feasible and safe for the stoma stricture that developed following AMT. Although we did not achieve long-term results,

temporary stent placement is an option for treating stoma stricture forming after AMT.

REFERENCES

1. Maipang T, Singha S, Panjapiyakul C, Totemchokchayakarn P. Mediastinal tracheostomy. *Am J Surg* 1996;171:581-586
2. Hefer T, Joachims HZ. CO2 laser repair of permanent tracheostomy stricture. *Otolaryngol Head Neck Surg* 1997; 117(3 Pt 1):276-279
3. Gómez-Caro A, Gimferrer JM, Macchiarini P. Technique to avoid innominate artery ligation and perform an anterior mediastinal tracheostomy for residual trachea of less than 5 cm. *Ann Thorac Surg* 2007;84:1777-1779
4. Kim JH, Shin JH, Song HY, Shim TS, Yoon CJ, Ko GY. Benign tracheobronchial strictures: long-term results and factors affecting airway patency after temporary stent placement. *AJR Am J Roentgenol* 2007;188:1033-1038
5. Orringer MB. As originally published in 1992: Anterior mediastinal tracheostomy with and without cervical exenteration. Updated in 1998. *Ann Thorac Surg* 1999;67:591
6. Grillo HC. *Tracheal fistula to brachiocephalic artery*. In Grillo HC. *Surgery of the trachea and bronchi*. Hamilton, London: BC Decker Inc, 2004:357-362
7. Martinod E, Guillaume JY, Radu DM, Despreaux G. A more conservative technique for anterior mediastinal tracheostomy after sub-total resection of the trachea. *Interact Cardiovasc Thorac Surg* 2011;12:672-675

앞가슴세로칸 기관절개술 후 발생한 스토마 협착 치료를 위한 제거 가능한 기도 스텐트 삽입: 증례 보고¹

황재연¹ · 신지훈¹ · 김용희² · 이연주³ · 송호영¹ · 김진형¹

앞가슴세로칸 기관절개술(anterior mediastinal tracheostomy; AMT)은 목가슴 부위의 진행된 종양 제거 후 기도 확보를 위해 시행되는 술기이다. 저자들은 AMT 스토마(stoma)에 협착이 생긴 기관낭샘암(adenoid cystic carcinoma) 환자에서 covered retrievable self-expandable nitinol stent를 삽입하여 기도를 확보한 증례를 보고하고자 한다. 스텐트 헐거워짐(loosening)의 발생에 의해 두 번의 스텐트 삽입 및 제거가 시행되었으며, 각각의 스텐트는 2개월 및 3개월 동안 유지할 수 있었다. 비록 환자 과다 출혈로 인한 환자의 사망 때문에 장기적 결과(long-term result)는 얻을 수 없었지만, 스텐트 삽입은 실행 가능하였고 안전하였으며, 이는 임시적인 스텐트 삽입이 AMT 후에 발생한 스토마 협착에 대한 가치 있는 치료 방법이 될 수 있다고 생각하기에 이를 보고하는 바이다.

울산대학교 의과대학 서울아산병원 ¹영상의학과, ²흉부외과, ³부산대학교 어린이병원 소아청소년과