

Successful Treatment of an Iatrogenic Hepatic Arteriovenous Fistula with an Endobiliary Covered Stent Graft: A Case Report

의인성 간동맥-쓸개길 누공의 쓸개길내스텐트 설치술에 의한 성공적인 치료: 증례 보고

Hyun Song, MD, Su Lim Lee, MD, Young Mi Ku, MD, Chang Woo Chun, MD

Department of Radiology, Uijeongbu St. Mary's Hospital, College of Medicine, The Catholic University of Korea, Uijeongbu, Korea

Hepatic arteriovenous fistula is a rare cause of hemobilia following percutaneous transhepatic biliary drainage for treatment of hilar cholangiocarcinoma. Hemobilia related to arterial injury is resistant to conservative treatment. Therefore, transarterial embolization after confirmation of bleeding vessels on an angiogram is generally considered as the first line of treatment to stop arterial bleeding. However, in high risk situations such as a hepatic infarction by arterial embolization, the endobiliary approach with a covered stent can be considered as an alternative treatment method. The authors report a case of iatrogenic arteriovenous fistula in a patient with hilar cholangiocarcinoma which was successfully controlled by an endobiliary covered stent graft.

Index terms

Arteriovenous Fistula
Bile Duct
Complication
Hemobilia
Hepatic Artery
Percutaneous Drainage
Stent Graft

INTRODUCTION

Percutaneous transhepatic biliary drainage (PTBD) is an invasive procedure with the risk of complications including cholangitis, bile leak, pneumothorax and hemobilia (1). The incidence of hepatic artery injury in patients with PTBD is reported to be 1.9-2.2% (2). The two most common angiographic findings of hepatic artery injury are an arteriovenous fistula and a pseudoaneurysm (2). Traditionally, a transarterial embolization and an endovascular stent graft have been known as first line of treatment for hepatic arteriovenous fistula (3, 4). Transarterial embolization is immediately effective but may disrupt the distal circulation, probably resulting in a hepatic infarction in high

risk patients. An endovascular stent graft is a viable treatment option for cases of arteriovenous fistula. Herein, we describe the usefulness of an endobiliary covered stent graft as a simultaneous treatment for hepatic arteriovenous fistula and biliary obstruction due to hilar cholangiocarcinoma, especially in patients with a high risk of a hepatic infarction.

CASE REPORT

A 71-year-old man with a history of hilar cholangiocarcinoma was admitted to our hospital for evaluation of intermittent bleeding through an 8 Fr internal-external biliary drainage catheter and poor catheter drainage function. A contrast-enhanced com-

Received February 24, 2012; Accepted May 2, 2012

Corresponding author: Su Lim Lee, MD

Department of Radiology, Uijeongbu St. Mary's Hospital,
College of Medicine, The Catholic University of Korea,
271 Cheonbo-ro, Uijeongbu 480-717, Korea.
Tel. 82-31-820-3749 Fax. 82-31-846-3080
E-mail: radlsl@catholic.ac.kr

Copyrights © 2012 The Korean Society of Radiology

puted tomographic (CT) scan revealed a type IIIa hilar cholangiocarcinoma with right portal vein and right hepatic artery invasion (Fig. 1A). A wedge-shaped hypo-perfusion area was noted in liver segments 5 and 8, suggesting an ischemic change due to compromised dual supply (Fig. 1B). An initial cholangiogram obtained through the existing catheter showed multiple filling defects that were considered to be blood clots (Fig. 1C). Under fluoroscopic guidance, a 0.035-inch stiff guidewire (Terumo Medical Corporation, Somerset, NJ, USA) was inserted through the catheter; the existing 8 Fr internal-external biliary drainage catheter was removed, which resulted in the development of active bleeding. We attempted to upsize the drainage

catheter to tamponade the bleeding site, and install a 10 Fr internal-external biliary drainage catheter (Flexima, Boston Scientific, Natick, MA, USA). In addition, an 8 Fr internal-external biliary drainage catheter (Flexima, Boston Scientific, Natick, MA, USA) was inserted into the left dilated intrahepatic duct. On the next day, a hepatic angiography was performed during the release of the 10 Fr internal-external drainage catheter. An angiography demonstrated an arteribiliary fistula at the level of the right hepatic artery, with opacification of the right intrahepatic duct and common hepatic duct (Fig. 1D). Under fluoroscopic guidance, a 10 × 50 mm covered self-expandable-nitinol stent (Hanaro spiral stent; MI Tech, Seoul, Korea) was deployed

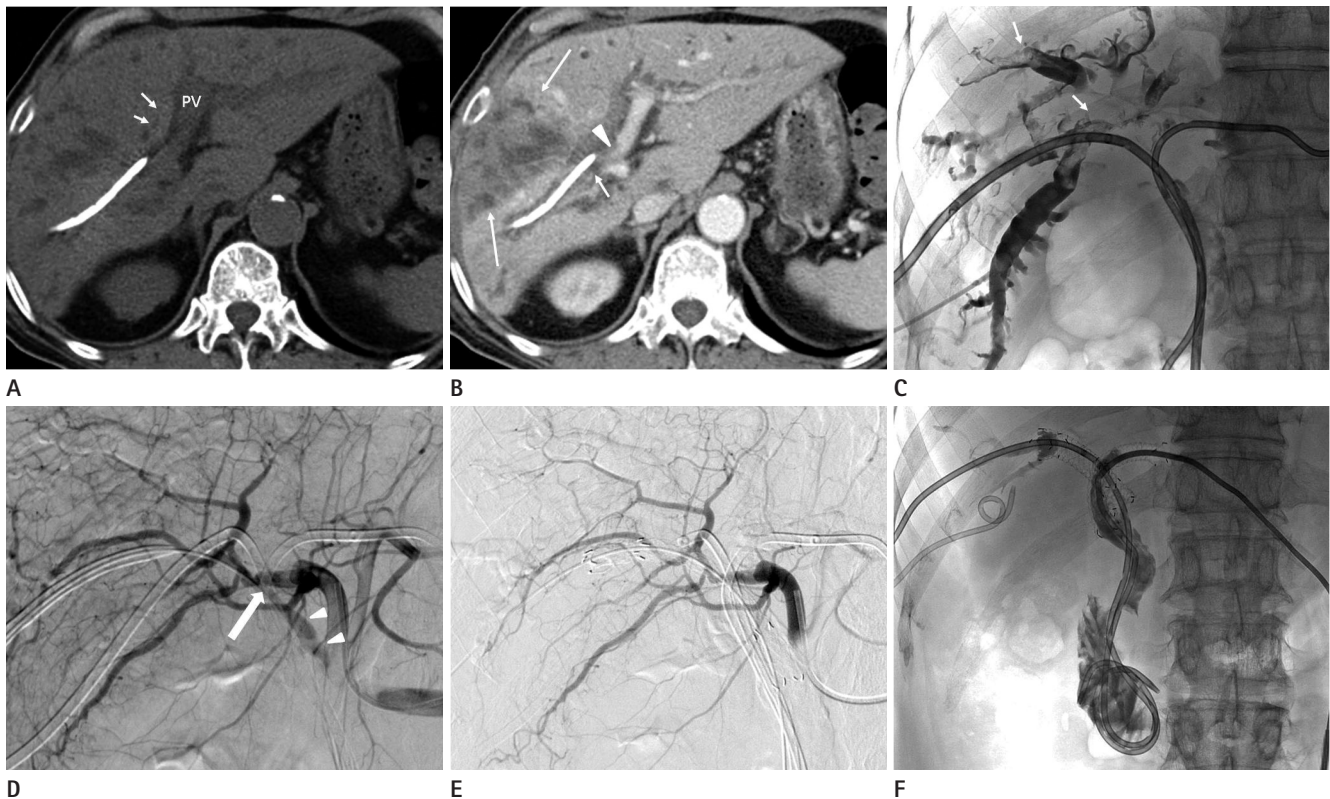


Fig. 1. A 71-year-old man with hilar cholangiocarcinoma and hemobilia.

A. Pre-contrast computed tomographic (CT) scan shows hyperdense left intrahepatic duct (short arrows) adjacent to the portal vein, suggesting hemobilia.

B. Contrast-enhanced CT scan reveals type IIIa hilar cholangiocarcinoma with right portal vein (arrowhead) and right hepatic artery (short arrow) invasion. A wedge-shaped hypo-perfusion area (long arrows) is noted in hepatic segments 5 and 8, suggesting ischemic change due to compromised dual supply.

C, D. Initial cholangiogram (**C**) shows multiple filling defects, suggesting blood clots (short arrows). Right hepatic angiogram (**D**) reveals a fistula between the right hepatic artery and the right intrahepatic duct (long arrow), and shows drainage of contrast media through the right intrahepatic duct and the common hepatic duct (arrowheads).

E, F. A 10 × 50 mm covered self-expandable nitinol stent is successfully deployed at the injured bile duct across the arteribiliary fistula, and a post-procedure hepatic angiogram (**E**) shows the absence of contrast leakage to the intrahepatic bile duct and common hepatic duct. A final cholangiogram (**F**) demonstrates a patent, bare self-expandable nitinol stent within the left intrahepatic duct and common hepatic duct, resulting in a Y-configuration stent by stent graft for bilateral biliary drainage.

Note.—PV = portal vein

in the injured bile duct across the arteriobiliary fistula. Hepatic arteriography after a covered stent graft resulted in non-visualization of the arteriobiliary fistula, along with no active bleeding through the 8 Fr pigtail internal-external drainage catheter within the stent (Fig. 1E). Further, by inserting an 8 × 70 mm bare self-expandable nitinol stent (Hanaro spiral stent; MI Tech, Seoul, Korea) in the left dilated intrahepatic duct through the stiff guide wire, we made a Y configuration stenting technique for bilateral drainage (Fig. 1F).

DISCUSSION

Hemobilia is a well known complication of PTBD. The goals of therapy for hemobilia are to stop the bleeding and restore bile flow past the clots. Persistent hemobilia causes dysfunction of the biliary drainage catheter and leads to hemodynamic consequences. In most cases, hemobilia resolves spontaneously or through catheter upsizing (5, 6). However if the bleeding source is arterial in origin, additional care, such as endovascular embolization or stent graft, is often necessary. Nonoperative treatment of arteriobiliary fistula varies depending on the size and location of the damaged vessels. Hepatic arterial angiography and transarterial embolization is considered as the first line diagnostic tool and treatment option to control bleeding with a high success rate and low complication rate (7, 8). Ideal embolization of an arteriobiliary fistula should be performed as close to the injury site of the hepatic artery as possible. Proximal hepatic embolization is usually well tolerated in patients with normal portal venous flow and does not alter collateral vessels. Rarely, distal hepatic embolization may lead to liver necrosis, even in the presence of normal portal blood flow (9). Hashimoto et al. (10) reported a case of fatal hepatic failure that developed in a patient with severe portal stenosis and segmental infarction after selective embolization of the left hepatic artery for iatrogenic biliary hemorrhage. In our case of synchronized invasion of right portal vein and hepatic artery with hepatic segmental ischemia, proximal embolization of the right hepatic artery could cause a large infarction of the liver and lethal hepatic failure.

In addition to transarterial embolization, the endobiliary stent graft is a known alternative treatment modality (11). During endobiliary placement of a covered stent, extremely precise

deployment at the fistula site with shortest stent length should be taken not to occlude large bile duct branches (11). In our case, the tumor invaded the second order branch level of the right intrahepatic bile duct and right hepatic vessels, resulting in ischemic change and decreased function in the liver segment 8. As liver segment 8 already had vascular compromise in this case, the resulting possible obstruction of the anterior trunk of the right intrahepatic duct due to use of a covered stent graft was not a clinically critical factor. Our goal was to restore biliary patency through a right covered stent and bare stent at the left intrahepatic duct.

Considering the advanced nature of the hilar cholangiocarcinoma and potential risk of arterial embolization, placement of an endobiliary covered stent through the existing tract was thought to be the best alternative and simultaneous treatment option.

In conclusion, endobiliary treatment with a covered stent-graft can be considered as an alternative and simultaneous treatment option for hepatic arteriobiliary fistula and biliary obstruction in patients with a high risk of liver infarction.

REFERENCES

1. Winick AB, Waybill PN, Venbrux AC. Complications of percutaneous transhepatic biliary interventions. *Tech Vasc Interv Radiol* 2001;4:200-206
2. Choi SH, Gwon DI, Ko GY, Sung KB, Yoon HK, Shin JH, et al. Hepatic arterial injuries in 3110 patients following percutaneous transhepatic biliary drainage. *Radiology* 2011; 261:969-975
3. Rami P, Williams D, Forauer A, Cwikiel W. Stent-graft treatment of patients with acute bleeding from hepatic artery branches. *Cardiovasc Intervent Radiol* 2005;28:153-158
4. Takao H, Doi I, Makita K, Watanabe T. Coil embolization of an arteriobiliary fistula caused by hepatic intra-arterial chemotherapy. *Cardiovasc Intervent Radiol* 2005;28:825-827
5. Mitchell SE, Shuman LS, Kaufman SL, Chang R, Kadir S, Kinnison ML, et al. Biliary catheter drainage complicated by hemobilia: treatment by balloon embolotherapy. *Radiology* 1985;157:645-652
6. Merrell SW, Schneider PD. Hemobilia--evolution of current diagnosis and treatment. *West J Med* 1991;155:621-625
7. Basile A, Lupattelli T, Giulietti G, Massa Saluzzo C, Mundo E,

- Carbonatto P, et al. Interventional treatment of iatrogenic lesions and hepatic arteries. *Radiol Med* 2005;110:88-96
8. Nicholson T, Travis S, Ettles D, Dyet J, Sedman P, Wedgwood K, et al. Hepatic artery angiography and embolization for hemobilia following laparoscopic cholecystectomy. *Cardiovasc Intervent Radiol* 1999;22:20-24
9. Doppman JL, Girton M, Kahn R. Proximal versus peripheral hepatic artery embolization experimental study in monkeys. *Radiology* 1978;128:577-588
10. Hashimoto M, Akabane Y, Heianna J, Tate E, Ishiyama K, Nishii T, et al. Hepatic infarction following selective hepatic artery embolization with microcoils for iatrogenic biliary hemorrhage. *Hepatol Res* 2004;30:42-50
11. Tan KC, Kapoor BS. Hepatic arteriovenous fistula successfully treated with an endobiliary covered stent. *J Vasc Interv Radiol* 2008;19:1521-1522

의인성 간동맥-쓸개길 누공의 쓸개길내스텐트 설치술에 의한 성공적인 치료: 증례 보고

송 현 · 이수림 · 구영미 · 전장우

간동맥-쓸개길 누공은 피부간경유쓸개관배액술(percutaneous transhepatic biliary drainage)의 드문 합병증이다. 간동맥 손상에 의한 쓸개관 내 출혈은 보존적인 치료에 잘 반응하지 않으며 추가적인 치료가 필요한 경우가 많다. 간동맥-쓸개길 누공의 일차적 치료는 고식적으로 경동맥 색전술과 혈관내스텐트 설치술이 흔히 이용된다. 경동맥 색전술은 즉각적인 효과와 있으나 고위험 환자에서는 시술 부위의 원위부 순환을 방해하여 간경색을 일으킬 수 있다. 간문부 쓸개길암종에 의한 혈관 침범으로 간경색의 위험이 높은 환자에서 발생한 간동맥-쓸개길 누공을 쓸개길내스텐트 설치술(endobiliary covered stent graft)로 치료하였기에 이를 보고하고자 한다.

가톨릭대학교 의과대학 의정부성모병원 영상의학과