

# Pedunculated Angioleiomyoma of the Nasopharynx: A Case Report<sup>1</sup>

## 비인두의 유경성 혈관평활근종: 증례 보고<sup>1</sup>

Dong Eun Kim, MD<sup>1</sup>, Sang Kwon Lee, MD<sup>2</sup>, Sun Young Kwon, MD<sup>3</sup>, Sang Pyo Kim, MD<sup>3</sup>,  
Byung Hak Rho, MD<sup>2</sup>

Departments of <sup>1</sup>Otolaryngology, <sup>2</sup>Radiology, <sup>3</sup>Pathology, Dongsan Medical Center, Keimyung University School of Medicine, Daegu, Korea

Angioleiomyoma of the pharynx is extremely rare. We report a case of pedunculated angioleiomyoma originating from the posterior nasopharyngeal wall, in a 77-year-old man. Contrast-enhanced CT revealed a well-demarcated, smooth, spherical, pedunculated, solid mass with heterogeneous intense enhancement in the nasopharynx. As a result, nasopharyngeal angioleiomyoma should be included in the differential diagnosis of a pedunculated, solid nasopharyngeal mass with heterogeneous intense enhancement.

### Index terms

Nasopharynx  
Angioleiomyoma  
Computed Tomography, X-Ray

Received August 31, 2011; Accepted November 1, 2011

Corresponding author: Sang Kwon Lee, MD  
Department of Radiology, Dongsan Medical Center,  
Keimyung University School of Medicine,  
56 Dalseong-ro, Jung-gu, Daegu 700-712, Korea.  
Tel. 82-53-250-7735 Fax. 82-53-250-7766  
E-mail: sklee@dsmc.or.kr

Copyrights © 2012 The Korean Society of Radiology

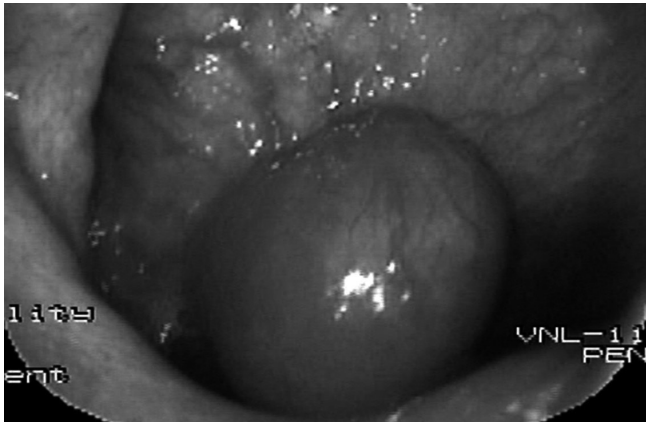## INTRODUCTION

Leiomyomas are generally classified into 3 groups based upon histology: solid leiomyoma, angioleiomyoma, or epithelioid leiomyoma. An angioleiomyoma, a rare benign tumor, is presumed to originate from the tunica media of the veins (1). Pathologically, it is composed of mature smooth muscle cells and numerous blood vessels. It occurs anywhere in the body, most often in the extremities, and especially the leg. In most cases, it occurs as a solitary subcutaneous nodule. Angioleiomyoma of the head and neck is rare (2-5). Angioleiomyoma of the nasopharynx in humans has not been documented in the literature, although a case of angioleiomyoma of the nasopharynx in a dog (6) has been reported. We report a case of pedunculated angioleiomyoma originating from the posterior nasopharyngeal wall in a 77-year-old man, along with laryngoscopic, CT, and pathologic findings.

## CASE REPORT

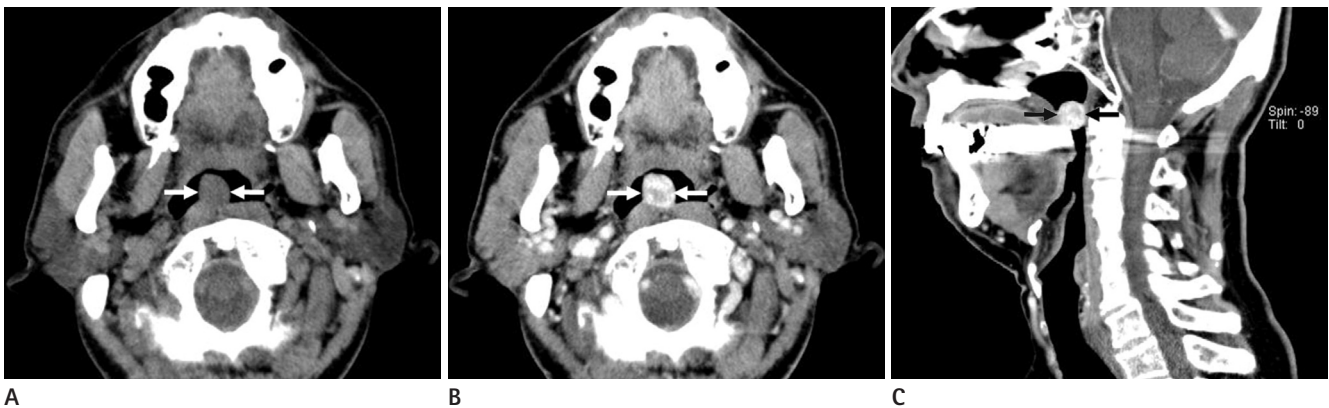A 77-year-old man visited our medical center with a chief

complaint of a foreign body sensation in his throat for 2 weeks and intermittent chronic throat discomfort. In addition, he had globus pharyngeus, but denied odynophagia or dysphagia. About 40 years prior, he had undergone sinonasal surgery for polypoid mass at the left middle meatus. He had been regularly medicated for bronchial asthma diagnosed 7 years prior at another medical center. A laryngoscopic examination revealed an approximately 2 × 2 cm sized spherical mass in the nasopharynx which originated from the posterior nasopharyngeal wall (Fig. 1). The mass moved downward and upward during swallowing and respiration and the throat showed first degree tonsillitis on both sides. The larynx and neck were free of a visible or palpable mass. Non-enhanced CT showed an approximately 17 × 17 × 17 mm (anteroposterior × transverse × longitudinal diameters) sized well-demarcated, smooth, spherical, pedunculated, hypoattenuating mass (compared with the muscular structures of the neck) in the lumen of the nasopharynx (Fig. 2A). Contrast-enhanced CT (CECT) demonstrated a mass with heterogeneous intense enhancement abutting the soft palate and posterior wall of the nasopharynx (Fig. 2B, C). On the basis of CT findings, we suggested minor salivary gland tumor (espe-



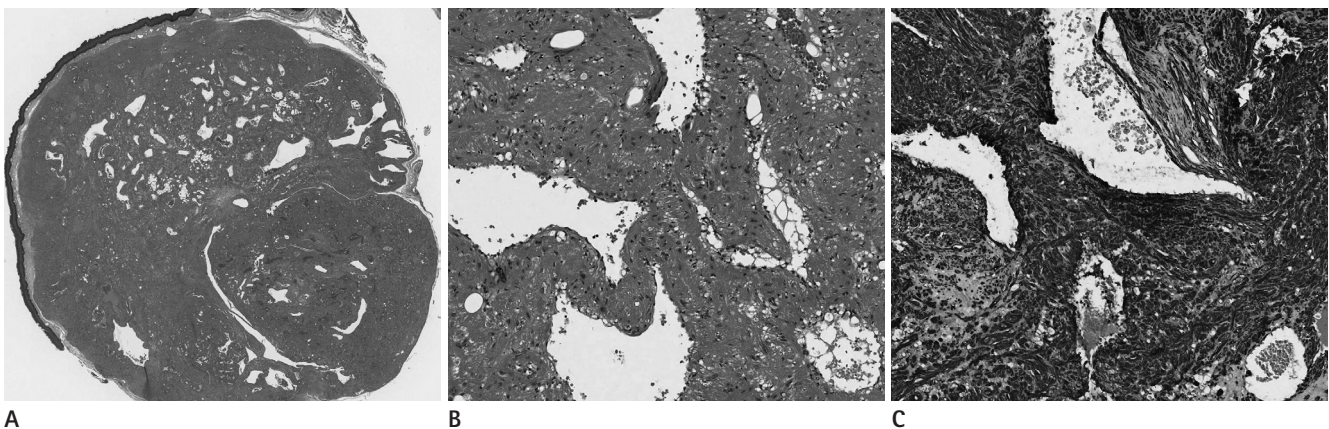
**Fig. 1.** Laryngoscopic examination shows a smooth, spherical mass originating from the posterior wall of the nasopharynx.

cially, pleomorphic adenoma) of the pharyngeal mucosal space as a possible diagnosis. No significant cervical lymphadenopathy was noted. The patient underwent surgical excision of the mass. The mass appeared spherical, pedunculated, and originated from the posterior nasopharyngeal wall. Complete removal of the mass was achieved and the histologic findings were consistent with angioleiomyoma (Fig. 3A, B). An immunohistochemical study demonstrated diffuse, strong positivity for smooth muscle actin (Fig. 3C). No significant bleeding occurred during the operation. The postoperative course was uneventful, and there has been no evidence of tumor recurrence at 12 months after surgery.



**Fig. 2.** CT features of nasopharyngeal angioleiomyoma.

- A.** An axial non-enhanced CT image shows a well-demarcated, smooth, spherical, pedunculated, hypoattenuating (compared with muscular structures) mass (arrows) in the lumen of the nasopharynx which arises from the posterior wall of the nasopharynx.
- B.** An axial contrast-enhanced CT (CECT) image demonstrates a mass (arrows) with heterogenous, intense enhancement.
- C.** A sagittal reformatted CECT image reveals a mass (arrows) abutting the soft palate and the posterior nasopharyngeal wall.



**Fig. 3.** Pathologic features of nasopharyngeal angioleiomyoma.

- A.** A lower power view [hematoxylin-eosin (HE),  $\times 10$ ] shows a well-defined, round, solid mass containing multiple varying-sized tortuous vascular networks with a thickened wall.
- B.** A high power view (HE,  $\times 100$ ) demonstrates that the tumor is composed of a diffuse proliferation of hypertrophied smooth muscle bundles surrounding the dilated vascular structures.
- C.** Immunohistochemical study reveals diffuse strong positivity for smooth muscle actin at the vessels and smooth muscle bundles (original magnification,  $\times 100$ ).

## DISCUSSION

Our case represents the first documented pedunculated nasopharyngeal angioleiomyoma in a human. The mass was well-defined, smooth, spherical, pedunculated, and showed heterogeneous intense enhancement on CECT.

Duhig and Ayer (7) suggested that proliferation of smooth muscle in a hemangioma produces an angioleiomyoma, and that further proliferation produces a simple leiomyoma. Other investigators suggested that an angioleiomyoma arises from vein walls (1). These lesions may be hamartomas (1, 8, 9). Duhig and Ayer (7) also suggest that a number of angioleiomyomas are not true tumors but are instances of vascular malformations.

Angioleiomyomas occur most often in the extremities, particularly the lower leg. Accordingly, most previous studies concerning imaging features of angioleiomyomas have focused on the extremities. Gomez-Dermitt et al. (10) reported sonographic features of 10 subcutaneous angioleiomyomas of the extremities. They concluded that the presence of a well-defined, hypoechoic, vascular subcutaneous tumor in the extremities should raise the possibility of angioleiomyoma. Yoo et al. (11) have described MR imaging findings of angioleiomyomas in the soft tissue of extremities. They noticed that angioleiomyomas are a well-demarcated, subcutaneous mass of isointense signal on T1-weighted images, heterogeneous high signal intensity on T2-weighted images with homogeneous intense enhancement and an adjacent tortuous vascular structure. A comprehensive review of imaging features of angioleiomyoma of the head and neck has not appeared in the literature because of its rarity in this region. Our review of the literature has yielded only 10 case reports concerning the laryngeal angioleiomyoma. Lee and Oh (12) reported a case of angioleiomyoma of the larynx in a 73-year-old man. They noted that the mass is a well-defined, round, broad-based, enhancing mass in the subglottic larynx on CECT. Articles concerning pharyngeal angioleiomyoma rarely appear in the literature (13, 14). Chun et al. (13) reported a case of oropharyngeal angioleiomyoma in a 26-year-old woman. The mass occupied the vallecula and was based on the right lateral oropharyngeal wall and lateral wall of the vallecula. It appeared as a well-defined, spherical, and enhancing mass on CECT. Evans et al. (14) reported a case of pedunculated angioleiomyoma of the vallecula in a 44-year-old man presenting with acute airway

obstruction. The common CT features of the laryngeal and pharyngeal angioleiomyomas in the literature consist of a well-defined, smooth, spherical, pedunculated or nonpedunculated, solid mass with heterogeneous, intense contrast enhancement, as seen in our case. It is extremely rare to encounter a pedunculated mass in the nasopharynx. Nasopharyngeal angioleiomyomas are extremely rare and there were no documented reports concerning imaging features of this entity. Thus, our tentative diagnosis was minor salivary gland neoplasms, especially the pleomorphic adenoma. However, we have not experienced any case of pleomorphic adenoma which has a pedicle, so far. As such, we should have considered pedunculated angioleiomyoma as one of the differential diagnoses. At microscopic examination, the presence of tortuous vascular channels surrounded by smooth muscle bundles and areas of myxoid change explains the heterogeneity and intense enhancement of the tumor on CECT images (11).

In summary, nasopharyngeal angioleiomyomas should be included in the differential diagnosis of a pedunculated, solid nasopharyngeal mass with heterogeneous intense enhancement.

## REFERENCES

1. Stout AP. Solitary cutaneous and subcutaneous leiomyoma. *Am J Cancer* 1937;29:435-469
2. Hirakawa K, Harada Y, Tatsukawa T, Nagasawa A, Fujii M. A case of vascular leiomyoma of the larynx. *J Laryngol Otol* 1994;108:593-595
3. Singh R, Hazarika P, Balakrishnan R, Gangwar N, Pujary P. Leiomyoma of the nasal septum. *Indian J Cancer* 2008;45:173-175
4. Kim HY, Jung SN, Kwon H, Sohn WI, Moon SH. Angiomyoma in the buccal space. *J Craniofac Surg* 2010;21:1634-1635
5. Shetty SC, Kini U, D'Cruz MN, Hasan S. Angioleiomyoma in the tonsil: an uncommon tumour in a rare site. *Br J Oral Maxillofac Surg* 2002;40:169-171
6. Carpenter JL, Hamilton TA. Angioleiomyoma of the nasopharynx in a dog. *Vet Pathol* 1995;32:721-723
7. Duhig JT, Ayer JP. Vascular leiomyoma. A study of sixtyone cases. *Arch Pathol* 1959;68:424-430
8. Hachisuga T, Hashimoto H, Enjoji M. Angioleiomyoma. A clinicopathologic reappraisal of 562 cases. *Cancer* 1984;

54:126-130

9. Hwang JW, Ahn JM, Kang HS, Suh JS, Kim SM, Seo JW. Vascular leiomyoma of an extremity: MR imaging-pathology correlation. *AJR Am J Roentgenol* 1998;171:981-985
10. Gomez-Dermat V, Gallardo E, Landeras R, Echevarria F, Garcia Barredo R. Subcutaneous angioleiomyomas: gray-scale and color Doppler sonographic appearances. *J Clin Ultrasound* 2006;34:50-54
11. Yoo HJ, Choi JA, Chung JH, Oh JH, Lee GK, Choi JY, et al. Angioleiomyoma in soft tissue of extremities: MRI findings. *AJR Am J Roentgenol* 2009;192:W291-W294
12. Lee SW, Oh CH. A case of angioleiomyoma of larynx. *Korean J Otolaryngol-Head Neck Surg* 1998;41:1350-1353
13. Chun JH, Kim HY, Nam SY, Kwon SJ. A case of angioleiomyoma of the oropharyngeal wall. *Korean J Otorhinolaryngol-Head Neck Surg* 2007;50:833-835
14. Evans KL, Lowe DG, Keene MH. Vallecule angioleiomyoma: unusual cause of acute adult airway obstruction. *J Laryngol Otol* 1990;104:341-343

## 비인두의 유경성 혈관평활근종: 증례 보고<sup>1</sup>

김동은<sup>1</sup> · 이상권<sup>2</sup> · 권선영<sup>3</sup> · 김상표<sup>3</sup> · 노병학<sup>2</sup>

인두의 혈관평활근종은 아주 드물다. 저자들은 77세 남자의 비인두 후벽에서 기원한 유경성 혈관평활근종 1예를 보고하고자 한다. 비인두의 혈관평활근종은 조영증강 후 전산화단층촬영 영상에서 경계가 잘 지워지고, 매끄러운, 구형의, 유경성의 고형 종괴로 보였으며, 불균질하고, 강한 조영증강을 보였다. 불균질하고, 강한 조영증강을 보이는 비인두의 유경성의 고형 종괴의 경우, 혈관평활근종을 감별진단에 포함시켜야 할 것으로 생각된다.

계명대학교 의과대학 동산의료원 <sup>1</sup>이비인후과학교실, <sup>2</sup>영상의학과학교실, <sup>3</sup>병리학과학교실