

Miscellaneous Endovascular Treatment of Ruptured Hepatic Artery Pseudoaneurysms after Pylorus Preserving Pancreaticoduodenectomy¹

유문보존 췌십이지장절제술 후의 간동맥 거짓동맥류에 대한 다양한 혈관 내 치료¹

Ung Rae Kang, MD¹, Young Hwan Kim, MD², See Hyung Kim, MD², Eun Joung Ahn, MD², Young Hwan Lee, MD¹

¹Department of Radiology, Catholic University of Daegu School of Medicine, Daegu Catholic University Medical Center, Daegu, Korea

²Department of Radiology, Keimyung University College of Medicine, Keimyung University Dongsan Medical Center, Daegu, Korea

Purpose: To assess the feasibility and safety of the endovascular treatment of ruptured hepatic artery pseudoaneurysms after pylorus preserving pancreaticoduodenectomy (PPPD).

Materials and Methods: Thirteen patients with hepatic artery pseudoaneurysm after PPPD were enrolled. Various endovascular techniques were used depending on the sites and morphologies of the pseudoaneurysms. Five cases were treated by coil embolization, five with stent-graft, one by thrombin injection and coil embolization, one with stent-graft and coil embolization, and one with N-butyl cyanoacrylate (NBCA) injection. Computed tomography scans and liver function test were performed after the procedures.

Results: Pseudoaneurysm exclusion and bleeding cessation was achieved in all patients. In four patients that underwent coil or NBCA embolization of the hepatic artery, aspartate transaminase (AST) and alanine transaminase (ALT) were markedly elevated. Two of these four patients with narrowing of the portal vein due to surrounding hematoma died of hepatic infarction or hepatic abscess. In other nine patients, AST and ALT were unchanged. In the 11 surviving patients, normal hepatic function and complete pseudoaneurysm disappearance were achieved during follow-up.

Conclusion: Endovascular treatment of ruptured hepatic artery pseudoaneurysms can be considered as a feasible and safe method. However, complete occlusion of the hepatic artery with coils should be avoided in patients with inadequate portal flow.

Index terms

Pseudoaneurysm

Pylorus Preserving Pancreaticoduodenectomy

Hepatic Artery

Endovascular Treatment

Received December 2, 2011; Accepted January 17, 2012

Corresponding author: Young Hwan Kim, MD

Department of Radiology, Keimyung University College of Medicine, Keimyung University Dongsan Medical Center, 56 Dalseong-ro, Jung-gu, Daegu 700-712, Korea. Tel. 82-53-250-7767 Fax. 82-53-250-7767

E-mail: yhkim68@dsmc.or.kr

Copyrights © 2012 The Korean Society of Radiology

INTRODUCTION

Gastrointestinal bleeding caused by a pseudoaneurysm is a potentially serious complication after pylorus preserving pancreaticoduodenectomy (PPPD) (1-5), and is a life-threatening vascular lesion because it can cause rupture of pseudoaneurysm in 30-40% of cases, with mortality rate ranging from 23-70% (3-5). This situation can be delayed until after surgery or often after discharge from the hospital. Although computed tomography (CT) will demonstrate bleeding foci with high accu-

racy, angiography is required to reveal the vascular sources. Depending on the patient's clinical condition, several treatments can be used, including surgery and endovascular interventions (6). In the era of improved radiologic intervention, percutaneous techniques have been used as a surgical alternative with increasing frequency for the management of visceral pseudoaneurysms. Several interventional treatments, such as transcatheter embolization, percutaneous thrombin injection, or stent graft placement have been reported for the management of visceral artery pseudoaneurysms (3). However, endo-

vascular treatment of bleeding from hepatic artery pseudoaneurysms after PPPD has rarely been reported (4).

Here, we present our experiences of the endovascular treatment of pseudoaneurysms of the hepatic artery, which were managed using various techniques and materials after considering the sites and morphologies of the pseudoaneurysms, the states of portal veins, and patient condition.

MATERIALS AND METHODS

Patients

Thirteen patients with bleeding from a hepatic artery pseudoaneurysm after PPPD were treated using miscellaneous endovascular techniques. Our institutional review board approved the retrospective study and informed consent was obtained from all 13 patients. Radiologic findings and medical records were retrospectively reviewed. PPPD was performed to treat distal common bile duct cancer in seven patients, pancreatic cancer in four patients, and Ampulla of Vater cancer in two patients. The study cohort consisted of nine men and four women of mean age 65.9 years (range, 54-76 years). In 10 patients, diagnosis was achieved at time of rupture with an elapsed time of approximately 2 weeks post-PPPD. Three patients had already been discharged from the hospital when the bleeding occurred. Median time from PPPD to a definitive diagnosis of a ruptured hepatic artery pseudoaneurysm by CT scan obtained immediately after development of symptoms was 10.8 days (range, 3-30 days). Nine patients showed hypotension, gastrointestinal bleeding, and bleeding into a surgical drainage bag. Four patients complained of sudden abdominal pain and a reduction in hemoglobin level. All patients underwent a CT scan for lesion identification and treatment planning. CT scans depicted the pseudoaneurysm with surrounding hematoma around the hepatic artery in all cases.

Angiographic Findings

Diagnostic angiography and embolization were performed simultaneously during a single session for all 13 patients, and all underwent emergency treatment with vital sign monitoring. Selective angiography of the common hepatic artery was performed using a 5 Fr catheter (Cook, Bloomington, IN, USA) via the common femoral artery. Superior mesenteric angiography

was then performed to obtain an indirect portogram. The endovascular technique was decided after the angiography finding. Examples included coil embolization of the hepatic artery, N-butyl cyanoacrylate (NBCA) embolization of the hepatic artery, stent graft, thrombin injection, or a combination technique based on considerations of location and morphology of the pseudoaneurysm neck, patency of the portal vein, anatomy of the hepatic artery including its variation and tortuosity, and device availability. A pseudoaneurysm was located in the common hepatic artery in six patients, stump of the gastroduodenal artery in four patients, proper hepatic artery in two patients, and in the replaced right hepatic artery in one patient. Pseudoaneurysms were saccular in all 13 cases. Among them, 11 had a short and wide neck, one had a short and narrow neck, and the other had a relatively long and narrow neck, which was suitable for coil embolization with preservation of the hepatic artery. Both pseudoaneurysms with a narrow neck were located in the gastroduodenal artery stump. In eight patients, the main portal vein was narrowed due to extrinsic compression by the surrounding hematoma. In the remaining five patients, the main portal vein was patent. Anatomical variation was present in five patients. An aberrant left hepatic artery from the left gastric artery was present in two patients, a replaced right hepatic artery from superior mesenteric artery was present in two patients, and a common hepatic artery from the superior mesenteric artery was present in one patient. Celiac axis stenosis or arterial tortuosity that made it difficult to advance the guiding catheter into the hepatic artery was encountered in three patients.

Procedure Selection

A summary of endovascular procedures utilized is provided in Table 1. The preservation of hepatic arterial flow was our main consideration when deciding on the optimal endovascular technique. Thus, coil embolization of the neck or stent graft placement was initially attempted.

In two patients with a narrowed pseudoaneurysm neck, coil embolization of the neck was performed to treat the patient with a narrow and long neck. The patient with a narrow, short pseudoaneurysm neck was treated by coil embolization of the neck after injecting thrombin into the lumen of the pseudoaneurysm to prevent coil migration into the lumen. A 500 unit single bolus of bovine thrombin (D-STAT; Vascular Solution,

Table 1. Patient Characteristics and Techniques of Endovascular Treatment

No.	Sex/Age	Disease	Location	Day (Po)	AV	Materials	Techniques
1	M/72	Distal CBD Ca	CHA	5 days	No	Stent, coil	3 mm stent-graft + coil embolization of gap
2	F/68	Pancreatic head Ca	GDA stump	6 days	ALHA	Coil	Endovascular exclusion of hepatic artery
3	M/69	Ampullar of Vater Ca	CHA	7 days	No	Stent	6 mm stent-graft
4	M/67	Distal CBD Ca	PHA	12 days	No	Coil	Endovascular exclusion of hepatic artery
5	F/67	Distal CBD Ca	CHA	9 days	RCHA	Glue	Endovascular exclusion of hepatic artery
6	F/60	Distal CBD Ca	CHA	3 days	No	Stent	6 mm stent-graft
7	M/71	Pancreatic head Ca	CHA	5 days	No	Coil	Coil embolization of neck
8	M/54	Pancreatic head Ca	GDA stump	30 days	No	Thrombin, coil	500 IU thrombin intravascular injection + coil embolization of neck
9	M/62	Distal CBD Ca	GDA stump	10 days	No	Coil	Endovascular exclusion of hepatic artery
10	M/56	Ampulla of Vater Ca	CHA	8 days	No	Stent	6 mm stent-graft
11	M/76	Pancreatic head Ca	GDA stump	25 days	ALHA, RRHA	Coil	Endovascular exclusion of middle hepatic artery
12	F/76	Distal CBD Ca	RHA	3 days	RRHA, CTO	Stent	6 mm stent-graft
13	M/59	Distal CBD Ca	PHA	18 days	No	Stent	6 mm stent-graft

Note.—ALHA = aberrant left hepatic artery from left gastric artery, AV = anatomical variation, Ca = common artery, CBD = common bile duct, CHA = common hepatic artery, CTO = celiac trunk occlusion, GDA = gastroduodenal artery, PHA = proper hepatic artery, Po = post-operative, RCHA = replaced common hepatic artery from superior mesenteric artery, RRHA = replaced right hepatic artery from superior mesenteric artery

Minneapolis, MN, USA) was injected through a 2.4 Fr microcatheter (Progreat, Terumo, Tokyo) into the lumen after occluding the pseudoaneurysm neck with a 4 mm-diameter balloon (Hyperform; EV3, Irvine, CA, USA) to prevent reflux of thrombin into the hepatic artery. When pseudoaneurysmal flow ceased, the neck of the pseudoaneurysm was embolized using a Tornado microcoil (Cook, Bloomington, IN, USA) to prevent blood inflow into the pseudoaneurysm and recurrence.

Six patients with a wide pseudoaneurysm neck were treated by use of a Jo stent graft (Abbott, Rangendingen, Germany). In four of these six patients, the main portal vein was narrowed due to extrinsic compression by hematoma. Initially, an 8 Fr guiding catheter (Cordis, Miami, FL, USA) was positioned at the origin of the hepatic artery and, after passing a guide wire across the pseudoaneurysm, a balloon expandable stent-graft was implanted in the involved hepatic artery (Fig. 1). Diameters of stent graft ranged from 4-7 mm in five of the six patients. The remaining patient was treated using a 3 mm Jo stent graft and by coil embolization of the gap between the stent graft and the hepatic artery. In this patient, contrast filling of the pseudoaneurysm through a gap between the stent-graft and the neck was done by immediate post-procedural angiography, and the gap due to mismatch between the stent-graft and diameter of artery was super-selectively cannulated using a 2.4 Fr microcatheter and embolized using microcoils. Subsequently, there

was no evidence of pseudoaneurysm filling.

Five patients with a wide pseudoaneurysm neck were treated by complete occlusion of the hepatic artery using microcoils or NBCA (Histoacryl; B. Braun, Melsungen, Germany), either because no stent graft was available at that time or because the guiding catheter could not advanced into the hepatic artery due to celiac axis stenosis or arterial tortuosity. Three of these five patients had an intact portal vein. One of the three patients had the common hepatic artery replaced from the superior mesenteric artery, one patient had an aberrant left hepatic artery replaced from the left gastric artery, and the remaining patient had a replaced right hepatic artery replaced from the superior mesenteric artery. In the patient with a replaced common hepatic artery, the pseudoaneurysm as well as inflow and outflow hepatic artery were embolized by injecting NBCA diluted 1 : 1 with Lipiodol Ultrafluid (Guerbet, Aulnay-Sous-Bois, France) to avoid glue migration into the peripheral hepatic artery. Microcoils were used in the other four patients to occlude the hepatic artery. To achieve complete occlusion of the hepatic artery, endovascular exclusion with coils or NBCA across the pseudoaneurysm to prevent rebleeding due to collateral flow from the distal hepatic artery was performed (Fig. 2).

Technical success was defined as complete pseudoaneurysm exclusion by immediate post-procedural angiography. Laboratory data and CT scans were obtained during follow-up to de-

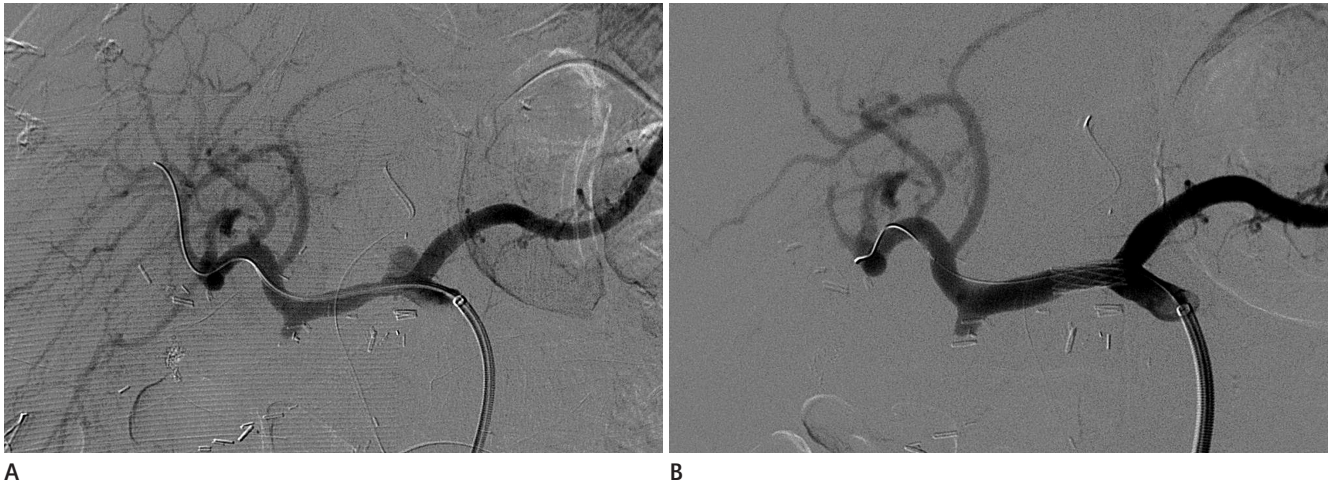


Fig. 1. A 69-year-old man with ampulla of Vater cancer.
A. Celiac angiograph shows a pseudoaneurysm with wide neck in the common hepatic artery.
B. After deployment of a stent graft, the pseudoaneurysm disappeared and the hepatic artery was preserved.

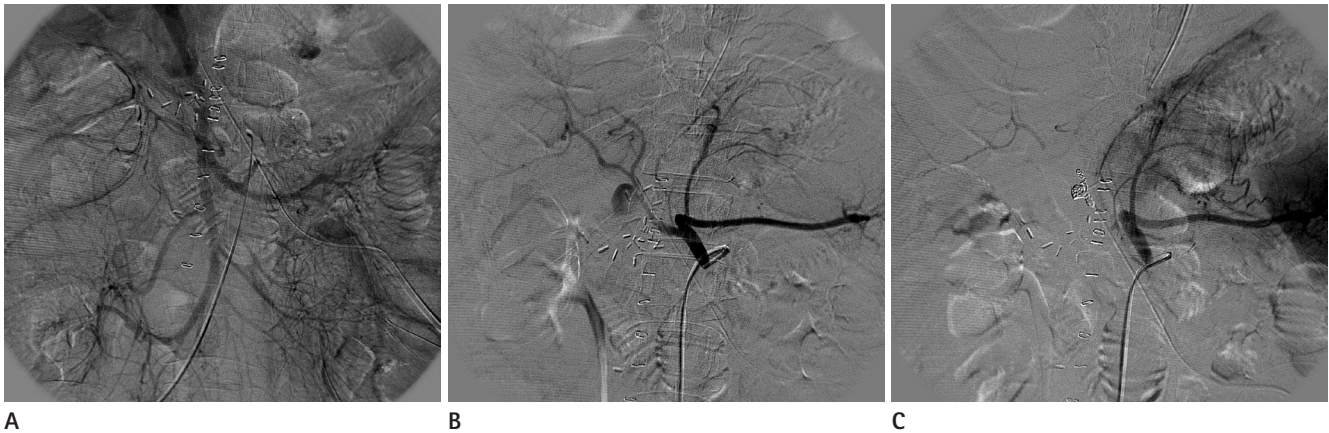

Fig. 2. A 62-year-old man with distal CBD cancer.
A. Indirect portogram shows a patent portal vein without stenosis.
B. Celiac angiograph reveals a pseudoaneurysm arising from the stump of the gastroduodenal artery.
C. Celiac angiograph obtained immediately after hepatic artery occlusion showing intra-hepatic arterial flow through the right inferior phrenic artery. Liver function was aggravated immediately after the procedure, but was normalized 1 week later.
 Note. —CBD = common bile duct

tect procedure-related complications and to ensure complete thrombosis of pseudoaneurysms.

RESULTS

The results of endovascular treatment and clinical follow-up are summarized in Table 2. In all cases, post-procedural angiography revealed complete pseudoaneurysm exclusion. All patients rapidly regained hemodynamic stability and had an excellent subsequent recovery. After definite bleeding control, a clinically relevant complication, including marked hepatic enzyme elevation, occurred only in those patients who had un-

dergone hepatic artery occlusion using coil or NBCA. In five patients with complete hepatic artery occlusion using coil or NBCA, intra-hepatic arterial flow was observed via collateral supply by an aberrant left hepatic artery, the replaced right hepatic artery or right inferior phrenic artery by immediate post-procedural angiography. In these five patients, two with portal vein narrowing due to surrounding hematoma died of hepatic infarction or an abscess at 7 and 10 days post-procedure, respectively (Fig. 3). In the other three patients, the increased hepatic enzyme levels were normalized by 1 week after the procedure. Follow-up CT scans (range, 6-24 months) obtained for 11 patients showed complete disappearance of pseudoaneurysm.

Table 2. Results of Endovascular Treatment

No.	F/U Periods	Complication	PVF	Collaterals	Hepatic Enzyme (GOT, GPT)	Final Outcome
					(1 Day/< 1 Week/< 1 Month/< 6 Months)	
1	10 months	No	Insufficient	No	(88, 64/85, 63/56, 47/29, 26)	Recovery
2	10 days	Abscess	Insufficient	ALHA	(2103, 1000/419, 470/X/X)	Die
3	12 months	No	Sufficient	No	(75, 52/55, 33/36, 25/27, 25)	Recovery
4	1 week	Infarction	Insufficient	RIPA	(3632, 940/3103, 2826/X/X)	Die
5	9 months	No	Sufficient	RIPA	(133, 89/63, 43/28, 15/26, 22)	Recovery
6	6 months	No	Insufficient	No	(70, 46/43, 32/30, 26/26, 23)	Recovery
7	7 months	No	Insufficient	No	(19, 27/25, 26/24, 31/21, 21)	Recovery
8	24 months	No	Insufficient	No	(85, 65/66, 53/44, 39/45, 38)	Recovery
9	11 months	No	Sufficient	RIPA	(330, 289/185, 175/63, 52/41, 34)	Recovery
10	7 months	No	Insufficient	No	(60, 45/55, 35/34, 25/25, 23)	Recovery
11	3 months	No	Sufficient	ALHA, RRHA	(40, 12/35, 12/X/24, 13)	Recovery
12	3 months	No	Insufficient	No	(29, 24/42, 27/20, 11/24, 10)	Recovery
13	3 months	No	Sufficient	No	(59, 22/48, 40/23, 9/X)	Recovery

Note.—ALHA = aberrant left hepatic artery, GOT = glutamic oxaloacetic transaminase, GPT = glutamic pyruvic transaminase, PVF = portal vein flow, RIPA = right inferior phrenic artery, RRHA = replaced right hepatic artery

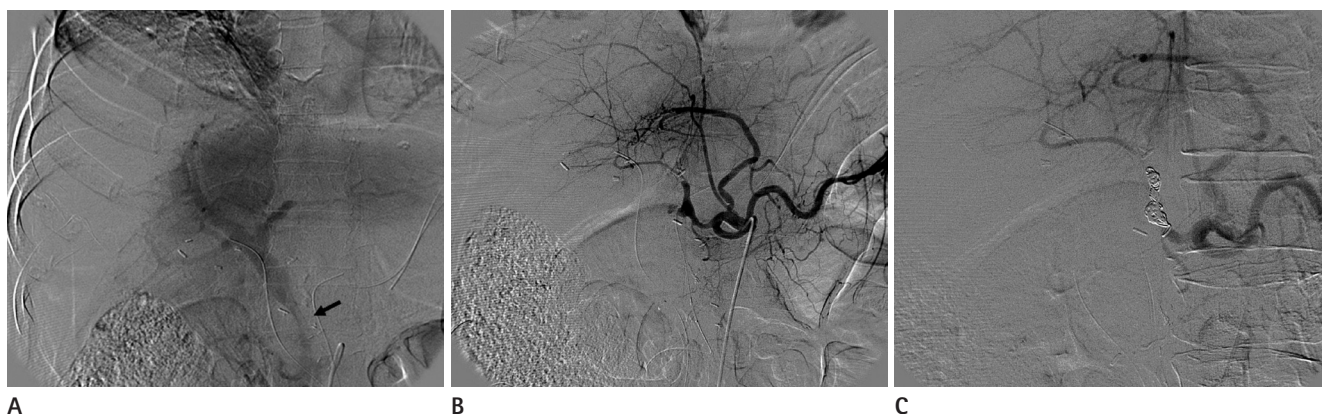


Fig. 3. A 68-year-old woman with pancreatic head cancer.

A. Indirect portogram obtained by superior mesenteric angiography showing extrinsic compression of the portal vein (arrow) by surrounding hematoma.

B. Celiac axis angiograph shows a pseudoaneurysm arising from the stump of the gastroduodenal artery. The aberrant left hepatic artery originated from the left gastric artery.

C. After occlusion of the common hepatic artery with coils, intra-hepatic arterial flow was observed by angiography via an aberrant left hepatic artery. The patient succumbed to sepsis caused by a hepatic infarction and subsequent hepatic abscess development in the right lobe 10 days after the procedure.

DISCUSSION

Hepatic artery pseudoaneurysms are rarely encountered after PPPD. Of the 37 patients found with visceral artery pseudoaneurysms, 19 had a hepatic artery pseudoaneurysm, according to data from the Mayo Clinic (7). More recently, Otah et al. (8) reported five cases of pseudoaneurysm after PPPD - two of the left hepatic artery, one of the right hepatic artery, one of the gastroduodenal artery stump, and one of the replaced right hepatic artery. Healthy tissue covering vessels is removed during

surgery, which exposes the adventitia to pancreatic juice or inflammation. Other possible causes include direct vascular injury during dissection or retraction, vessel clamp injuries, or dermal injuries caused by electrocautery. Stump pseudoaneurysms of the gastroduodenal artery are caused by insufficient suture and ligation. Potential lethal bleeding can occur early or late during the postoperative period (2).

The traditional treatment of hepatic artery pseudoaneurysms consists of open ligation, or excision and vascular reconstruction. However, good immediate outcomes for endovascular treatment

with success rates ranging from 67-100% have been reported recently (8, 9). Our patients were hemodynamically unstable at the time of diagnosis and would probably not have survived open surgery. Accordingly, an endovascular approach was evidently the optimal choice, and the endovascular procedures used included coil embolization, stent-graft, thrombin injection, and NBCA injection.

Traditionally, embolization using various embolic agents has been used to treat visceral artery pseudoaneurysms to exclude both vessel inflow and outflow, and, thus, to reduce the risk of antegrade and retrograde reperfusion. It is important to take care to avoid intraluminal pressure elevation because of the risk of sudden rupture during the procedure. The choice of embolization methods depends on the situation encountered. Coils are the first considered preferred embolic material, and can be used alone or as a mixture with NBCA. They can be delivered via catheter into the sac or neck, or positioned proximally and distally to the origin of the pseudoaneurysm to occlude possible antegrade and retrograde sac filling (10-13). NBCA is another favored embolic material. In one of our patients, a pseudoaneurysm in the replaced common hepatic artery was embolized with NBCA. Catheterization was not possible across the pseudoaneurysm in this case, and intraluminal irritation induced by repeated catheterization could have increased the risk of rupture. NBCA has several advantages as compared with other embolic materials, as it allows rapid and permanent embolization and polymerization rapidly in blood. This material allows complete hemostasis to be achieved by a single injection and simultaneously embolizes collateral vessels connected to the bleeding focus (14). NBCA embolization is highly effective and safe, especially when it is technically difficult to advance the microcatheter to the distal pseudoaneurysm. Appropriate indications and careful procedures are chosen by adequately trained physicians. During coil or NBCA treatment, potentially serious complications in addition to the hemorrhage itself must be considered. For example, occlusion of the common hepatic artery by coils may harm the liver. Although inadequately reported, a lack of arterial supply to the liver may lead to hepatic insufficiency, infarction, intrahepatic abscess formation, or extrahepatic bile duct complication after the procedure (15). In the present study, two of five patients that underwent coil or NBCA embolization of the hepatic artery eventually died of a hepatic

infarction and a hepatic abscess, respectively. In another three patients with collateral supplies and a patent portal vein, hepatic function recovered 1 week post-procedurally without further complications. In the two patients that expired, intra-hepatic arterial flows via collaterals were noted by post-procedural celiac angiography, but portal vein flow was inadequate by superior mesenteric angiography due to extrinsic compression of the portal vein by a surrounding large hematoma. Therefore, in spite of collateral blood supply to liver after embolization of hepatic artery, insufficient portal flow may result in hepatic insufficiency.

To avoid complications caused by arterial occlusion and to control bleeding, a stent-graft should be considered. Stent graft of pseudoaneurysms of the common hepatic artery may be crucial in patients who undergo PPPD, because coil embolization of common hepatic artery probably presents a greater risk of liver insufficiency and infarction due to an occluded collateral circulation from the gastroduodenal artery and pancreaticoduodenal arcade. The majority of our patients who underwent stent-graft placement showed decreased portal flow due to extrinsic compression by hematoma. Therefore, the potential risk of hepatic infarction after coil embolization was considerably higher than had the portal vein been intact. In all patients, placement of the stent graft retained antegrade hepatic arterial flow with complete exclusion of pseudoaneurysm, and hepatic enzyme levels were unchanged. In one case, the filling of aneurysmal sac through a gap between the stent-graft and the neck was identified by immediate post-operative angiography (this had occurred because the correct stent size was not available). Nevertheless, the gap was successfully embolized using microcoils. Completion angiography revealed 50% narrowing of the common hepatic artery due to the placement of a stent-graft with a diameter smaller than that of the common hepatic artery. Nonetheless, hepatic insufficiency did not develop. Stent-graft placement across pseudoaneurysm neck was first reported by Bürger et al. (16), and its use is related to a favorable arterial anatomy (17). The arterial anatomy, and the diameter and location of pseudoaneurysms have a substantial technical impact. The arterial diameter must be suitable to allow an adequate seal and achieve complete exclusion. The tortuosity of visceral vessels can also cause navigation difficulties. Further technical developments with respect to more flexible stent-grafts and smaller delivery systems are needed before this treatment can be of-

ferred to a wider population, and stent-grafts that better preserve hepatic flow might provide a safe and efficacious alternative to coil embolization.

Percutaneous thrombin injection has been used to treat iatrogenic pseudoaneurysms of the femoral artery and, in a limited number of cases, a thrombin injection has been used to treat visceral artery pseudoaneurysm (18-20). Thrombin converts inactive fibrinogen to fibrin, which causes thrombus formation. In our case, we did not use CT- or ultrasound-guided thrombin injection because of anatomical difficulties. Therefore, a direct intravascular injection was preferred. Thrombin administration during the acute phase reduces the pressure inside the sac and diminishes the risk of rupture. After administering thrombin, we embolized the pseudoaneurysm neck to close inflow and prevent rebleeding. We believe that this combination approach provides a possible valid alternative for large saccular pseudoaneurysms with a short and narrow neck, as is shown presently.

In conclusion, miscellaneous endovascular procedures can be considered feasible and effective for the treatment of ruptured pseudoaneurysms of the hepatic artery after PPPD in an emergent situation, with the caution that total occlusion of the hepatic artery with coils should be avoided in patients with a portal flow insufficiency.

REFERENCES

1. Choi SH, Moon HJ, Heo JS, Joh JW, Kim YI. Delayed hemorrhage after pancreaticoduodenectomy. *J Am Coll Surg* 2004;199:186-191
2. Harvey J, Dardik H, Impeduglia T, Woo D, DeBernardis F. Endovascular management of hepatic artery pseudoaneurysm hemorrhage complicating pancreaticoduodenectomy. *J Vasc Surg* 2006;43:613-617
3. Laganà D, Carrafiello G, Mangini M, Dionigi G, Caronno R, Castelli P, et al. Multimodal approach to endovascular treatment of visceral artery aneurysms and pseudoaneurysms. *Eur J Radiol* 2006;59:104-111
4. Makowiec F, Riediger H, Euringer W, Uhl M, Hopt UT, Adam U. Management of delayed visceral arterial bleeding after pancreatic head resection. *J Gastrointest Surg* 2005;9:1293-1299
5. Santoro R, Carlini M, Carboni F, Nicolas C, Santoro E. Delayed massive arterial hemorrhage after pancreaticoduodenectomy for cancer. Management of a life-threatening complication. *Hepatogastroenterology* 2003;50:2199-2204
6. Saad NE, Saad WE, Davies MG, Waldman DL, Fultz PJ, Rubens DJ. Pseudoaneurysms and the role of minimally invasive techniques in their management. *Radiographics* 2005;25 Suppl 1:S173-S189
7. Tessier DJ, Fowl RJ, Stone WM, McKusick MA, Abbas MA, Sarr MG, et al. Iatrogenic hepatic artery pseudoaneurysms: an uncommon complication after hepatic, biliary, and pancreatic procedures. *Ann Vasc Surg* 2003;17:663-669
8. Otah E, Cushin BJ, Rozenblit GN, Neff R, Otah KE, Cooperman AM. Visceral artery pseudoaneurysms following pancreaticoduodenectomy. *Arch Surg* 2002;137:55-59
9. Kasirajan K, Greenberg RK, Clair D, Ouriel K. Endovascular management of visceral artery aneurysm. *J Endovasc Ther* 2001;8:150-155
10. Baker KS, Tisnado J, Cho SR, Beachley MC. Splanchnic artery aneurysms and pseudoaneurysms: transcatheter embolization. *Radiology* 1987;163:135-139
11. Reber PU, Baer HU, Patel AG, Wildi S, Triller J, Büchler MW. Superselective microcoil embolization: treatment of choice in high-risk patients with extrahepatic pseudoaneurysms of the hepatic arteries. *J Am Coll Surg* 1998;186:325-330
12. Yamakado K, Nakatsuka A, Tanaka N, Takano K, Matsumura K, Takeda K. Transcatheter arterial embolization of ruptured pseudoaneurysms with coils and n-butyl cyanoacrylate. *J Vasc Interv Radiol* 2000;11:66-72
13. Parildar M, Oran I, Memis A. Embolization of visceral pseudoaneurysms with platinum coils and N-butyl cyanoacrylate. *Abdom Imaging* 2003;28:36-40
14. Schoder M, Cejna M, Längle F, Hittmaier K, Lammer J. Glue embolization of a ruptured celiac trunk pseudoaneurysm via the gastroduodenal artery. *Eur Radiol* 2000;10:1335-1337
15. Teramoto K, Kawamura T, Takamatsu S, Noguchi N, Arai S. A case of hepatic artery embolization and partial arterialization of the portal vein for intraperitoneal hemorrhage after a pancreaticoduodenectomy. *Hepatogastroenterology* 2003;50:1217-1219
16. Bürger T, Halloul Z, Meyer F, Grote R, Lippert H. Emergency

- stent-graft repair of a ruptured hepatic artery secondary to local postoperative peritonitis. *J Endovasc Ther* 2000;7: 324-327
17. Larson RA, Solomon J, Carpenter JP. Stent graft repair of visceral artery aneurysms. *J Vasc Surg* 2002;36:1260-1263
18. Carrafiello G, Laganà D, Recaldini C, Mangini M, Lumia D, Giorgianni A, et al. Combined percutaneous thrombin injection and endovascular treatment of gastroduodenal artery pseudoaneurysm (PAGD): case report. *Emerg Radiol* 2007;14:51-54
19. Benjaminov O, Atri M. Percutaneous thrombin injection for treatment of an intrarenal pseudoaneurysm. *AJR Am J Roentgenol* 2002;178:364-366
20. Kang SS, Labropoulos N, Mansour MA, Michelini M, Filliung D, Baubly MP, et al. Expanded indications for ultrasound-guided thrombin injection of pseudoaneurysms. *J Vasc Surg* 2000;31:289-298

유문보존 채십이지장절제술 후의 간동맥 거짓동맥류에 대한 다양한 혈관 내 치료¹

강웅래¹ · 김영환² · 김시형² · 안은정² · 이영환¹

목적: 유문보존 채십이지장절제술 후에 발생한 파열된 간동맥 거짓동맥류에 대한 혈관 내 치료의 적합성과 안정성을 평가하고자 한다.

대상과 방법: Pylorus preserving pancreaticoduodenectomy 후 간동맥 거짓동맥류가 발생한 13명의 환자를 대상으로 하였으며, 거짓동맥류의 위치와 모양에 따라 다양한 혈관 내 치료술을 시행하였다. 시행한 혈관 내 치료술은 코일색전술 5예, 스텐트 이식편 5예, 코일색전술 및 트롬빈주입 1예, 스텐트 이식편과 코일색전술 1예, N-butyl cyanoacrylate (NBCA) 주입 1예였다. 시술 후 CT 촬영과 간기능 검사를 시행하였다.

결과: 모든 환자에서 시술 후 거짓동맥류의 소실과 지혈이 확인되었다. 코일색전술과 NBCA 주입한 4명의 환자에서 aspartate transaminase (AST)와 alanine transaminase (ALT)의 상당한 증가가 관찰되었다. 이들 4명 중 2명은 혈중에 의한 간문맥 협착이 있던 환자로, 시술 후 간경색과 간농양으로 사망하였다. 다른 9명의 환자에서는 AST와 ALT의 증가가 없었다. 생존한 11명의 환자는 추적검사상 정상 간기능을 보였으며, 거짓동맥류의 완전소실이 관찰되었다.

결론: 파열된 간동맥 거짓동맥류의 혈관 내 치료는 적합하고 안전한 치료 방법으로 생각될 수 있다. 그러나 간문맥 혈류량이 충분하지 않은 환자에 있어서 간동맥의 완전 코일색전술은 피하여야 한다.

¹대구가톨릭대학교 의과대학 대구가톨릭대학교병원 영상의학과학교실,

²계명대학교 의과대학 동산의료원 영상의학과학교실