

Variation of the Degree of Coronary Artery Stenosis during the Cardiac Cycle: Influence of Heart Rate or Calcium Score on Coronary CT Angiography¹

심장박동수 또는 석회수치에 따른 수축기와 이완기 말기에서 협착된 관상동맥의 직경 변화 측정¹

Hyun Kyung Lee, MD¹, Gong Yong Jin, MD¹, Jae Keun Park, MD¹, Young Min Han, MD¹, Young Sun Lee, MD¹, Keun Sang Kwon, MD², Song Soo Kim, MD³

Departments of ¹Radiology, ²Preventive Medicine, Chonbuk National University Hospital and Medical School, Research Institute of Clinical Medicine, Institute of Cardiovascular Research, Jeonju, Korea

³Department of Radiology, Chungnam National University Hospital, Chungnam National University School of Medicine, Daejeon, Korea

Purpose: To assess the stenotic coronary artery diameter in systole and end-diastole by coronary CT angiography and to evaluate the change in diameter according to heart rate and calcium score.

Materials and Methods: Twenty-seven patients with coronary artery stenosis that underwent a coronary CT angiography and invasive coronary angiography were enrolled in the study. We assessed the percentage of diameter change in the stenotic coronary artery between the systolic and end-diastolic phase and evaluated its relationship with heart rate or Agatston score using a linear regression analysis.

Results: The mean difference in the change of vessel diameter was 12.9% for a heart rate of 50-59 beats/min (bpm), 11.3% for 60-69 bpm, 10% for 70-79 bpm, 20% for 80-89 bpm, 13% for 90-99 bpm, and 6.7% for 100-109 bpm, none of which were statistically significant ($p = 0.760$). For the Agatston score, the mean difference in the change of vessel diameter was 8.3% for a score < 100, 12.4% for 100-400, and 20% for > 400. The relationship between the change in diameter and Agatston score was statistically significant ($p = 0.004$).

Conclusion: The data suggest that a change in diameter of the stenotic coronary artery in systole and end-diastole might be affected by the Agatston score.

Index terms

Diagnosis
Computer-Assisted
Dual Source Computed Tomography
Coronary Angiography
Coronary Stenosis

Received September 28, 2011;

Accepted January 10, 2012

Corresponding author: Gong Yong Jin, MD
Department of Diagnostic Radiology, Chonbuk National University Hospital and Medical School, 20 Geonji-ro, Deokjin-gu, Jeonju 561-712, Korea.
Tel. 82-63-250-2307 Fax. 82-63-272-0481
E-mail: gyjin@chonbuk.ac.kr

Copyrights © 2012 The Korean Society of Radiology

INTRODUCTION

Dual source computed tomography (DSCT) has provided the best image on coronary CT angiography (CCTA) in order to achieve high diagnostic accuracy for coronary artery stenosis (1-4). With recent technical developments, there were no significant differences in image quality or diagnostic performance among different heart rate frequencies when an adaptive electrocardiography (ECG)-pulsing algorithm used. However, a trend toward increased false positives in patients with low calcium scores (Agatston score < 100) or heart rate variability of more than 10 was still observed (5-8). Indeed, if we obtain a

poor image for assessing the stenotic coronary artery on the diastolic phase of CCTA because of high heart rate or high calcium score, we often hesitate to re-check the CCTA after the heart rate has decreased, or select a proper systolic phase for evaluating the stenotic coronary artery if we cannot perform CCTA again.

Recently, several papers have focused on the diagnostic accuracy of coronary artery stenosis or image quality of the coronary artery on CCTA based on an invasive coronary angiography (ICA) in the diastolic phase (2, 4, 5). If the best image for coronary artery stenosis is obtained on the systolic phase, we should compare the same stenotic portion of coronary vessel in

systolic phase on CCTA with the diastolic phase on ICA. For this reason, it is important to understand changes in the stenotic coronary vessel using DSCT during diastole and systole at the same stenotic site with respect to heart rate and calcium score.

This study was designed to assess the difference in diameter of the stenotic coronary artery between the in-systolic and end-diastolic phase on CCTA according to heart rate and calcium score. We also evaluated the diagnostic accuracy of CCTA for coronary artery stenosis during systolic and end-diastolic phase base by comparing it with invasive ICA as a reference value.

MATERIALS AND METHODS

Study Population

This study was performed prospectively with the approval of the institutional ethics committee at our institution. Written informed consent was obtained from all patients. From November 2007 to January 2008, 347 patients with chest pain underwent DSCT examinations. Among these patients, 27 (13 men and 14 women; age range 46-78 years, mean age 63.1 ± 8.4 years) with coronary artery stenosis on DSCT images and ICA were enrolled. The mean time interval between CCTA and ICA was 5.2 ± 2.1 days (range, 0-8 days). Patients who were pregnant or who had unstable clinical conditions, severe renal failure, previous allergic reactions to the use of an iodinated contrast agent, hyperthyroidism, any circumstances that would not allow the patient to lie in the supine position or patients who had inserted coronary stents or who had undergone previous bypass surgery, were excluded from the study. In addition, image quality of a stenotic coronary segment that was assessed for moderate artifacts with diagnostic or severe artifacts impairing the accurate evaluation on CCTA, was excluded.

DSCT-Calcium Scoring and Coronary CT Angiography

All CT examinations were performed on a DSCT scanner (Somatom Definition, Siemens Medical Solutions, Forchheim, Germany). The patients were centrally placed in the scanner to ensure that the entire heart was covered by the smaller field-of-view of the second tube detector array. No beta-blockers were administered prior to scanning. Non-enhanced DSCT for calcium scoring was performed from 1 cm below the level of the tracheal bifurcation to the diaphragm in the cranio-caudal di-

rection. Non-contrast CT scans were obtained with a collimation of 0.6-mm thickness; rotation time of 0.33 msec; tube voltage of 100 or 120 kV; tube current of 100 mAs per rotation on both tubes; and pitch of 0.3-0.39 (depending on heart rate). The scan time was 5.7-8.1 seconds for a single breath hold.

CCTA was used with a tri-phasic injection protocol. Bolus tracking was performed in the ascending aorta, with an additional scan delay of 7 seconds used for timing. In the first phase, a 50-60 mL bolus of 370 mg/mL iopromide contrast media (Ultravist; Schering, Erlangen, Germany) was injected into an antecubital vein at a flow rate of 4-5 mL/s. In the second phase, 50 mL of mixed contrast agent and saline (7 : 3 or 6 : 4) was injected at the same flow rate, followed by a 40 mL saline chasing bolus administered using an autoinjector (Stellant; Medrad, Warrendale, PA, USA). The patient held his/her breath at mild inspiration. The mean scan time was 10 seconds (range 7-12 seconds). The tube voltage was 100-120 kVp for both tubes. Height and weight of all patients were measured and BMI was calculated. If BMI was standard or lower, 100 kVp was used, and if BMI was above standard, 120 kVp was used. The current was between 30% and 80% of the cardiac cycle if the heart rate was less than 90 beats per minute (bpm). The current was full between 10% and 100% of the cardiac cycle if the heart rate was more than 90 bpm, because good images could be obtained at the systolic phase for the majority of patients with a fast heart beat. The gantry rotation time was 0.33 seconds, and the pitch was 0.3-0.4, depending on heart rate. Using a medium soft-tissue convolution kernel and a mono-segment reconstruction algorithm that uses data from quarter rotations of both detectors, 1-mm axial images were reconstructed for the entire cardiac cycle, with reconstruction intervals obtained in 10% steps. ECG-pulsing was applied for radiation dose reduction in all patients.

A retrospective gating technique was used to synchronize the data reconstruction with the ECG signal. A mono-segment reconstruction algorithm that uses the data from 1/4 rotation of both detectors was used for image reconstruction. In each patient, images were reconstructed at 70-75% of the RR interval for diastolic images and 30-35% of the RR interval for systolic images. If considered necessary, additional images were reconstructed in 5% steps of the RR interval.

For CCTA, images were reconstructed from the contrast-en-

hanced DSCT scans with a slice thickness of 0.75 mm, a reconstruction increment of 0.5 mm, and using a medium soft-tissue convolution kernel (B26f). Depending on each patient's anatomy, the reconstructed field-of-view (FOV) was adjusted to exactly encompass the heart (mean FOV, 167 ± 19 mm; range, 131-187 mm; image matrix, 512×512 pixels). After the patient was removed and the ECG information was obtained, all reconstructed images were transferred to a dedicated workstation (Wizard, Siemens Medical Solutions, Forchheim, Germany) equipped with dedicated cardiac post-processing software (Syngo Circulation, Siemens Medical Solutions, Forchheim, Germany).

Data Analyses

For analysis of CCTA data, the coronary arteries were segmented according to the guidelines of the American Heart Association (10) as follows. All segments with a diameter of at least 1.5 mm at the origin were included. Image quality of a stenotic coronary segment was assessed semiquantitatively on a four-point ranking scale by one radiologist as follows: 1, excellent (no artifacts); 2, good (minor artifacts); 3, adequate (moderate artifacts, diagnostic), and 4, not assessable (severe artifacts impairing accurate evaluation). The mean Agatston score was calculated for each patient using a semi-automated software (Syngo Calcium Scoring, Siemens Medical Solutions, Forchheim, Germany). Diameter measurements were performed using an electronic caliper by one radiologist. All reconstructed images were simultaneously evaluated by two radiologists using axial source images, multi-planar reformations, maximum intensity projections, and volume rendering on a per-segment basis. All of the coronary artery segments were assessed for the presence of hemodynamically significant stenoses. Significant stenosis was defined as narrowing of the coronary luminal diameter that exceeded 50%. The diameter of the stenotic vessel diameters was measured perpendicular to the vessel course. For the initial measurement, the narrowest stenotic area at the same site in systolic and end-diastolic phase was selected. The diameter was measured three times continuously to get an average value at the most stenotic area and the mean value of the stenotic vessel's diameter was calculated. The percentage of diameter change in stenotic coronary artery was calculated as: $[(\text{diameter of stenotic portion in diastole} - \text{diameter of stenotic portion in systole}) \div \text{diameter of stenotic portion in diastole}] \times 100\%$. In a sub-analysis,

patients were divided into cardiac contraction of the end-diastolic and systolic phase as well as for mean heart rate of ≤ 80 bpm and > 80 bpm.

Invasive Coronary Angiography (ICA)

ICA was performed according to standard techniques, and multiple views were stored on a CD-ROM. One experienced cardiologist who was blinded to the results of the CCTA evaluated the angiograms. Coronary artery segments were defined according to the guidelines described above (9). Each vessel segment was scored as being significantly stenosed, which was defined as a diameter reduction of $> 50\%$. A coronary artery analysis was performed in all vessels with a luminal diameter of at least 1.5 mm, excluding vessels distal to complete occlusions. The narrowest stenotic area at the end-diastolic phase was selected. The diameter was measured three times continuously to get an average value at the most stenotic area and the mean value of the stenotic vessel's diameter was calculated (10).

Statistical Analyses

Statistical analyses were performed using commercially available software (SPSS 12.0, SPSS, Chicago, IL, USA). We evaluated the percent difference in the stenotic coronary artery between systolic and end-diastolic phases with respect to heart rate or calcium score and correlated the diagnostic accuracy with heart rate in the end-diastolic phase using a linear regression analysis. The sensitivity, specificity, positive predictive value (PPV), and negative predictive value (NPV), and accuracy on a per-vessel basis of CCTA in diastole in terms of the heart rate or Agatston score were calculated using the Chi-square test for contingency. The ICA findings were considered the standard of reference. A correlation between the degree of coronary artery stenosis on DSCT and ICA was evaluated by Pearson's correlation analysis depending on overall end-diastolic phase, heart rate ≤ 80 bpm, and heart rate > 80 bpm.

RESULTS

The clinical characteristics of the enrolled patients are summarized in Table 1. ICA demonstrated coronary artery stenosis in all patients. Among all of the coronary arteries, 51 vessels (62.9%) had stenoses. Among the vessels with a stenosis, 23

(45.0%) were significantly stenosed, which is defined as having a diameter reduction $\geq 50\%$.

Image quality of stenotic coronary segments, assessed semi-quantitatively, was excellent (mean score, 1.2 ± 0.6). The mean difference in the stenotic coronary artery diameter between systole and end-diastole according to heart rate was 12.9% for < 60 bpm, 11.3% for 60-69 bpm, 10.0% for 70-79 bpm, 20.0% for 80-89 bpm, 13.0% for 90-99 bpm, and 6.7% for ≥ 100 bpm. The stenotic site of the coronary arteries in the systolic phase was narrower than in the diastolic phase. However, there was no statistically significant correlation between the diameter change for the stenotic portion of coronary artery and heart rate ($r = -0.198, p = 0.760$) (Fig. 1).

The overall sensitivity, specificity, PPV, NPV, and accuracy on a per-vessel basis of CCTA determined during diastole were 100%, 84%, 87%, 100%, and 92%, respectively. For a heart rate ≤ 80 bpm ($n = 26, 50.9\%$), the sensitivity, specificity, PPV, NPV, and accuracy of CCTA determined during diastole were 100%, 88%, 83%, 100%, and 92%, respectively. For a heart rate > 80 bpm ($n = 25, 49.1\%$), these values were 100%, 78%, 89%, 100%, and 92%, respectively.

The correlation between the use of ICA and DSCT was 0.805

($p < 0.001$) determined during the diastolic phase. The correlation between the use of ICA and DSCT was 0.867 ($p < 0.001$) for a heart rate ≤ 80 bpm, and 0.817 ($p < 0.001$) and for a heart rate > 80 bpm, both determined during the diastolic phase (Fig. 2).

The mean Agatston score was 238.5 ± 196.2 and the mean difference in the stenotic coronary artery diameter between systole and end-diastole according to calcium score was 8.3% for less than 100, 12.4% for 100-400, and 20% for ≥ 400 (Figs. 3-5). There was a significant correlation between the diameter change of the stenotic portion of the coronary artery and Agatston score ($r = 0.942, p = 0.004$).

In patients with calcium scores < 100 , sensitivity, specificity, PPV, NPV, and accuracy on a per-vessel basis were 97.3%, 97.9%, 88.8%, 99.0%, and 97.6%, respectively. These measurements were 96.6%, 95.3%, 82.6%, 95.2%, and 94.1%, respectively in patients with calcium scores between 100 and 400; and 90.3%, 91.2%, 81.7%, 90.7%, and 88.2%, respectively in patients with calcium scores of > 400 .

DISCUSSION

High calcium burdens make it difficult to diagnose the coro-

Table 1. Patients Characteristics

No. of patients	27
Age (years)	63.1 ± 8.4
Gender (M/F)	13/14
Smoking	9 (33.3)
Hypertension	24 (88.9)
Diabetes	4 (14.8)
Hyperlipidemia	20 (74.1)
Mean body mass index (kg/m^3)	24.5 ± 2.7
Mean heart rate during scan (beats/mean)	
HR ≤ 80	17 (62.9)
HR > 80	10 (37.1)
Mean Agatston score	
0-100	15 (55.6)
101-400	7 (25.9)
> 400	5 (18.5)
No. of diseased vessel	
Non-significant CAD	10 (37.1)
Single vessel	12 (44.4)
Two vessel	4 (14.8)
Three vessel	1 (3.7)

Data in parentheses are percentages.

Note.—CAD = coronary artery disease, HR = heart rate

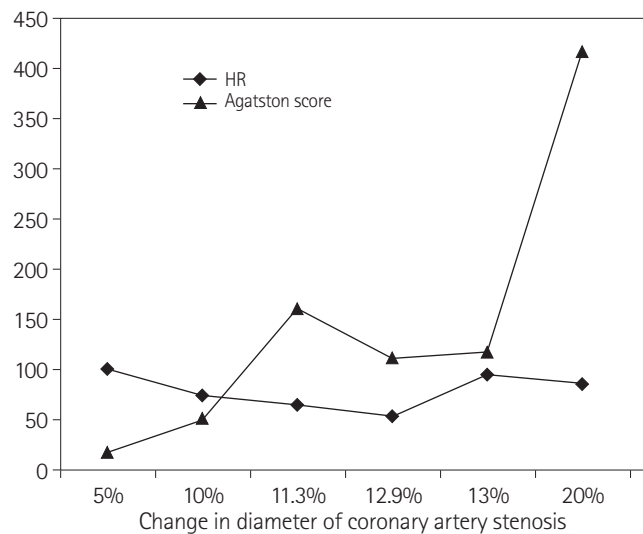


Fig. 1. This graph shows the mean difference in the stenotic coronary artery diameter between the systole and end-diastole according to heart rate. There was no statistically significant correlation between the change in diameter of coronary artery stenosis and heart rate ($r = -0.198, p = 0.760$). However, the change in diameter of coronary artery stenosis and Agatston score were correlated ($r = 0.942, p = 0.004$).

Note.—HR = heart rate

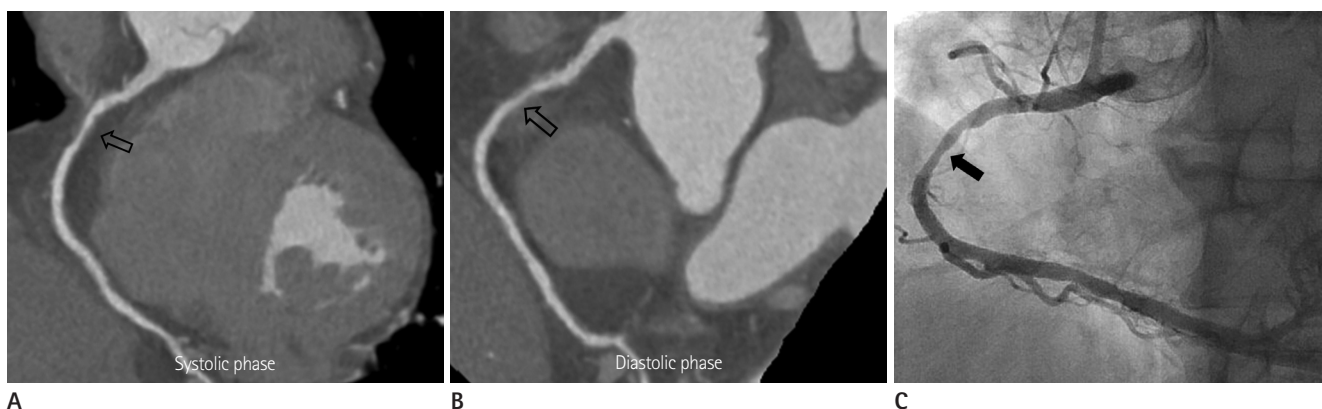


Fig. 2. A 65-year-old man diagnosed with unstable angina (heart rate of 62 bpm and Agatston score of 40).
A, B. On coronary CT angiography, there is diffuse, moderate stenosis with a plaque in the diastolic phase and diffuse, severe stenosis with a plaque at the middle RCA in the systolic phase. The difference in stenotic coronary vessel diameter between the systolic and diastolic phase was 5%.
C. Invasive coronary angiography shows diffuse, moderate stenosis (50%) at the middle RCA.
 Note.—RCA = right coronary artery

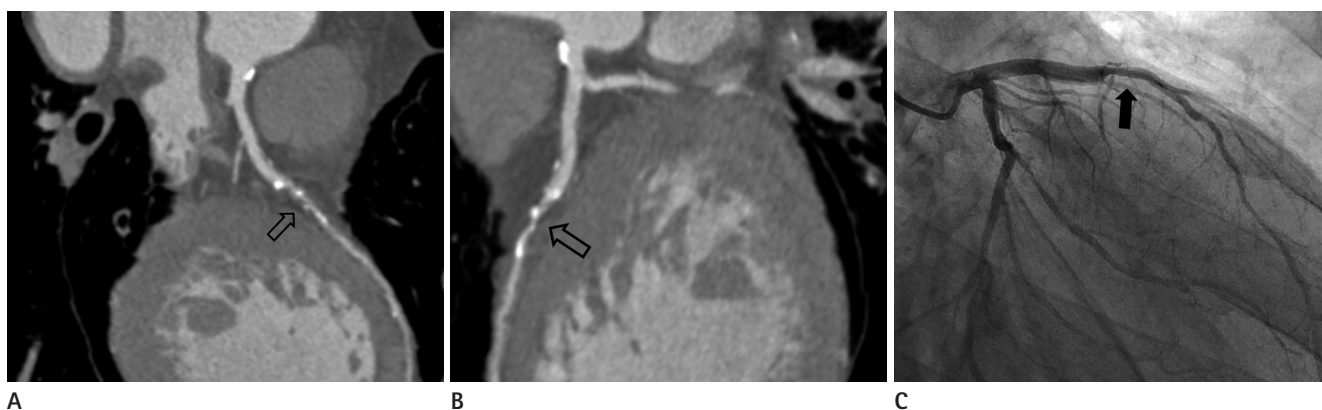


Fig. 3. A 69-year-old man who had chest pain (heart rate of 65 bpm and Agatston score of 345).
A, B. On coronary CT angiography, there is diffuse, severe stenosis with mixed plaque at the proximal LAD in the diastolic phase and had tight stenosis in the systolic phase. The difference in the stenotic coronary vessel diameter between systolic and diastolic phase was 15%.
C. Invasive coronary angiography shows diffuse, moderate stenosis (70-80%) at the proximal LAD.
 Note.—LAD = left anterior descending artery

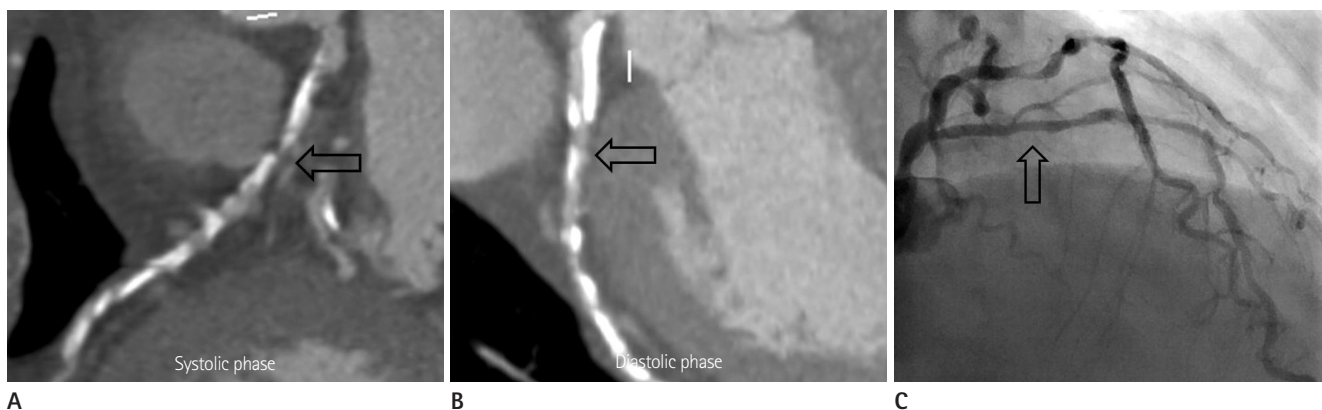

Fig. 4. A 76-year-old woman diagnosed with stable angina (heart rate of 69 bpm and Agatston score of 2429.7).
A, B. On coronary CT angiography, there is diffuse, moderate to severe stenosis with calcified plaque at the proximal LCX in the diastolic phase and had severe to tight stenosis in the systolic phase. The difference in the stenotic coronary vessel diameter between systolic and diastolic phase was 52%.
C. Invasive coronary angiography shows diffuse, severe stenosis (70%) at the proximal LCX.
 Note.—LCX = left circumflex artery

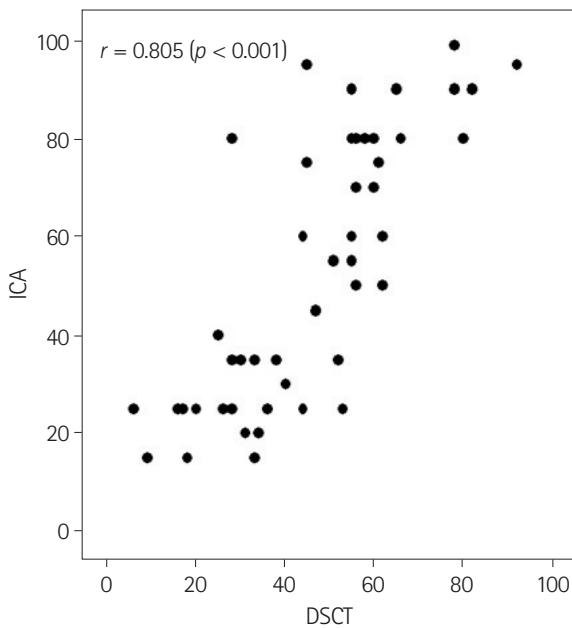


Fig. 5. This graph shows the correlation between the observers of ICA and DSCT for the evaluation of coronary artery stenosis during the diastolic phase.

Note.—DSCT = dual source computed tomography, ICA = invasive coronary angiography

nary artery stenosis accurately and which significantly reduce the sensitivity and specificity of CCTA using DSCT (4, 10). Meng et al. (10) reported that on a per-artery basis of CCTA for coronary artery stenosis in diastolic phase, a specificity of 99%, PPV of 96%, and accuracy of 98% was achieved in the low calcium group, and reduced to 79%, 69%, and 85%, respectively in the high calcium group. In our study, we found that the mean difference in the stenotic coronary artery diameter between systole and end-diastole was 8.3% for an Agatston score < 100, but increased approximately three-fold when the mean Agatston score was > 400. According to these results, we expect that the diagnostic accuracy of coronary artery stenosis could be possible with the best image in the systolic phase if the Agatston score is less than 100, because the mean difference in the stenotic coronary artery diameter between end-diastole and systole is low. However, if the Agatston score is > 400, on the basis of our study, we suggest that coronary artery stenosis in the systolic phase could be overestimated compared with the diastolic phase.

Many studies have reported the technical capacity of DSCT to provide diagnostic quality images of coronary arteries in patients regardless of heart rate (1-4). Image reconstruction in

CCTA is typically performed in mid to late diastole (6, 11). Because the diastolic phase is relatively long in patients with low heart rates, we usually select the diastolic phase for image reconstruction in such cases. However, the diastolic phase dramatically shortens with increasing heart rates, and even ceases to exist at heart rates > 80 bpm. In contrast to the duration of diastole, the duration of systole is less affected by changes in heart rate (11), thus explaining why image quality in systolic reconstructions did not deteriorate as much with increasing heart rate as observed in diastolic reconstructions. The transition of the optimal reconstruction interval from the diastole to systole in this study was around 80 bpm, a finding that is supported by an early report by Johnson et al. (1) on DSCT of the coronary arteries. In our study, the diagnostic accuracy of the stenotic coronary artery was always lower in the systolic phase than the diastolic phase. Hence, although we could obtain the best image of the stenotic coronary artery in the systolic phase, this might not provide the best diagnostic accuracy.

Generally, stenosis less than 50% are revascularized only in the presence of clinical symptoms, whereas stenosis greater than 70% are typically treated, even in the absence of symptoms (12). To understand the change in stenotic vessel diameter between the systolic and diastolic phase on CCTA, it is sometimes helpful to determine the severity of coronary artery stenosis based on ICA. ICA is the standard for the analysis of the severity of coronary artery stenosis in the diastolic phase. In clinical practice, when we obtain a best image in the systolic phase, we should compare the severity of coronary artery stenosis in the systolic phase on CCTA with the diastolic phase on ICA. In our study, the mean difference in stenotic coronary vessel diameter between systolic and diastolic phase was on average 12%, although this varied according to Agatston score. Herzog et al. (12) reported that marked calcifications did not necessarily compromise image quality but were causes of overestimation of moderate stenosis in the diastolic phase, hence the specificity decreased. Consequently, because stenotic coronary vessels with marked calcification in the systolic phase could be overestimated based on ICA, radiologists and cardiologists should be cautious when diagnosing significant stenosis in such vessels.

A limitation of our study was the small number of patients ($n = 27$) included who had stenotic coronary vessels. Accordingly, a further study with a large number of patients is needed. In

addition, although we measured the stenotic coronary vessel diameter in the systolic and diastolic phases on CCTA, we measured the stenotic coronary vessel diameter only in the end-diastolic phase on ICA. We recommend an additional study in which the change in stenotic coronary vessel diameter in the systolic and diastolic phase on CCTA and ICA will be measured simultaneously to obtain the standard reference for systolic phase on CCTA. Patients with irregular heart rates were excluded, especially on atrial fibrillation or premature ventricular contraction because image quality is related to heart rate variability.

In conclusion, the calcium burden in stenotic coronary vessels might markedly affect the change in vessel diameter according to the cardiac cycle. In particular, stenotic coronary vessels with a high calcium burden in the systolic phase could lead to the overestimation of the severity of coronary artery stenosis based on ICA. Therefore, a radiologist should be cautious when interpreting the severity of coronary artery stenosis on CCTA when they obtain the best image of the coronary artery in the systolic phase only along with a high Agatston score.

REFERENCES

1. Johnson TR, Nikolaou K, Wintersperger BJ, Leber AW, von Ziegler F, Rist C, et al. Dual-source CT cardiac imaging: initial experience. *Eur Radiol* 2006;16:1409-1415
2. Scheffel H, Alkadhi H, Plass A, Vachenaue R, Desbiolles L, Gaemperli O, et al. Accuracy of dual-source CT coronary angiography: first experience in a high pre-test probability population without heart rate control. *Eur Radiol* 2006;16:2739-2747
3. Achenbach S, Ropers D, Kuettner A, Flohr T, Ohnesorge B, Bruder H, et al. Contrast-enhanced coronary artery visualization by dual-source computed tomography--initial experience. *Eur J Radiol* 2006;57:331-335
4. Zhang LJ, Wu SY, Wang J, Lu Y, Zhang ZL, Jiang SS, et al. Diagnostic accuracy of dual-source CT coronary angiography: the effect of average heart rate, heart rate variability, and calcium score in a clinical perspective. *Acta Radiol* 2010;51:727-740
5. Weustink AC, Neefjes LA, Kyrzopoulos S, van Straten M, Neoh Eu R, Meijboom WB, et al. Impact of heart rate frequency and variability on radiation exposure, image quality, and diagnostic performance in dual-source spiral CT coronary angiography. *Radiology* 2009;253:672-680
6. Leschka S, Husmann L, Desbiolles LM, Gaemperli O, Schepis T, Koepfli P, et al. Optimal image reconstruction intervals for non-invasive coronary angiography with 64-slice CT. *Eur Radiol* 2006;16:1964-1972
7. Seifarth H, Wienbeck S, Püsken M, Juergens KU, Maintz D, Vahlhaus C, et al. Optimal systolic and diastolic reconstruction windows for coronary CT angiography using dual-source CT. *AJR Am J Roentgenol* 2007;189:1317-1323
8. Matt D, Scheffel H, Leschka S, Flohr TG, Marincek B, Kaufmann PA, et al. Dual-source CT coronary angiography: image quality, mean heart rate, and heart rate variability. *AJR Am J Roentgenol* 2007;189:567-573
9. Austen WG, Edwards JE, Frye RL, Gensini GG, Gott VL, Griffith LS, et al. A reporting system on patients evaluated for coronary artery disease. Report of the Ad Hoc Committee for Grading of Coronary Artery Disease, Council on Cardiovascular Surgery, American Heart Association. *Circulation* 1975;51:5-40
10. Meng L, Cui L, Cheng Y, Wu X, Tang Y, Wang Y, et al. Effect of heart rate and coronary calcification on the diagnostic accuracy of the dual-source CT coronary angiography in patients with suspected coronary artery disease. *Korean J Radiol* 2009;10:347-354
11. Chung CS, Karamanoglu M, Kovács SJ. Duration of diastole and its phases as a function of heart rate during supine bicycle exercise. *Am J Physiol Heart Circ Physiol* 2004;287:H2003-H2008
12. Herzog C, Zwerner PL, Doll JR, Nielsen CD, Nguyen SA, Savino G, et al. Significant coronary artery stenosis: comparison on per-patient and per-vessel or per-segment basis at 64-section CT angiography. *Radiology* 2007;244:112-120

심장박동수 또는 석회수치에 따른 수축기와 이완기 말기에서 협착된 관상동맥의 직경 변화 측정¹

이현경¹ · 진공용¹ · 박재근¹ · 한영민¹ · 이영선¹ · 권근상² · 김성수³

목적: CT 관상동맥조영술을 이용하여 좁아진 관상동맥의 수축기와 이완기 말기에서의 직경 변화를 측정하고 심장박동수 또는 석회수치와의 관련성에 대해서 알아 보았다.

대상과 방법: 관상동맥협착이 있는 환자 중 CT 관상동맥조영술과 침습적 관상동맥조영술을 모두 시행한 27명의 환자를 대상으로 하였다. CT 관상동맥조영술에서 협착된 동맥의 수축기와 이완 말기에서의 관상동맥 직경의 백분율 변화를 측정한 후 심장박동수 또는 Agatston 점수와의 관련성을 단순선형회귀분석을 이용하여 조사하였다.

결과: 수축기와 이완 말기에서의 좁아진 관상동맥 직경의 변화는 분당 심장박동수 50~59회에서 12.9%, 60~69회에서 11.3%, 70~79회에서 10%, 80~89회에서 20%, 90~99회에서 13%, 100~109회에서 6.7%의 차이를 보였다. 그러나 심장박동수와 관상동맥 직경 변화의 차이는 통계적으로 유의하지 않았다($p = 0.760$). Agatston 점수에 따른 관상동맥 직경 변화의 차이는 100 미만에서 8.3%, 100~400에서 12.4%, 400 이상에서 20%를 보였고, Agatston 점수와 관상동맥 직경 변화의 차이는 통계적으로 유의하였다($p = 0.004$).

결론: 수축기와 이완 말기에서 좁아진 관상동맥 직경 변화는 Agatston 점수에 영향을 받는다.

전북대학교 의학전문대학원 전북대학교병원 임상의학연구소 심혈관연구소 ¹영상의학과학교실, ²예방의학과학교실,
³충남대학교 의학전문대학원 충남대학교병원 영상의학과학교실