

## Peripancreatic Lymphocele after Distal Gastrectomy

## 위절제술 후에 발생한 복강내 림프류

Eun Joo Lee, MD, Mi Jeong Kim, MD

Department of Diagnostic Radiology, Keimyung University School of Medicine, Daegu, Korea

Lymphocele occurs as a result of persistent leakage of disrupted lymphatics. Peripancreatic lymphocele is quite rare and has not yet been described in the literature. Here we report on a case of peripancreatic lymphocele in which a cystic mass was observed with a fat attenuating component using computed tomography after gastrectomy.

## Index terms

Cyst, Percutaneous Drainage  
Lymphatic System, Interventional Procedure  
Lymphocele

Received October 11, 2011; Accepted November 8, 2011

Corresponding author: Mi Jeong Kim, MD  
Department of Diagnostic Radiology, Keimyung  
University School of Medicine, 56 Dalseong-ro, Jung-gu,  
Daegu 700-712, Korea.  
Tel. 82-53-250-7767 Fax. 82-53-250-7766  
E-mail: kmj1971@dsmc.or.kr

Copyrights © 2012 The Korean Society of Radiology

## INTRODUCTION

Lymphocele is defined as a collection of lymphatic fluid within a nonepithelialized cavity, which occurs as a result of persistent leakage of disrupted lymphatics (1). As a surgical complication, lymphoceles usually develop after pelvic lymphadenectomy performed for staging of urologic or gynecologic malignancies and renal transplantation. Less commonly, lymphoceles may develop after vascular and spinal surgery. Theoretically, any kind of surgery leading to lymphatic injury can cause lymphoceles (2).

We recently encountered a patient with a cystic collection adjacent to the pancreas that had indicative features upon CT scan. Only two other cases of peripancreatic lymphocele have been reported (3, 4) and no case after gastrectomy has been reported in the literature. In this article, we describe the unusual occurrence of a peripancreatic lymphocele that had evident features after distal gastrectomy, as well as report on the management of this lesion by sclerotherapy with ethanol.

## CASE REPORT

A 75-year-old female with stomach cancer underwent distal gastrectomy and gastroduodenostomy. Perigastric lymphade-

nectomy was performed during the procedure. A six month postoperative routine follow-up abdominal CT scan with contrast revealed a well-defined, 13-cm diameter, low density fluid collection in the region of the tail of the pancreas, compressing the spleen posteriorly, and the cystic mass had a nonenhancing thin wall as well as a small amount of very low density component that measured -50 HU, indicative of fat in the nondependent portion (Fig. 1A).

The serum amylase and lipase levels were found to be normal. Under ultrasound guidance, percutaneous drainage was performed. A total 680 mL of milky fluid was yielded (Fig. 1B), and cystogram revealed a lobulating cavity with no communication with the pancreatic duct, adjacent bowel, vessels or thoracic duct (Fig. 1C). The fluid analysis revealed an amylase concentration of 5 IU/L, triglyceride of 3211 mg/dL, total protein of 2750 mg/dL, and a white cell count of 12/mm<sup>3</sup> (85% lymphocytes). Gram stain and bacteriologic cultures on initial aspirates demonstrated no bacterial growth. The sclerotherapy using absolute ethanol was performed, where a 6 F pigtail drainage catheter was placed into the cavity under fluoroscopic guidance. After excluding the probability of extravasation by cavito-gram, absolute ethanol 100 mL was instilled and left in the cavity for 20 min. All of the fluid was completely drained, with

2 additional sessions that were done at 48 hours intervals. The cystogram obtained after 8 days showed almost complete obliteration of the cavity (Fig. 1D), and the catheter was withdrawn without any complication.

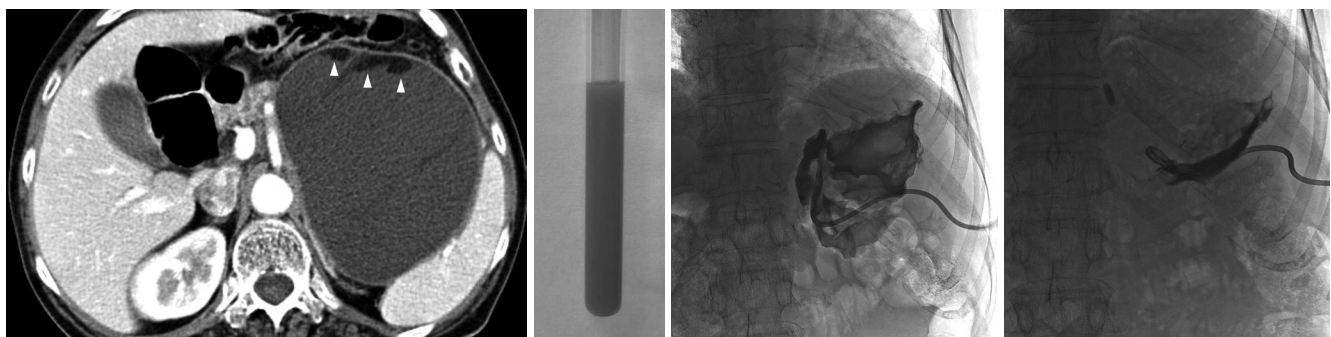
## DISCUSSION

Lymphatics from the lower extremities and gastrointestinal tract flow upward to the cisterna chyli, a 5-7 cm long saccular dilatation of the lymphatic system, located anterior to the first or second lumbar vertebrae. The cisterna chyli becomes the thoracic duct and ascends through the esophageal hiatus of the diaphragm, along the anterior surface of the fifth thoracic vertebral column. Then, the thoracic duct crosses from right to left, and drains into one of the major veins at the junction of the left subclavian and internal jugular veins. The main function of this lymphatic system is the transportation of the fat absorbed from the gastrointestinal tract. About 60 to 70% of absorbed fat is transported through the lymphatics rather than the capillary vessels. Because of gastrointestinal lymphatics, lymph above the cisterna chyli is rich in chylomicron and has a turbid, creamy white color, and lymph below the cisterna chyli is of a serous nature, clear yellow in color and contains a lower triglyceride level (5-7). If this system is disrupted, lymph flows and accumulates in anatomic compartments, walled off by adjacent organs. As time progresses, lymph fluid is loculated by the fibrotic wall without epithelial linings like the pancreatic pseudocyst. Disrupted lymphatics can remain open up to 48

hours after injury due to low concentrations of clotting factors and lack of thrombocytes and smooth muscle cells in the wall of lymphatics (8, 9).

Lymphocele frequently occurs after pelvic lymphadenectomy performed for staging of urologic or gynecologic malignancies and renal transplantation, that is, below the cisterna chyli. Thus, we usually encounter lymphocele of a serous nature and with suitable radiologic findings; on ultrasound lymphocele appears as an anechoic cystic structure in a characteristic location adjacent to vessels in the paraaortic region or surgical clips and may contain thin septations and debris. CT scan also reveals a hypodense cystic lesion in non-complicated cases and thick irregular enhancing wall in infected or complicated cases. On MR imaging of pelvic lymphocele appears as a lobulated cystic lesion with high signal intensity on T2-weighted images with imperceptible wall and negligible wall enhancement on contrast-enhanced T1-weighted images (2).

In our case, CT scan revealed a hypodense cystic mass in the region of the pancreatic tail after distal gastrectomy and perigastric lymphadenectomy. In view of its location, our first assumption was that the lesion was a pancreatic pseudocyst that occurred as a result of upper abdominal surgery. But, the patient had no past history of pancreatitis, no corresponding imaging findings to pancreatitis and had normal range of serum amylase. Furthermore, the hypodense cystic mass contained peripheral very low density materials, which is indicative of fat. The mass was so pathognomonic that we diagnosed the cystic mass as a lymphocele in spite of the rarity of this type of peri-



**Fig. 1.** A 75-year-old woman underwent gastrectomy for gastric cancer.  
**A.** Contrast-enhanced CT scan shows a well-defined, hypodense mass with thin wall and a small amount of very low density component that measured -50 HU (arrowheads).  
**B.** Under ultrasound guidance, turbid and milky fluid was aspirated from the hypodense mass.  
**C.** A cystogram revealed a lobulating cavity with no communication to the pancreatic duct, adjacent bowel, vessels, or the thoracic duct.  
**D.** A cystogram obtained 8 days after catheter drainage with sclerotherapy shows almost complete obliteration of the cavity.

pancreatic lesion. The fatty materials indicated the collection is chylous, specifically the lymph above the cisterna chyli. An unusually located dermoid cyst also might be considered, but the hypodense cystic mass did not exist prior to 6 months.

The aspiration of fluid and biochemical analysis of aspirated fluid confirmed the diagnosis of lymphocele. The fluid appeared turbid and milky, and predominantly consisted of lymphocytes, also contained high triglyceride levels and low total protein levels corresponding to chylous lymphatics collection. Amylase concentration from the aspirated fluid was low, which is always elevated in pseudocysts. Although there is no single diagnostic test for lymph fluid, a comprehensive understanding of gross appearance of fluid and several laboratory studies render the diagnosis.

Asymptomatic lymphocele does not require treatment. In many cases, it spontaneously resolves over time. On the other hand, large lymphoceles can cause clinical symptoms. For example, compression of adjacent anatomic structures iliac vessels, bladder, ureter, pelvic nerves, and rectosigmoid colon can cause leg swelling, thromboembolism, genital edema, bladder dysfunction, hydronephrosis, pelvic pain and constipation. Treatment decisions depend on the severity of the clinical situation including but not limited to secondary infection, symptoms, growing or persistence in size (10).

In the past, open or laparoscopic surgery had been performed as a treatment method. However, in any kind of surgery, there are associated risks and laparoscopic surgery is not suitable for all lymphoceles. Therefore, percutaneous catheter drainage with sclerosing agents (ethanol, bleomycin, doxycycline, or povidone-iodine) is considered as a first-line treatment for lymphoceles with a high success rate, in part due to its safe nature (2).

The formation of a lymphocele after distal gastrectomy is a very rare complication. But, the lymphocele in the upper abdomen, specifically above the cisternal chili, has distinguishable characteristics of a cystic mass containing very low density com-

ponent indicative of fat from other cystic lesions found by imaging analysis, unlike lymphocele in the pelvic cavity.

## REFERENCES

1. White M, Mueller PR, Ferrucci JT Jr, Butch RJ, Simeone JF, Neff CC, et al. Percutaneous drainage of postoperative abdominal and pelvic lymphoceles. *AJR Am J Roentgenol* 1985;145:1065-1069
2. Karcaaltincaba M, Akhan O. Radiologic imaging and percutaneous treatment of pelvic lymphocele. *Eur J Radiol* 2005;55:340-354
3. Chen YH, vanSonnenberg E, Urman R, Silverman SG. Lymphocele mimicking a pancreatic pseudocyst: imaging characteristics and percutaneous management. *Cardiovasc Intervent Radiol* 2003;26:564-566
4. Lim WC, Leblanc JK, Dewitt J. EUS-guided FNA of a peripancreatic lymphocele. *Gastrointest Endosc* 2005;62:459-462
5. Levi AD. Treatment of a retroperitoneal lymphocele after lumbar fusion surgery with intralesional povidone iodine: technical case report. *Neurosurgery* 1999;45:658-660; discussion 660-661
6. Propst-Proctor SL, Rinsky LA, Bleck EE. The cisterna chyli in orthopaedic surgery. *Spine (Phila Pa 1976)* 1983;8:787-792
7. Shen YS, Cheung CY, Nilsen PT. Chylous leakage after arthrodesis using the anterior approach to the spine. Report of two cases. *J Bone Joint Surg Am* 1989;71:1250-1251
8. Glass LL, Cockett AT. Lymphoceles: diagnosis and management in urologic patients. *Urology* 1998;51:135-140
9. Leitner DW, Sherwood RC. Inguinal lymphocele as a complication of thighplasty. *Plast Reconstr Surg* 1983;72:878-881
10. vanSonnenberg E, Wittich GR, Casola G, Wing VW, Halasz NA, Lee AS, et al. Lymphoceles: imaging characteristics and percutaneous management. *Radiology* 1986;161:593-596

## 위절제술 후에 발생한 복강내 림프류

이은주 · 김미정

림프류(lymphocele)는 림프관 손상으로 지속적인 림프액의 누출로 인해 생기는 낭종이다. 췌장 주위에 발생한 림프류는 매우 드물며 위절제술 후에 발생한 림프류에 대한 보고는 없었다. 저자들은 위절제술 후 전산화단층촬영(CT)에서 췌장 주위에 지방 음영을 포함한 낭성종괴의 형태로 나타난 림프류를 경험하였기에 보고하고자 한다.

계명대학교 의과대학 영상의학과학교실