

Upper Extremity Hemolymphangiomas in Children: A Case Report¹

소아의 상지에서 발생한 혈관림프관종: 증례 보고 1예¹

Hyo Jin Kang, MD¹, Yong Hoon Kim, MD¹, Yoon Joon Hwang, MD¹, Su Young Kim, MD¹,
Han Seong Kim, MD²

Departments of ¹Radiology, ²Pathology, Ilsan Paik Hospital, Inje University College of Medicine, Goyang, Korea

Hemolymphangiomas are rare benign soft tissue tumors that arise from congenital malformations of the vascular system. The malformations are usually diagnosed at birth or early in childhood and cases in the extremities have been scarcely reported. We present a very rare case of hemolymphangioma of the right upper extremity in a 7-year-old male. The diagnosis was made by plain radiography and magnetic resonance imaging and finally confirmed by histopathology of the resected specimen. The hemolymphangioma showed a well-defined soft tissue mass with a phlebolith on plain radiography, and a multilocular cystic mass with peripheral and septal enhancement on magnetic resonance imaging.

Index terms

Hemolymphangioma
Lymphangioma
Vascular Malformations
Upper Extremity
Magnetic Resonance Imaging

Received February 8, 2012; Accepted April 4, 2012

Corresponding author: Yong Hoon Kim, MD
Department of Radiology, Ilsan Paik Hospital, Inje
University College of Medicine, 170 Juhwa-ro,
Ilsanseo-gu, Goyang 411-706, Korea.
Tel. 82-31-910-7395 Fax. 82-31-910-7369
E-mail: kyh@paik.ac.kr

This work was supported by Grant from Inje University,
2007.

Copyrights © 2012 The Korean Society of Radiology

INTRODUCTION

Lymphangiomas are a heterogeneous group of vascular malformations of the lymphatic channels and are composed of cystically dilated lymphatics. According to Landing and Farber, these benign malformations are classified into four subtypes: capillary lymphangiomas, cavernous lymphangiomas, cystic lymphangiomas (hygromas) and hemolymphangiomas (combination of hemangiomas and lymphangiomas).

Hemolymphangiomas are extremely rare and in most cases, detected at birth or within 2 years of life. Lymphangiomas are rare in the extremities, and to the best of our knowledge, only four cases affecting the extremities have been reported in the literature to date (1-3). Prenatal ultrasonography can detect relatively large lesions as early as the second trimester (4).

We report a case of a hemolymphangioma arising in the upper extremity, and we also describe the radiological findings of

this disease and discuss the relevant literature review.

CASE REPORT

A 7-year-old male patient presented to our orthopedic examination room with a palpable, painless mass on the anteromedial side of his right elbow. Clinically, the lesion was found to be oval in shape, soft, compressible and painless. There was no history of trauma, previous infection or constitutional symptoms.

Anteroposterior and lateral plain radiographs demonstrated a well-defined soft tissue mass with focal calcification regarded as a phlebolith (Fig. 1). The lesion was confined to subcutaneous tissue without signs of bony erosion.

Magnetic resonance imaging of the affected area was performed pre-operatively in order to characterize the tumor, establish the extent of the tumor, and define the relationship to the

surrounding structures. The mass was seen to be a well circumscribed, lobulated, multilocular cystic mass with a maximum diameter of 19 mm, localized in the prefascial subcutaneous tissues, and anteromedial aspect of the right medial epicondyle of humerus (Fig. 2). The mass had an intermediate to slightly high signal intensity on T1-weighted sequences and hyperintense signal intensity with internal thin septae on T2-weighted sequences. Focal dot-like dark signal intensity was noted within the mass for all sequences that corresponded to the phlebolith

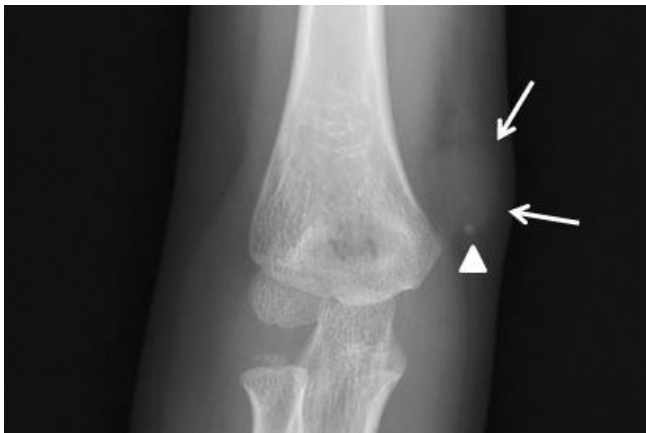

Fig. 1. Anteroposterior plain radiographic finding for case. Anteroposterior plain radiograph of the right elbow shows a phlebolith (arrowhead) within the soft tissue mass (arrows).

on plain radiographs. Peripheral and septal enhancement of the tumor was observed after administration of gadolinium. The lesion had fine adhesions to the surrounding tissue, and the cortex of the bone was found intact. The imaging findings were suspicious for the diagnosis of a hemangioma, cystic lymphangioma, unusual peripheral nerve sheath tumor or Kimura's disease.

An excisional biopsy of the lesion was performed to release the specimen from the adhesion to subcutaneous tissue. A histological examination described the resected tumor as a fibrolipomatous mass containing lymphatic and blood vessels with the stroma being infiltrated by lymphocytes (Fig. 3). The histopathological diagnosis following a complete surgical resection was a hemolymphangioma.

DISCUSSION

Lymphangiomas are considered to be a congenital malformation of the lymphatic system. The greatest impediment for the diagnosis and treatment of vascular anomalies has been the confusing terminology. A biologic classification system introduced in 1982 based on studies correlating physical findings, natural history, and cellular features has clarified most of the

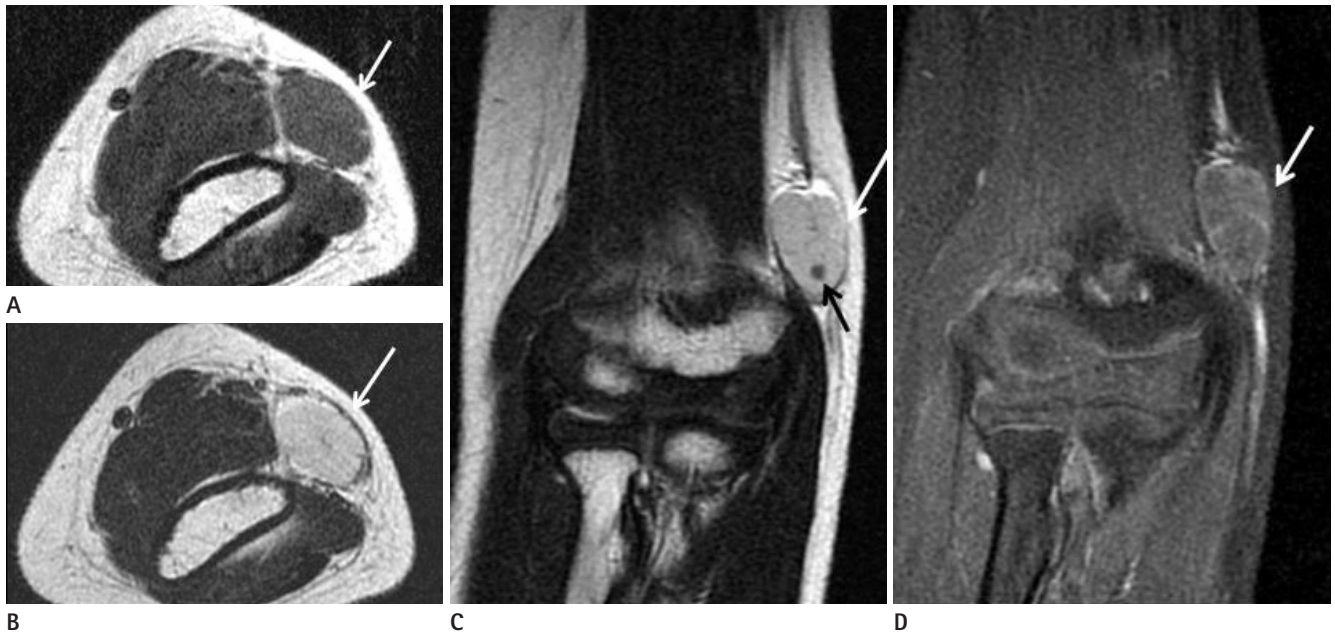


Fig. 2. MR imaging findings for the case study. Axial **(A)** T1-weighted SE image (TR: 450, TE: 11) shows an isointense mass (arrow). Axial **(B)** and coronal **(C)** T2-weighted SE image (TR: 2967, TE: 88 ms) shows homogeneous high signal intensity of the entire mass (white arrow) with thin hypointense septae and a focal dark signal intensity (black arrow). A coronal **(D)** contrast-enhanced T1-weighted image shows peripheral and septal enhancement of the tumor (arrow).

Note.—MR = magnetic resonance, SE = spin echo, TE = echo time, TR = repetition time

terminologic disorder. There are two major types of vascular anomalies: tumors and malformations. Vascular tumors are endothelial neoplasms characterized by increased cellular proliferation. Hemangiomas are the most common and are almost exclusive to infants. Vascular malformations are the result of the abnormal development of vascular elements during embryogenesis and fetal life. These may be single formations (capillary, arterial, lymphatic or venous) or in combination. Vascular malformations do not generally demonstrate increased endothelial turnover; they are designated according to the predominant channel type as capillary malformations, lymphatic malformations, venous malformations, arteriovenous malformations, and complex forms such as capillary-lymphatico-venous malformations. Malformations with an arterial component are fast-flow while all others are slow-flow (5-7).

Lymphangiomas are slow-flow vascular malformations and are histologically classified as capillary (formed by small thin walled lymphatic vessels), cavernous (formed by large lymphatic vessels with a fibrous adventitia), cystic (composed of macroscopic lymphatic spaces) and hemolymphangioma (combination of a hemangioma and lymphangioma).

Hemolymphangiomas are mostly presented as cystic or cavernous lesions. It generally occurs as a solitary or multiple mass in the cervicofacial region (75-90%) or in the axilla, or even in the thoracic, abdominal, retroperitoneal or mesenteric regions (1).

The incidence of hemolymphangiomas varies from 1.2 to 2.8 per 1000 newborns. However, only 6.5% of them are located at the extremities and both sexes get equally affected (2). The diagnosis in most cases (90%) is made before the age of two years, while 60% of those are present at the time of birth. In a clinical examination, they are usually described as soft and compressible masses, loculated in pattern.

The formation of the tumor may be explained by the obstruction of the venolymphatic communication, between dysembryoplastic vascular tissue and the systemic circulation during embryologic development (8). A segmentation of the outbudding of the primary lymphatic sacs is thought to be the basis of the development of this anomaly.

Takahashi et al. (9) demonstrated that during the proliferating phase, many growth factors such as vascular endothelial growth factor, basic fibroblast growth factor, proteases, and E-selectin (an adhesion molecule), may be involved.

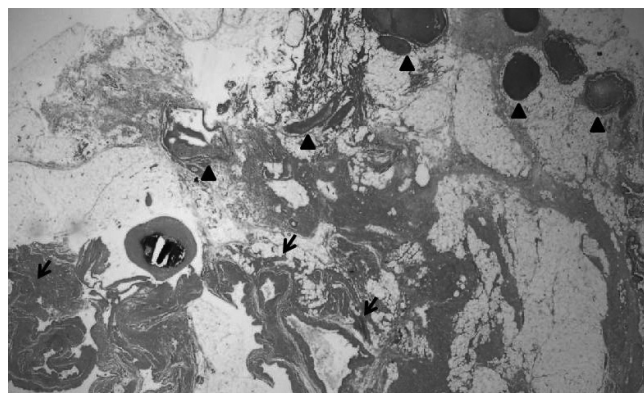


Fig. 3. Histological finding for case. Low power (H&E stain, $\times 10$) examination reveals a mixed hemangioma and lymphangioma area. Hemangiomas have thin walls and contain blood cells in the lumina (arrowheads). The lymphangioma area shows irregularly-contoured vessels with lymphoid cells (arrows).

Histologically, hemolymphangiomas consist of dense fibrous tissue that grows in bands between the numerous vascular spaces and invades the subcutaneous fat. Some of those are blood vessels, while others are lymphatic.

Its occurrence in the extremities is very rare, although two cases have been reported in the literature as hemolymphangiomas of the lower extremities in children (2). In two cases demonstrated to be a soft tissue mass in a subcutaneous fat layer of the proximal tibia, the masses demonstrated cystic mass with blood flow on ultrasound sonography and hyperintense signal intensity on T2-weighted images. Two other cases reported in the literature as cystic lymphangiomas affecting the extremities (1, 3), showed soft tissue masses in the forearm and plantar aspect of foot, respectively. In all cases, the masses showed a multilocular cystic mass without remarkable blood flow on ultrasound sonography and intermediate to low signal intensity on T1-weighted images and high signal intensity on T2-weighted images. Gadolinium-enhanced T1-weighted images showed rim enhancement of the mass in all cases. Our report is one of the first clinical descriptions by plain radiograph and magnetic resonance imaging findings of a hemolymphangioma located in an extremity.

Plain radiographs show a soft tissue mass with an intact underlying bony cortex. Some cases have a phlebolith, and are commonly misdiagnosed as hemangiomas.

Radiologic documentation is best performed by magnetic resonance imaging; where, lymphangiomas are characterized by the absence of feeding vessels and lack of intense contrast

enhancement. Hemolymphangiomas, like lymphangiomas and most vascular malformations, demonstrate hyperintense signal intensity on T2-weighted and turbo short T1 inversion recovery images. The masses demonstrate peripheral and septal enhancement after administration of gadolinium. Conventional contrast lymphangiography is rarely performed.

While the lesion is regarded a benign soft tissue tumor, the clinical and radiologic findings overlap. Differential diagnosis includes hemangioma, cystic lymphangioma, peripheral nerve sheath tumor and Kimura's disease. Kimura's disease, which is characterized as a partially or poorly defined subcutaneous mass involving the upper extremities, is very rare. Its signal intensities on T1- and T2-weighted images are similar to hemolymphangioma, but have moderate to good homogeneous enhancement, variable stranding in the surrounding subcutaneous tissue, and serpentine signal voids within the mass.

Complete surgical excision gave the best results along with a lower recurrence rate. On the contrary, aspiration and injection of sclerotic agents gave the highest risk of recurrence.

In conclusion, hemolymphangiomas are rare, especially in an extremity. It is important for the radiologist to be aware of the diagnosis. Surgical resection of the mass is recommended as part of the treatment with the goal of complete excision.

REFERENCES

1. Rossi G, Iannicelli E, Almberger M, Innocenzi D, David V.

Cystic lymphangioma of the upper extremity: US and MRI correlation (2004;11b). *Eur Radiol* 2005;15:400-402

2. Kosmidis I, Vlachou M, Koutroufinis A, Filiopoulos K. Hemolymphangioma of the lower extremities in children: two case reports. *J Orthop Surg Res* 2010;5:56

3. Ly JQ, Gilbert BC, Davis SW, Beall DP, Richardson RR. Lymphangioma of the foot. *AJR Am J Roentgenol* 2005;184:205-206

4. Suzuki N, Tsuchida Y, Takahashi A, Kuroiwa M, Ikeda H, Mohara J, et al. Prenatally diagnosed cystic lymphangioma in infants. *J Pediatr Surg* 1998;33:1599-1604

5. Christison-Lagay ER, Fishman SJ. Vascular anomalies. *Surg Clin North Am* 2006;86:393-425, x

6. Marler JJ, Mulliken JB. Current management of hemangiomas and vascular malformations. *Clin Plast Surg* 2005;32:99-116, ix

7. Dohil MA, Baugh WP, Eichenfield LF. Vascular and pigmented birthmarks. *Pediatr Clin North Am* 2000;47:783-812, v-vi

8. Balderramo DC, Di Tada C, de Ditter AB, Mondino JC. Hemolymphangioma of the pancreas: case report and review of the literature. *Pancreas* 2003;27:197-199

9. Takahashi K, Mulliken JB, Kozakewich HP, Rogers RA, Folkman J, Ezekowitz RA. Cellular markers that distinguish the phases of hemangioma during infancy and childhood. *J Clin Invest* 1994;93:2357-2364

소아의 상지에서 발생한 혈관림프관종: 증례 보고 1예¹

강효진¹ · 김용훈¹ · 황윤준¹ · 김수영¹ · 김한성²

혈관림프관종은 드문 양성 연부조직종양으로 혈관계에서 발생하는 선천적인 기형이다. 이 질환은 대부분 출생시나 소아에서 진단되고, 특히 사지에서 발생하는 경우는 극히 드물게 보고되고 있다. 이에 저자들은 보기 드문 위치인 상지에서 발생한 혈관림프관종 1예를 영상의학적 소견 및 병리 소견과 함께 보고하고자 한다. 진단은 단순촬영과 MRI 그리고 최종적으로 병리학적으로 확인되었다. 본 증례는 단순촬영에서 경계가 좋은 연부조직종양으로 정맥석을 보였고, MRI에서 다방성낭종으로 주변부 및 격막의 조영증강을 보였다.

인제대학교 의과대학 일산백병원 ¹영상의학과학교실, ²병리과학교실