

## Fenestrated Internal Jugular Vein: Case Report<sup>1</sup>

Ju Young Park, M.D., In Ho Lee, M.D., Chang June Song, M.D.

A 54-year-old woman presented with a submental mass for 10 days. She underwent neck CT and a fenestrated internal jugular vein was incidentally found. We report a case of fenestrated internal jugular vein.

**Index words :** Jugular Veins  
Tomography, X-Ray Computed

Fenestrations or duplications of the internal jugular vein (IJV) are a rare congenital anomaly in the neck. Although many arterial fenestrations have been reported in the vertebral artery, basilar artery, middle cerebral artery, anterior cerebral artery, posterior inferior cerebellar artery, posterior cerebral artery, posterior communicating artery, and internal carotid artery, fenestration of the IJV is very rare (1). To our knowledge, there have been nine case reports of fenestrated IJVs (1-9). Prades et al. (2) reported that the incidence of fenestrated IJVs is 0.4%. We report an incidentally detected fenestrated IJV.

### Case Report

A 54-year-old woman presented with a submental mass for 10 days. She underwent neck computed tomography (CT). The CT scan revealed multiple small lymph nodes in the neck. Incidentally, there was a fenestration of the right IJV (Fig. 1).

### Discussion

The IJV is the largest collecting vein of the cranium, the face and the anterior region of the neck (1, 2). Fenestrations or duplications of the IJV are rare variations, but there is an important difference between fenestration and duplication. Downie et al. (10) suggested that the term 'duplication' should be used for those cases where the branches of the anomalous vessel, regardless of artery or vein, remain separate along the whole length of their normal course and that the term 'fenestration' should be used for those cases where branched vessels rejoin a single normal vessel. According to this suggestion, our case is not a duplicated IJV but a fenestrated IJV.

Although fenestration of the IJV is clinically insignificant, preoperative diagnosis of a fenestrated IJV may be important because the accessory spinal nerve may pass through a fenestration of the IJV and resection or injury of these structures can cause considerable morbidity (3). There have also been several reports about an accessory spinal nerve passing through a fenestration of the IJV (3-5), but such nerves usually pass superficial to the IJV (2). Because our patient didn't need an operation, we were not able to find the anatomical relation between the IJV and the spinal accessory nerve.

The etiology of fenestrated IJVs is still unclear and sev-

<sup>1</sup>Department of Radiology, Chungnam National University Hospital, Chungnam National University School of Medicine, Korea  
Received August 10, 2010 ; Accepted December 8, 2010  
Address reprint requests to : In Ho Lee, M.D., Department of Radiology, Chungnam National University Hospital, Chungnam National University School of Medicine, 33 Munhwa-ro, Jung-gu, Daejeon 301-721, Korea.  
Tel. 82-42-280-8065 Fax. 82-42-253-0061  
E-mail: leeinho1974@hanmail.net

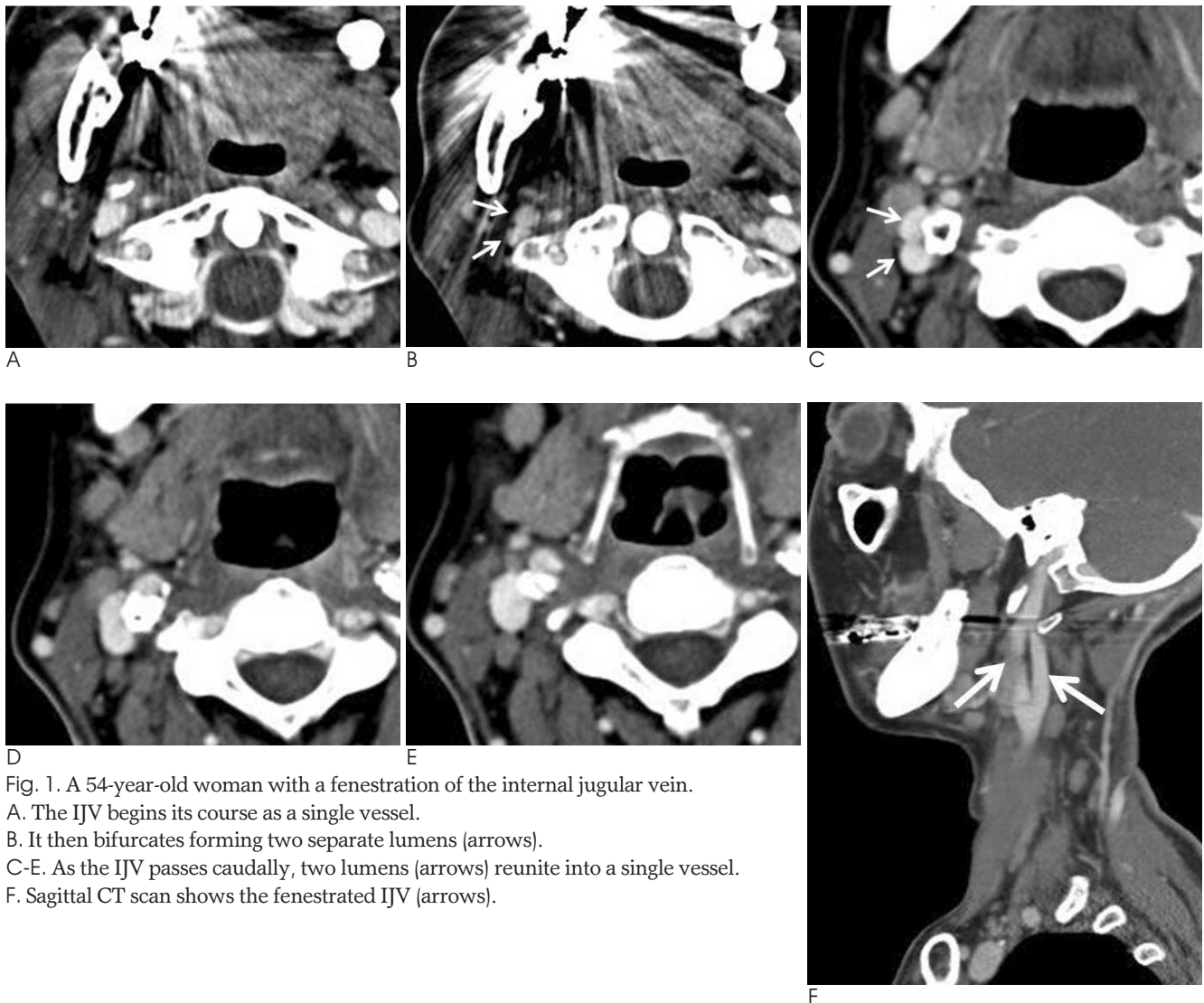


Fig. 1. A 54-year-old woman with a fenestration of the internal jugular vein.

A. The IJV begins its course as a single vessel.

B. It then bifurcates forming two separate lumens (arrows).

C-E. As the IJV passes caudally, two lumens (arrows) reunite into a single vessel.

F. Sagittal CT scan shows the fenestrated IJV (arrows).

eral hypotheses have been suggested to describe the embryological basis of this fenestration. Among vascular, neural or bony hypotheses, the vascular theory is the most likely and is usually accepted in the literature (2, 3). Embryologically the IJV has a lateral and medial vein of the head and the accessory spinal nerve passes between them. One of them, usually the lateral vein, disappears. However, a secondary venous ring surrounding the accessory spinal nerve may develop, and this may be an important cause of fenestration of the IJV (2).

Precise diagnosis, bearing in mind a fenestrated IJV as a variation, may be helpful for various surgical dissections and radiological procedures in the neck.

## References

1. Towbin AJ, Kanal E. A review of two cases of fenestrated internal jugular veins as seen by CT angiography. *AJNR Am J Neuroradiol* 2004;25:1433-1434
2. Prades JM, Timoshenko A, Dumollard JM, Durand M, Merzougui N, Martin C. High duplication of the internal jugular vein: clinical incidence in the adult and surgical consequences, a report of three clinical cases. *Surg Radiol Anat* 2002;24:129-132
3. Ozturk NC, Talas DU. Fenestration of internal jugular vein and relation to spinal accessory nerve: case report and review of the literature. *Clin Anat* 2010;23:883-884
4. Iseri M, Ustundag E, Aydin O. A rare anatomical variation of the spinal accessory nerve. *J Laryngol Otol* 2007;121:277-278
5. Gardiner KJ, Irvine BW, Murray A. Anomalous relationship of the spinal accessory nerve to the internal jugular vein. *Clin Anat* 2002;15:62-63
6. Sylaidis P, Bardsley A, Montgomery P. Duplication of internal jugular vein. *Arch Otolaryngol Head Neck Surg* 1997;123:1358
7. Rossi A, Tortori-Donati P. Internal jugular vein phlebectasia and duplication: case report with magnetic resonance angiography features. *Pediatr Radiol* 2001;31:134
8. Alaani A, Webster K, Pracy JP. Duplication of internal jugular vein and relation to the spinal accessory nerve. *Br J Oral Maxillofac Surg* 2005;43:528-531

9. Nayak BS. Surgically important variations of the jugular veins. *Clin Anat* 2006;19:544-546
10. Downie SA, Schalop L, Mazurek JN, Savitch G, Lelonek GJ, Olson

TR. Bilateral duplicated internal jugular veins: case study and literature review. *Clin Anat* 2007;20:260-266

## 내경정맥의 유창: 증례 보고<sup>1</sup>

<sup>1</sup>충남대학교병원 영상의학과

박주영 · 이인호 · 송창준

54세 여자 환자가 10일 동안 만져지는 악하 종괴를 주소로 내원하였다. 환자는 경부 전산화단층촬영을 시행하였고 내경정맥의 유창이 우연히 발견되었다. 저자들은 내경정맥의 유창에 대해서 보고하고자 한다.