

# A New Promising Technique of 3D Isovoxel Imaging Using 3T MRI in the Wrist: Comparison with 3T MR Arthrography<sup>1</sup>

Guen Young Lee, M.D., Baek Hyun Kim, M.D., Jong Woong Park, M.D.<sup>2</sup>

**Purpose:** We wanted to evaluate the usefulness of 3D isovoxel MR imaging using 3T MRI in the wrist joint, as compared with 3T MR arthrography.

**Materials and Methods:** A total of 33 patients underwent both MR arthrography and 3D isovoxel imaging of the wrist joints using 3T MR, including 11 patients with arthroscopic confirmation. 3D isovoxel MR imaging was performed using an intermediate-weighted fast spin echo coronal scan with a 0.4-mm slice thickness and the axial images were reconstructed with a 1-mm slice thickness. One radiologist evaluated for the presence of scapholunate or lunotriquetral ligament tear and she determined the grade of the triangular fibrocartilage complex tear and chondromalacia with its location. We compared the two examinations using kappa values.

**Results:** The rates of detecting wrist injury were similar for both exams with substantial to almost perfect inter-examination agreement (kappa value = 0.864 for scapholunate ligament tear, 0.835 for lunotriquetral ligament tear, 0.799 for TFCC tear and 0.940 for chondromalacia). For the eleven cases that underwent arthroscopy, their results of 3D isovoxel MRI were also similar to that of MR arthrography.

**Conclusion:** 3D isovoxel MR imaging is useful for the evaluation of the wrist joint.

**Index words :** Wrist Joint

Three-dimensional imaging  
Magnetic Resonance Imaging  
Arthrography

Direct MR arthrography (MRA) of the wrist joint is known to be superior to conventional MR imaging for the evaluation of intrinsic ligament tears or triangular fibrocartilage complex (TFCC) tears (1-6). However,

many of the studies that showed a better diagnostic performance of MRA than that of conventional MR imaging used a three-compartment injection method and they performed multiple MR sequences, and the total exam time was over 20 minutes (4, 5). When no communicational defects are visible after a single-compartment injection at the radiocarpal joint, some authors have said that at least injection into the distal radioulnar joint should be added to the diagnostic process (7). To the best of our knowledge, although many current studies have reported on 3D isovoxel MR imaging (ISO-MR) of the shoulder, knee and ankle, there has been no report

<sup>1</sup>Department of Radiology, Korea University Ansan Hospital, Korea University College of Medicine, Gyeonggi-do, Korea

<sup>2</sup>Department of Orthopedic Surgery, Korea University Ansan Hospital, Korea University College of Medicine, Gyeonggi-do, Korea

Received November 8, 2010; Accepted December 12, 2010

Address reprint requests to : Baek Hyun Kim, M.D., Department of Radiology, Korea University Ansan Hospital, 516, Gojan-dong, Danwon-gu, Ansan-si, Gyeonggi-do 425-707, Korea.

Tel. 82-31-412-5227 Fax. 82-31-412-5224

E-mail: kimbaekh@hanmail.net

about iso-MR of the wrist. So, we aimed to evaluate the usefulness of 3D isovoxel imaging using 3T MR for making the diagnosis of scapholunate (SL) tear, lunotriquetral (LT) ligament tear and TFCC tear in the wrist joint, and we compared its results with that of 3T MR arthrography.

## Materials and Methods

### *Patient selection*

From October of 2009 to October of 2010, a total 33 patients with chronic wrist pain and who underwent both ISO-MR without intra-articular contrast injection and MRA with intra-articular contrast injection were enrolled in this study. We decided to exclude the cases that had previous wrist operation, but there was no case with a history of previous wrist surgery. The mean age of the patients was 37.5 years (range: 17–59 years) and there were 23 men and 10 women. There were 23 right wrists and 10 left wrists.

### *3D Isovoxel MR Imaging (ISO-MR)*

All the ISO-MR examinations were obtained using 3T MRI (Achieva 3.0T X-series, Philips Medical System, Netherlands) with a surface coil (Sense-wrist-8, Siemens, Erlangen, Germany). ISO-MR imaging was done by performing a fat-suppressed intermediate-weighted fast spin echo coronal scan of the wrist joint (TR/TE: 1400/34 msec, slice thickness: 0.4 mm without a gap, field of view: 10 cm, matrix: 256 × 255, flip angle: 90°, ETL: 64 and number of excitations: 2). The scan time was 6 minutes 30 seconds and the number of slices in the coronal scan was 100. After coronal scanning, the axial images were reconstructed automatically in a workstation with a slice thickness of 1mm without a gap and the number of axial reconstructed images was 50. All the ISO-MR examinations were performed before MRA on the same day.

### *Direct MR Arthrography (MRA)*

MRA was done as follows: after local anesthesia with about 2 mL of 1% lidocaine solution, a fluoroscopic-guided puncture of the radiocarpal joint between the radius and scaphoid was done using a 22-gauge spinal needle. The MR contrast solution was prepared by mixing 10 mL of normal saline and 0.2 mL of MR contrast (Megaray, Dongkook pharmaceutical, Seoul, Korea). About 1mL of CT contrast was injected to confirm the intra-articular puncture and then about 2–3 mL of MR

contrast solution was injected. All the MRA scans were obtained using 3T MRI (Achieva 3.0T X-series, Philips Medical Systems, Netherlands) with a surface coil (Sense-wrist-8, Siemens, Erlangen, Germany). The T1-weighted spectral presaturation with inversion recovery (SPIR) coronal and axial images were obtained (TR/TE: 357.0/20.0 msec for the coronal scan and 528.0/22.0 msec for the axial scan, slice thickness: 3 mm without a gap, field of view: 11 cm for the coronal scan and 10 cm for the axial scan, matrix: 316 × 313 for the coronal scan and 332 × 333 for the axial scan, flip angle: 90°, ETL: 18 and number of excitations: 3). The number of slices in the coronal plane was thirteen and that of the axial plane was twenty. The scanning time for MRA was 6 minutes.

### *Image Analysis*

All 33 cases were randomized and the radiologist was blinded to the patients' age, gender and clinical history before the retrospective image reviews. One radiologist reviewed all the ISO-MR and MRA images. Evaluation of the ISO-MR images was done first and then the MRA images were investigated. The time interval between the ISO-MR and MRA image reviews was longer than one week.

On the ISO-MR and MRA images, which consisted of the axial and coronal images, the SL and LT ligament tears and TFCC tears were evaluated along with chondromalacia of the lunate or triquetrum. The presence or absence of SL or LT ligament tears was determined. On the ISO-MR, discontinuity or detachment of the SL or LT ligaments was defined as tear. On the MRA, if contrast leakage into the midcarpal joint was seen across the SL or LT ligaments, then there was a ligament tear. If a normal ligamentous structure could not be visible, then this was also defined as tear on both exams. The degree of TFCC injuries were divided into three grades (0: no TFCC abnormality, 1: TFCC wear with/without degeneration, 2: TFCC perforation), based on the Palmer classification system (8). TFCC wear was determined as TFCC thinning, and perforation was defined as discontinuity or detachment of the TFCC on both ISO-MR and MRA. For chondromalacia, the severity was also divided into three grades (0: no chondromalacia, 1: involves less than half, 2: involves half or more than half of the total cartilage thickness) along with its location.

### Arthroscopic Operation

One surgeon who was experienced with performing wrist arthroscopy performed all the arthroscopic operations on eleven wrists among the total 33 cases. He described whether there was either an intrinsic ligament tear (SL and LT ligaments) or a TFCC tear, including the severity and location of the chondromalacia of the lunate or triquetrum, based on the Palmer classification system. The mean interval was 30 days (range: 16–94 days) between ISO-MR/MRA and the arthroscopic operation.

### Statistical Analysis

For the eleven patients with arthroscopic operations, the diagnostic values (sensitivity, specificity, positive predictive value, negative predictive value and accuracy)

of ISO-MR and MRA were calculated for SL ligament tear, LT ligament tear and TFCC tear, based on the arthroscopic findings. The kappa values for the detection of SL ligament tear, LT ligament tear and TFCC tear were determined to evaluate the inter-examination agreement between ISO-MR and MRA. A kappa value was considered as slight (0–0.20), fair (0.21–0.40), moderate (0.41–0.60), substantial (0.61–0.80) and almost perfect (0.81–1.00). The statistical analysis was performed using SPSS for Windows version 17.0 (SPSS Inc, Chicago, IL, USA).

### Results

The rates of detecting SL and LT ligament tears in the

Table 1. Scapholunate (SL) and Lunotriquetral (LT) Ligament Tears on 3D Isovoxel MR and MR Arthrography

SL Ligament Tear		3D Isovoxel MR		Total
		Tear (-)	Tear (+)	
MR Arthrography	Tear (-)	21	0	21
	Tear (+)	2	10	12
	Total	23	10	33
LT Ligament Tear		3D Isovoxel MR		Total
		Tear (-)	Tear (+)	
MR Arthrography	Tear (-)	24	1	25
	Tear (+)	1	7	8
	Total	25	8	33

Table 2. Triangular Fibrocartilage Complex (TFCC) Tear and Chondromalacia on 3D Isovoxel MR and MR Arthrography

TFCC Tear		3D Isovoxel MR			Total
		Grade 0	Grade 1	Grade 2	
MR Arthrography	Grade 0	0	1	2	4
	Grade 1	0	11	1	12
	Grade 2	1	2	14	17
	Total	5	13	15	33
Chondromalacia					
		3D Isovoxel MR			Total
		Grade 0	Grade 1	Grade 2	
MR Arthrography	Grade 0	19	0	0	19
	Grade 1	1	12	0	13
	Grade 2	0	0	1	1
	Total	20	12	1	33

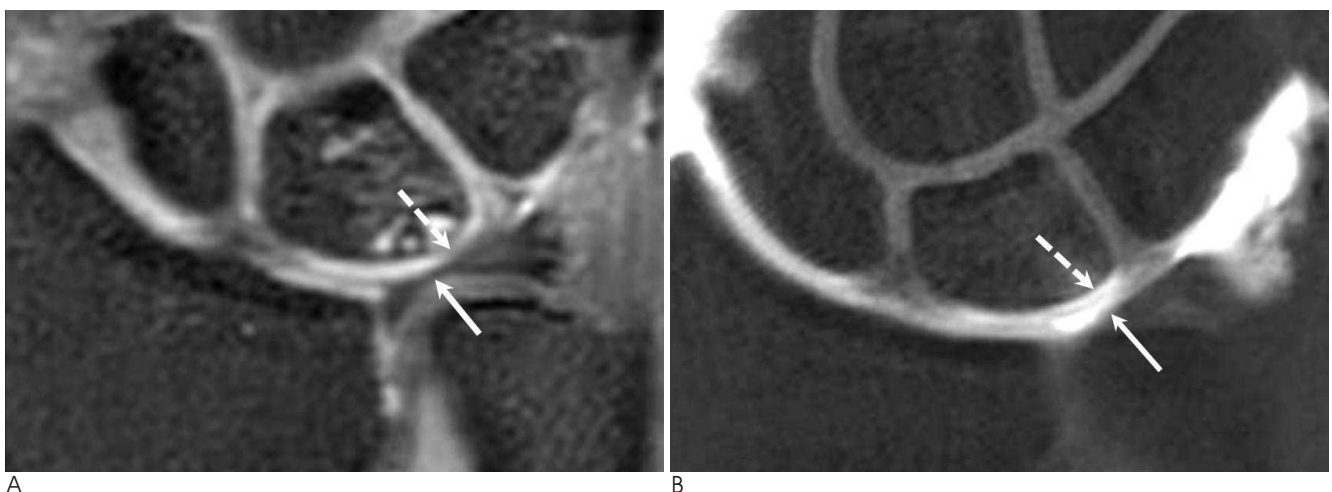


Fig. 1. A 43-year old woman with chronic wrist pain.

A. A coronal 3D isovoxel MR image shows only subtle signal change in the cartilage of the lunate (dotted arrow).

B. A coronal MR arthrographic image shows more clear detection of the minimal chondromalacia with marginal irregularity in the lunate (dotted arrow). Marked thinning of the triangular fibrocartilage complex with diffuse degeneration was revealed on both the 3D isovoxel MR and MR arthrography (arrows). This case was confirmed to have a grade 1 triangular fibrocartilage complex tear with grade 1 chondromalacia on arthroscopy.

total 33 wrists were similar on ISO-MR and MRA (Table 1). The inter-examination agreement was almost perfect between the two examinations (kappa value = 0.864 for SL ligament tear and 0.835 for LT ligament tear). For grading the TFCC tears, there was substantial inter-examination agreement (kappa value = 0.799, Fig. 1). The inter-examination agreement was also almost perfect for the grading of chondromalacia (kappa value = 0.940). The row data for TFCC tear and chondromalacia is listed in Table 2.

For the eleven cases that underwent wrist arthroscopic operations, the sensitivity, specificity, positive predictive value, negative predictive value and accuracy of SL ligament tears were 60% (3/5), 100% (6/6), 100% (3/3), 75% (6/8) and 81.8% (9/11) on ISO-MR and 80% (4/5), 100% (6/6), 100% (4/4), 85.7% (6/7) and 90.9% (10/11) on

MRA, respectively. For diagnosing LT ligament tear, all the diagnostic values were 100% for both ISO-MR and MRA, in which there were four true-positive cases and seven false-negative cases. In three cases, ISO-MR could not correctly detect the grade of TFCC tear, including two down-graded cases and one over-graded case. However, only one case was mistaken as grade 0 (no TFCC abnormality) on MRA, which was diagnosed as a grade 2 TFCC tear with partial healing and fibrosis on the arthroscopic operation. The grading of chondromalacia was the same for the two examinations (Fig. 1), except for only one case that was over-graded to grade 1 chondromalacia on both ISO-MR and MRA, and this case revealed no chondromalacia on arthroscopy.

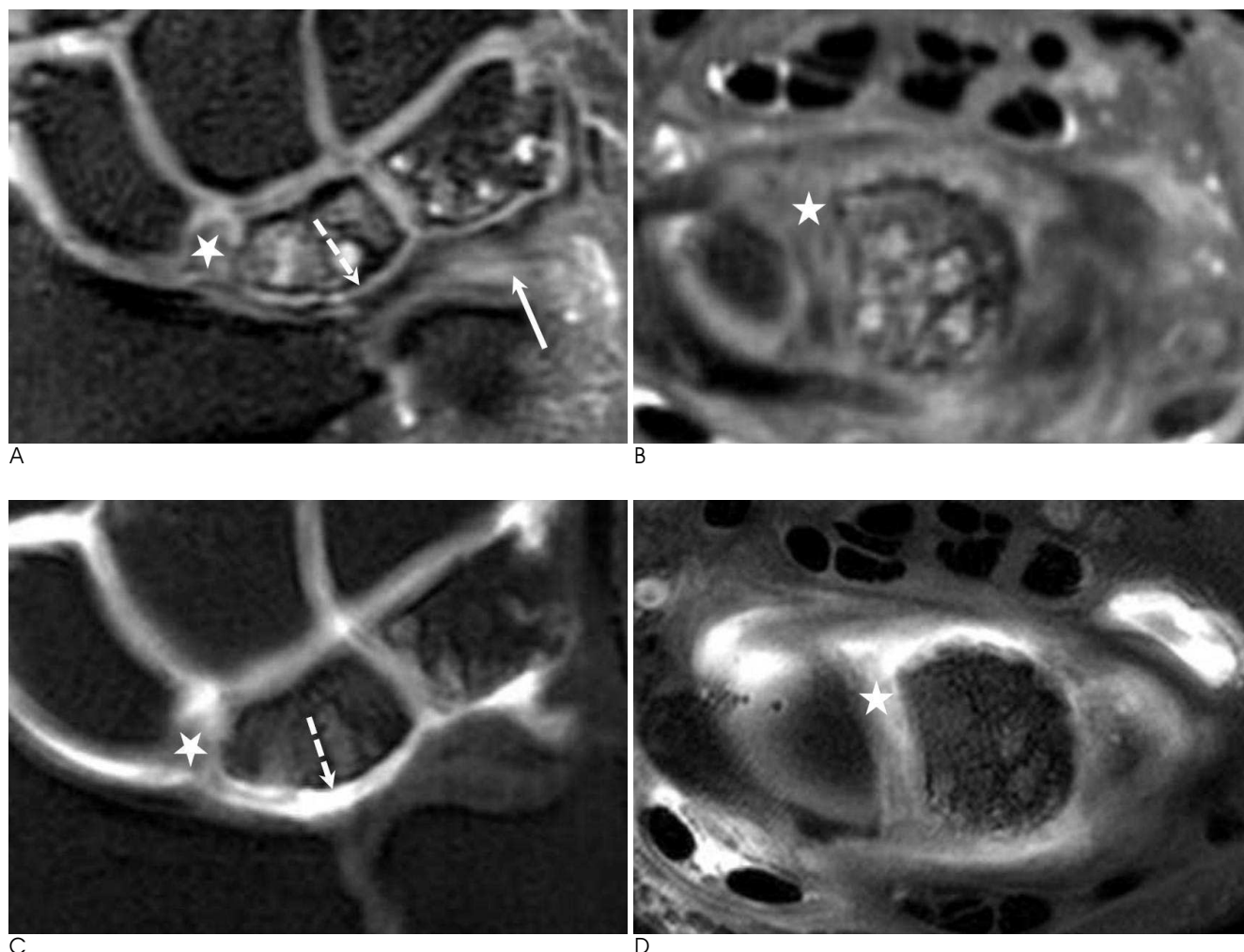


Fig. 2. A 44-year old man with chronic wrist pain.

(A, C) The coronal and (B, D) axial 3D isovoxel MR and MR arthrographic images well demonstrate the scapholunate ligament tear (star). The grade 1 triangular fibrocartilage complex tear at the ulnar side (arrow) was more definite on the 3D isovoxel MR than on the MR arthrography, but grade 2 chondromalacia of the lunate (dotted arrow) was markedly seen on MR arthrography. This patient also had a lunotriquetral ligament tear seen on arthroscopy.



## Discussion

MR imaging of the wrist to investigate wrist pathologies is challenging for radiologists because of the complex anatomy of the wrist joint, the small size of its components and there are little known asymptomatic variations (9). Many studies have demonstrated that MRA was more valuable for detecting SL ligament tear, LT ligament tear and TFCC tear than conventional MR imaging (1–6) because a wrist joint cavity can be fully expanded enough so that the internal structures can be directly visualized and clearly delineated due to intra-articular MR contrast such as Gd-DTPA (gadolinum-diethylenetriamine pentaacetic acid) on direct MRA using three- or single-compartment injection (10). However, some authors have doubts about the accuracy of MRA, and especially when single-compartment injection is used (7, 11).

MRA takes a long examination time because it needs an intra-articular contrast injection before the MR scan. In our hospital, the time needed for intra-articular injection before MRA of the wrist joint was about 8–10 minutes. As a result, the total time for wrist MRA was about 20 minutes when MRA was scanned in only the T1-weighted axial and coronal planes. Moreover, at 3T MR, the TR must be longer than that at 1.5T to improve the signal to noise ratio (SNR), and this leads to an increased scan time.

Since the first report about isotropic fast gradient echo imaging of the shoulder using 3T MR (12), many studies have been performed using isotropic MR imaging in the knee and ankle joints (13–17). Most of these studies revealed that the gradient echo sequence with isotropic MR imaging was suitable to minimize the scan time (12–13, 15–17). Only one study selected the T2-weighted fast spin echo sequence (14). We used the intermediate-weighted sequence in this study because there are some disadvantages of the gradient echo sequence such as marked susceptibility artifacts and low image resolution, and the intermediate-weighted fast spin echo sequence is more suitable to reveal chondromalacia rather than the T2-weighted fast spin echo sequence, and especially for patients with ulnar impaction syndrome. Although the scan time was not highly different between ISO-MR and MRA, the actual examination time for MRA was much longer than that for ISO-MR because the intra-articular contrast injection took 10–15 minutes (20 minutes for MRA vs. 6 minutes 30 seconds

for ISO-MR).

In our study, the agreement of ISO-MR and MRA for the detection of SL ligament tear, LT ligament tear, TFCC tear and chondromalacia was substantial to almost perfect ( $\kappa$  value = 0.799 – 0.940, Fig. 2). ISO-MR and MRA showed similar results in the eleven patients who underwent arthroscopic operations, although the sensitivity of MRA for detecting SL ligament tear was higher than that of ISO-MR (80% for MRA vs. 60% for ISO-MR).

There were some limitations in this study. First, a very small population was enrolled and especially the cases confirmed by arthroscopic operations. So, we did not correlate the results of ISO-MR with the arthroscopic findings. Second, because there has been no previous report on 3D isovoxel MR imaging using the intermediate-weighted fast spin echo sequence and not the gradient echo sequence, we did not compare our study with other studies that used the gradient echo sequence. In the future, studies with large cohorts can document the pros and cons of each sequence to be used for 3D isotropic MR of the wrist joint.

In conclusion, we suggest that 3D isovoxel MR imaging using an intermediate-weighted fast spin echo sequence and 3T MRI might be one of the best imaging modalities to evaluate the wrist joint, as compared with direct MR arthrography.

## References

1. Khoury V, Harris PG, Cardinal E. Cross-sectional imaging of internal derangement of the wrist with arthroscopic correlation. *Semin Musculoskelet Radiol* 2007;11:36-47
2. Braun H, Kenn W, Schneider S, Graf M, Sandstede J, Hahn D. Direct MR arthrography of the wrist: value in detecting complete and partial defects of intrinsic ligaments and the TFCC in comparison with arthroscopy. *Rofo* 2003;175:1515-1524
3. Kovanlikaya I, Camili D, Cakmakci H, Goktay Y, Kovanlikaya A, Ozaksoy D, et al. Diagnostic value of MR arthrography in detection of intrinsic carpal ligament lesions: use of cine-MR arthrography as a new approach. *Eur Radiol* 1997;7:1441-1445
4. Scheck RJ, Kubitzek C, Hierner R, Szeimies U, Pfluger T, Wilhelm K, et al. The scapholunate interosseous ligament in MR arthrography of the wrist: correlation with non-enhanced MRI and wrist arthroscopy. *Skeletal Radiol* 1997;26:263-271
5. Scheck RJ, Romagnolo A, Hierner R, Pfluger T, Wilhelm K, Hahn K. The carpal ligaments in MR arthrography of the wrist: correlation with standard MRI and wrist arthroscopy. *J Magn Reson Imaging* 1999;9:468-474
6. Schmitt R, Christopoulos G, Meier R, Coblenz G, Frohner S, Lanz U, et al. Direct MR arthrography of the wrist in comparison with arthroscopy: a prospective study on 125 patients. *Rofo* 2003;175:911-919
7. Maizlin ZV, Brown JA, Clement JJ, Grebenyuk J, Fenton DM,

- Smith DE, et al. MR arthrography of the wrist: controversies and concepts. *Hand* 2009;4:66-73
8. Palmer AK. Triangular fibrocartilage complex lesions: a classification. *J Hand Surg* 1989;14:594-606
9. Cerezal L, Abascal F, Garcia-Valtuille R, del Pinal F. Wrist MR arthrography: how, why, when. *Radiol Clin N Am* 2005;43:709-731
10. Tanaka T, Ogino S, Yoshioka H. Ligamentous injuries of the wrist. *Semin Musculoskelet Radiol* 2008;12:359-378
11. Joshy S, Lee K, Deshmukh SC. Accuracy of direct magnetic resonance arthrography in the diagnosis of triangular fibrocartilage complex tears of the wrist. *Int Orthop* 2008;32:251-253
12. Magee T. Can isotropic fast gradient echo imaging be substituted for conventional T1 weighted sequences in shoulder MR arthrography at 3 Tesla? *J Magn Reson Imaging* 2007;26:118-122
13. Duc SR, Pfirrmann CW, Koch PP, Zanetti M, Hodler J. Internal knee derangement assessed with 3-minute three-dimensional isovoxel true FISP MR sequence: preliminary study. *Radiology* 2008;246:526-535
14. Stevens KJ, Busse RF, Han E, Brau AC, Beatty PJ, Beaulieu CF, et al. Ankle: isotropic MR imaging with 3D-FSE-cube-initial experience in healthy volunteers. *Radiology* 2008;249:1026-1033
15. Oh DK, Yoon YC, Kwon JW, Choi SH, Jung JY, Bae S, et al. Comparison of indirect isotropic MR arthrography and conventional MR arthrography of labral lesions and rotator cuff tears: a prospective study. *AJR Am J Roentgenol* 2009;192:473-479
16. Jung JY, Yoon YC, Choi SH, Kwon JW, Yoo J, Choe BK. Three-dimensional isotropic shoulder MR arthrography: comparison with two-dimensional MR arthrography for the diagnosis of labral lesions at 3.0 T. *Radiology* 2009;250:498-505
17. Kijowski R, Blankenbaker DG, Klaers JL, Shinki K, De Smet AA, Block WF. Vastly undersampled isotropic projection steady-state free precession imaging of the knee: diagnostic performance compared with conventional MR. *Radiology* 2009;251:185-194

대한영상의학회지 2011;64:185-190

## 3T MR을 이용한 손목관절의 3차원 등화소 영상과 자기공명관절조영술의 비교<sup>1</sup>

<sup>1</sup>고려의대 안산병원 영상의학과

<sup>2</sup>고려의대 안산병원 정형외과

이근영 · 김백현 · 박종웅<sup>2</sup>

**목적:** 3T MR을 이용한 손목관절의 자기공명 관절조영술과 3차원 등방성 자기공명영상을 비교, 3차원 등방성 영상의 유용성을 평가하고자 하였다.

**대상과 방법:** 자기공명 관절조영술 및 3차원 등방성 자기공명영상을 모두 시행 받은 33명의 환자를 대상으로 하였고 이 중 11명은 검사 후 관절경 수술을 시행 받았다. 3차원 등방성 자기공명영상은 0.4 mm의 두께로 중등강조 급속 스핀에코 기법을 이용하여 관상면 스캔을 시행하였다. 각 검사에서 주상월상인대, 월상삼각인대, 섬유연골복합체 손상 유무 및 연골연화증을 평가하였고 카파 값을 구해 비교하였다.

**결과:** 두 검사 간 손목관절 손상 발견에 대해서 높은 일치도를 보였으며(kappa 값은 주상월상인대 파열 0.864, 월상삼각인대 파열 0.835, 삼각섬유인대 파열 0.799, 그리고 연골연화증 0.940), 수술을 시행 받은 11명에서도 두 검사 모두에서 비슷한 결과를 보였다.

**결론:** 3차원 등방성 자기공명영상은 손목관절 손상 진단에 유용하다.