

Circumaortic Left Brachiocephalic Vein: CT Findings¹

Mi-Suk Shim, M.D., Mi-jin Kang, M.D., Jae Hyung Kim, M.D., Woo Ho Cho, M.D.,
Soung Hee Kim, M.D., Ji-Young Kim, M.D., Soo Hyun Kim, M.D.,
Woo Sun Jun, M.D., Hyun Sun Cho, M.D.

The left brachiocephalic vein usually passes superior and anterior to the aortic arch. In rare cases, this vein follows an anomalous course; for example, a circumaortic left brachiocephalic vein. We present the case of a circumaortic left brachiocephalic vein in a 53-year-old male with lung cancer. A multidetector CT showed that the two branches of the left brachiocephalic vein circumscribed the aortic arch. The anterior branch was above and the posterior branch was below the aortic arch. Both branches drained into the superior vena cava.

Index words : Brachiocephalic vein
Tomography, X-Ray Computed

The brachiocephalic vein is formed by the internal jugular vein and the subclavian vein. The left brachiocephalic vein (LBCV) usually passes superior and anterior to the aortic arch (1). In rare cases, this vein follows an anomalous course. This anomaly was first described by Kerschner in 1888 (2) and a double LBCV described by Takata in 1992 (3). The incidence of an aberrant left brachiocephalic vein (ALBCV) with congenital heart disease is 0.15-0.98%, whereas in the general population, the incidence of this condition has been reported to be from 0.06 to 0.37% (4). In this report, we describe the computed tomography (CT) findings of circumaortic LBCV.

Case Report

A 53-year-old male presented with chest wall pain. He

underwent chest CT scan with 5-mm section thicknesses using a multidetector CT scanner (Aquilion 64, Toshiba Medical Systems, Tokyo, Japan). The images were acquired within a single breath hold after injection of the contrast medium (Iobrix 350; injection rate, 2.2 mL/sec; volume, 100 mL).

The CT scan revealed lung cancer in the right upper lobe. Incidentally, the CT identified an ALBCV that was divided into two branches at the level of the aortic arch (Fig. 1). The anterior branch was above the aortic arch and coursed anterior to the left common carotid artery and brachiocephalic artery, before draining into the superior vena cava (SVC). The posterior branch was below the aortic arch and coursed posterior to the ascending aorta. Both branches drained into the SVC separately and no other cardiovascular anomaly was noted. The patient refused further evaluation and operation.

Discussion

The brachiocephalic veins are two large vessels at the junction of the neck and thorax, which result from union of the internal jugular and subclavian veins in the

¹Department of Radiology, Sanggye Paik Hospital, Inje University College of Medicine, Korea

Received August 18, 2009; Accepted October 16, 2009

Address reprint requests to : Mi-jin Kang, M.D., Department of Radiology, Sanggye Paik Hospital, Inje University College of Medicine 761-1, Sanggye 7-dong, Nowon-gu, Seoul 139-707, Korea.

Tel. 82-2-950-1189 Fax. 82-2-950-1220 E-mail: S2621@paik.ac.kr

superior mediastinum. The LBCV begins behind the sternal end of the clavicle and ends at upper half of the manubrium sterni, and ultimately uniting with the right brachiocephalic vein to form the SVC. The LBCV usually courses obliquely downward and to the right, passing superior and anterior to the aortic arch and anterior to the left subclavian, left common carotid, and brachiocephalic arteries (1). Rarely, this vein follows an anomalous course. Kerschner described the first case of an

anomalous brachiocephalic vein beneath the aortic arch more than 100 years ago (2). Takata reported eight cases of LBCV in an anomalous position in 1992. Six cases were single aberrant LBCV, and two cases were double brachiocephalic veins (3).

In the embryonic stage (approx. 4 weeks), the primordium of the systemic veins appears as paired precardinal and postcardinal veins that unite on each side to form the common cardinal vein which opens into the

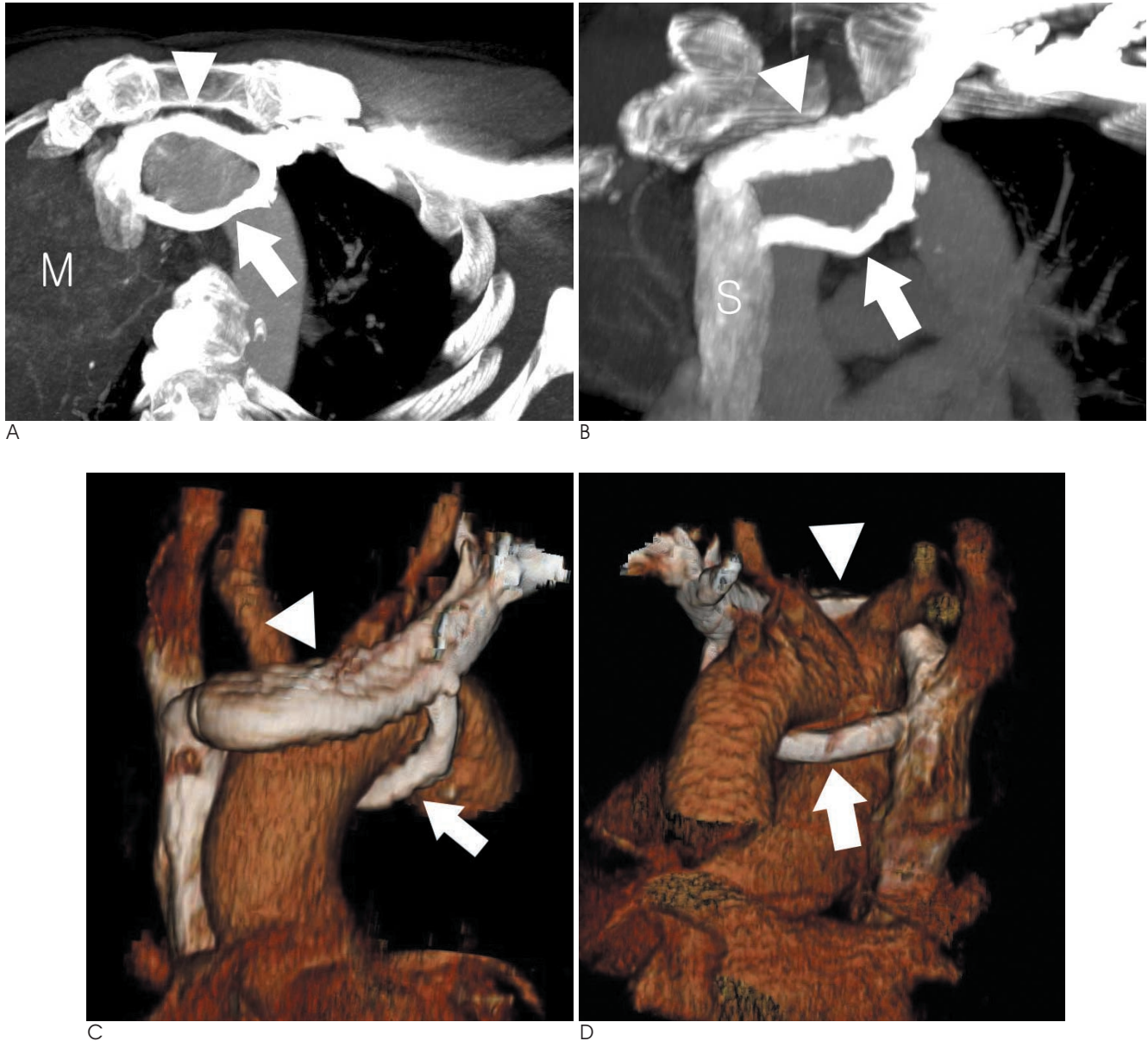


Fig. 1. A. Axial, B. coronal maximum intensity projection images show a circum-aortic left brachiocephalic vein. A circum-aortic left brachiocephalic vein divides into the anterior branch (arrowhead) and posterior branch (arrow) at the level of aortic arch. Finally, each branch drains into the superior vena cava (S). Note the lung cancer in the right upper lobe (M).

C. Anterior, D. posterior oblique coronal volume-rendered images show the anterior branch (arrowhead) and the posterior branch (arrow) of the circum-aortic left brachiocephalic vein. The anterior branch (arrowhead) courses anterior to the left common carotid artery and brachiocephalic artery, and then drains into the superior vena cava. The posterior branch (arrow) courses posterior to the ascending aorta, before draining into the superior vena cava.

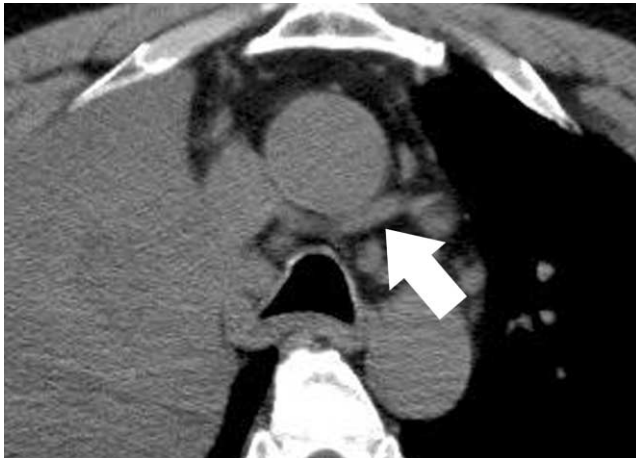

Fig. 2. Non-enhancement CT scan shows that the posterior branch (arrow) mimics an enlarged lymph node.

primitive sinus venosus. At 8 weeks, between the right and left precardinal veins, a new transverse anatomic channel (i.e. the upper transverse capillary plexus), develops and forms the LBCV. The portion above the anastomosis and the LBCV of the right precardinal vein become the right brachiocephalic vein. The distal portion of the right precardinal vein and the right common cardinal vein become the SVC. Subsequently, the subcardinal vein atrophies and is replaced by the supracardinal vein. At term, the right azygos represents the site of the right postcardinal vein, and the azygos vein orifice marks the junction of the precardinal vein and common cardinal venous components of the SVC (4-7). The exact cause of ALBCV is unknown. Normal precardinal anastomosis develops ventrally to the arterial structures. But, ALBCV is thought to result from the precardinal anastomosis being situated posterior to the truncus arteriosus, and the double LBCV is the consequence of both ventral and dorsal precardinal anastomosis (8).

Takada et al. (3) reported four major patterns of ALBCV. The report only described various types of single brachiocephalic veins: a, ALBCV crossing the midline above aortic arch and behind its major cephalic branch; b, ALBCV crossing the midline beneath the aortic arch, above the pulmonary artery, and in front of the patent ductal arteriosus; a + b, hybrid patterns of a and b, c, ALBCV crossing the midline beneath the aortic arch, above the pulmonary artery, and behind the patent ductal arteriosus; d, ALBCV crossing the midline below the pulmonary arterial trunk. However, there are only a few reports of double LBCV (3, 9). Yigit et al. (9) reported a case of double ALBCV. In this anomaly, the anterior branch was above the aortic arch and behind the trun-

cus brachiocephalicus, and finally drained into the superior vena cava. The posterior branch coursed posterior to the trachea and esophagus, and joined with the azygos vein before draining into the SVC. Takada et al. (3) reported cases of double ALBCVs, in which the posterior branch courses inferior to the aortic arch, behind the ascending arch and anterior to the trachea, and finally draining into the SVC without joining with the azygos vein. We believe that the circum-aortic type is different from the case reported by Yigit et al. (i.e. retrotracheal).

ALBCV causes no subjective symptoms and the diagnosis is incidental in most cases. Although an ALBCV by itself seems to be of no functional importance, we assessed its importance in terms of associated conditions and its possible relevance to subsequent operations.

The most frequent cardiac defects associated with ALBCV were tetralogy of Fallot and a ventricular septal defect with pulmonary atresia (10). This anomaly is also important when performing central venous catheters or cardiac surgeries. This may cause difficulties in introducing left-sided central lines unless they know the anatomy. Surgeons may not identify the anomalous course if they are not informed beforehand, which can significantly alter their surgical approach.

Moreover, recognition of this aberrant variation of the LBCV is of clinical importance to the radiologist, since a retro-aortic or subaortic segment of the ALBCV may mimic an enlarged lymph node and could be misinterpreted as an enlarged lymph node on non-contrast CT scans (9) (Fig. 2). Contrast-enhanced CT scans help in distinguishing aberrant vessels and lymph nodes. In this report, we describe the radiologic findings of a circum-aortic ALBCV. It is important for radiologists to be familiar with the CT appearance of these ALBCVs.

References

1. Standring S. *Gray's anatomy*. 39th. Edinburgh: Elsevier Churchill Livingstone, 2005:1027
2. Kerschner L. Zur. Morphologie der Vena cava inferior. *Anat Anz* 1888;3:808-823
3. Takada Y, Narimatsu A, Kohno A, Kawai C, Hara H, Harasawa A, et al. Anomalous left brachiocephalic vein: CT findings. *J Comput Assist Tomogr* 1992;16:893-896
4. Gerlis LM, Ho SY. Anomalous subaortic position of the brachiocephalic (innominate) vein: a review of published reports and report of three new cases. *Br Heart J* 1989;61:540-545
5. Arey LB. *The vascular system*. In Arey LB. *Developmental anatomy*. 7th. Philadelphia: Saunders, 1966:342-374
6. Maxwell DS. *Embryology of the vascular system*. In Moore WS. *Vascular surgery: a comprehensive reviews*. Philadelphia: Saunders, 1991:20-36

7. Kellman GM, Alpern MB, Sandler MA, Craig BM. Computed tomography of vena caval anomalies with embryologic correlation. *Radiographics* 1988;8:533-556
8. Adachi B. *Das venensystem der Japaner. Anatomie der Japaner II.* Tokyo: Kenkyusha, 1933:83-87
9. Yigit AE, Haliloglu M, Karcaaltincaba M, Ariyurek MO. Retrotracheal aberrant left brachiocephalic vein: CT findings. *Pediatr Radiol* 2008;38:322-324
10. Choi JY, Jung MJ, Kim YH, Noh CI, Yun YS. Anomalous subaortic position of the brachiocephalic vein (innominate vein): an echocardiographic study. *Br Heart J* 1990;64:385-387

대한영상의학회지 2010 ; 62 : 207-210

대동맥을 감싸는 환상 좌완두정맥의 CT 소견¹

¹인제대학교 상계백병원 영상의학과

심미숙 · 강미진 · 김재형 · 조우호 · 김성희 · 김지영 · 김수현 · 전우선 · 조현선

좌완두 정맥이 이상 경로로 주행하는 것은 드문 기형이다. 정상인에서 좌완두 정맥은 대동맥궁의 전상방을 가로질러 상대정맥으로 유입된다. 이 논문에서는 두 개의 좌완두 정맥이 대동맥궁을 둘러싸는 형태인, 대동맥환상 좌완두 정맥을 보이는 53세 남자 폐암 환자의 증례를 보고하고자 한다. 이 기형에서 좌완두 정맥의 앞쪽 가지는 대동맥궁의 위를 지나며 뒤쪽 가지는 대동맥궁의 아래를 지나 각각 상대정맥으로 합쳐진다. 이 논문에서 저자들은 이러한 대동맥환상 좌완두 정맥의 CT 소견을 살펴보고 관련된 참고 문헌들에 대해 기술하고자 한다.