

Comparison of Alcohol-Retention Sclerotherapy for Simple Cysts: Single-Session Prolonged and Multi-Session Techniques¹

So Hee Park, M.D., Hee Chul Yang, M.D., Sug Kyun Shin, M.D.²,
Do Joong Kim, M.D., Su Mi Park, M.D.

Purpose: To compare the therapeutic results of single-session prolonged sclerotherapy to a multi-session technique in patients with renal cysts.

Materials and Methods: We reviewed 47 renal cysts of 47 patients treated by sclerotherapy. All cysts were diagnosed by ultrasonography or CT. Twenty-seven cysts (group 1) were treated by multi-session sclerotherapy, which consisted of 95% alcohol retention (20–30% of the cyst volume) for 20 minutes after aspiration of the cyst fluid, which was repeated at a 24 hour interval until the daily drained fluid decreased to 10 mL. In addition, 20 cysts (group 2) were treated by single-session prolonged sclerotherapy, which consisted of one treatment session with alcohol retention (30–50% of cyst volume) for 2 hours. All patients had a follow-up ultrasonography at 3 to 6 month intervals for at least 6 months after the procedure. The therapeutic response of the treatment was classified as either a complete success (no residual cyst), partial success (diameter reduction, >50%), or failure (diameter reduction, <50%).

Results: The complete success rates in each group were 41% and 40%, along with partial success rates of 59% and 60%. No cases of treatment failure were observed in either group. In addition, no statistical difference in the therapeutic success rate was observed between two groups ($p = 0.317$).

Conclusion: Of the two sclerotherapy techniques, we recommend the single-session prolonged sclerotherapy, considering its comparable therapeutic outcome, patient comfort and reasonable cost-effectiveness.

Index words : Sclerotherapy

Alcohols

Ethanol

Kidney diseases, cystic

Sclerosing solutions

¹Department of Radiology, National Health Insurance Corporation Ilsan Hospital

²Department of Internal Medicine, National Health Insurance Corporation Ilsan Hospital

Received April 2, 2009; Accepted June 7, 2009

Address reprint requests to : Hee Chul Yang, M.D., Department of Radiology, National Health Insurance Corporation Ilsan Hospital, 1232 Baeksok-dong, Ilsandong-gu, Koyang City 410-719, Korea.

Tel. 82-31-900-0861 Fax. 82-31-900-0856 E-mail: Yang404@paran.com

Simple renal cysts are usually asymptomatic, diagnosed incidentally on imaging study, and do not require treatment. However, when the cyst is too large, it may cause symptoms such as abdominal pain, a palpable mass, abdominal discomfort and dyspnea (1–3). Under these circumstances, treatment should be considered.

In the treatment of symptomatic cysts, several therapeutic options such as surgical resection, percutaneous simple aspiration and sclerotherapy have been proposed. However, percutaneous sclerotherapy is currently generally accepted as the first line of treatment due to being less invasive and having a low rate of recurrence (1, 2, 4–6). Percutaneous sclerotherapy consists of the insertion of a catheter into the cyst, full aspiration of the internal contents of the cyst, and the injection of a sclerosing agent. The key of success for sclerotherapy is full contact between the sclerosing agent and the lining cells of the cyst, which prevent the reaccumulation of the secretion (7).

Several studies compared the therapeutic effects of a single session with that of multi-session alcohol injection. The multi-session technique showed a superior outcome, indicating the importance of a longer contact time between the sclerosing agent and cyst epithelium (8, 9). However, several disadvantages exist with the multiple session technique, which included the time consuming task of aspiration and repeated injection at 12 to 48 hour intervals. This step contributed to patient discomfort and increased risk of alcohol leakage (1). Recently, to compensate for the drawbacks of the multiple session technique, a single-session prolonged alcohol retention technique has been proposed, in which the alcohol retention time was increased over only one treatment session. However, this prolonged single-session sclerotherapy had not been well established as a standard technique for the treatment of a simple cyst.

Herein, we compared the therapeutic efficacy of the single-session prolonged alcohol retention sclerotherapy technique to multi-session alcohol retention sclerotherapy for symptomatic simple cysts.

Materials and Methods

A total of 47 patients diagnosed with simple renal cysts and underwent alcohol sclerotherapy in our department over the past 8 years between May 2000 and August 2007 were recruited in this retrospective study. The mean age of the 47 patients (17 men and 30 women) was 61.9 years. The indications for treatment were flank

pain ($n = 24$) or abdominal discomfort ($n = 14$), and patient's need without symptom ($n = 9$).

All cysts were located in the renal cortex and diagnosed by ultrasonography ($n = 40$), CT ($n = 22$), or both ($n = 15$) at least 1 month before sclerotherapy. All patients underwent a follow-up ultrasonography at 3 to 6 month intervals for at least 6 months after the procedure (mean follow-up period, 11.1 months). The size of the cyst was calculated by long diameter on ultrasonography.

Of the 47 cysts, 27 cysts were treated with multi-session sclerotherapy (group 1) during the first 5 years (between May 2000 and May 2004), and 20 cysts were treated with single-session prolonged (2 hours) alcohol retention sclerotherapy (group 2) during the next 3 years (between May 2004 and August 2007).

Written informed consent was obtained from all patients, and the institutional review board approved this retrospective study.

Technique

A cyst puncture was percutaneously performed with an 18-gauge needle under US guidance, local anesthesia, and a 0.035-inch guidewire, which was passed into the cyst. Next, a 7 Fr pigtail catheter (Dawson-Mueller Drainage Catheter, Cook, Bloomington, Illinois) was inserted into the cyst under the fluoroscopy guidance. The volume of the aspirated fluid from cyst was recorded, and 10 mL of aspirated fluid was sent for bacteriologic and cytologic examination. To evaluate the presence of extraluminal spillage or connection with the collecting system, 30–60% contrast medium diluted with normal saline was injected into the cyst equaling the aspirated volume. After confirming that there was no contrast leakage into the surrounding tissue, the contrast media within cyst was fully aspirated and 95% alcohol was slowly infused for sclerotherapy. During alcohol infusion, the patient's tolerance and vital signs were carefully observed. If there were any signs or complaints by the patient, the alcohol infusion was stopped and the infused alcohol was completely aspirated. Over the course of the procedure, the patient's vital signs including blood pressure, pulse, and oxygen saturation were monitored.

In group 1, based on the patient's tolerance, the alcohol at a quantity of 20–30% of the cyst volume (aspirated volume) was infused. However, the volume of the infused alcohol never exceeded 100 mL to avoid systemic intoxication. Next, the patients were rolled into four po-

sitions; prone, supine, left, and right lateral decubitus at 5 minute intervals. The total contact time between the sclerosing agent and the cyst wall was 20 minutes. As soon as the sclerotherapy ended, the infused alcohol was completely aspirated, but the inserted catheter was maintained for drainage purpose. Sclerotherapy was continued, using 20–30% alcohol, until the daily drained fluid volume was less than 10 mL.

In group 2, 95% alcohol equaling 30–50% of the cyst volume was infused into the cyst depending on patient's tolerance. The volume, however, never exceeded 100 mL due to safety concerns. The patients were rolled into four positions at 15 minutes intervals and this was repeated once. The total contact time between the sclerosing agent and the cyst wall was 2 hours. After 2 hours, the fluid content of the cyst was completely aspirated and the catheter was removed.

All the procedures were performed on an in-patient basis. Patients were observed after the procedure in the hospital. If necessary, analgesics were prescribed to the patients.

The disappearance of symptoms with complete elimination of the cyst during the follow-up period was considered to be a complete success. The relief of symptoms with cyst diameters reduced by more than 50% on ultrasonography was considered a partial success. When the cyst recurred to more than 50% of the original diameter and/or when the symptoms persisted, treatment was considered to have failed.

Statistical Analysis

A commercially available statistical software package (SPSS version 12.0, Statistical Package for the Social Sciences) was used for the analyses. A non-parametric Mann-Whitney *U* test was used to compare the differences between the methods. Statistical significance was defined as a *p*-value less than 0.05.

Results

In group 1, the mean cyst volume was 207.8 ± 101.5 mL. In addition, the mean amount of infused alcohol for each session was 47.8 ± 22.8 mL with a mean ratio of injected alcohol volume to cyst volume being 23% (Table 1). The number of sclerotherapy sessions averaged 2.5 ± 0.98 times; hence, the total contact time between the cyst wall and infused alcohol was 50 minutes (20 minutes per session \times 2.5 sessions). Three cysts were treated with the only one session of sclerotherapy and showed partial success (Table 2). There were no statistical difference between the number of treatment sessions and the cyst volume ($p = 0.501$).

In group 2, the mean volume of the aspirated fluid was 205.7 ± 163.0 mL and the mean amount of alcohol injected was 66.4 mL (32.4% of cyst volume).

The response rates of sclerotherapy in groups 1 and 2 were 41% ($n = 11$) vs. 40% ($n = 8$) for complete success and 59% ($n = 16$) vs. 60% ($n = 12$) for partial success. No cases of treatment failure were encountered in either of the groups. For the partial success cases, the mean diameter reduction rate was 84.0% in group 1 and 82.4% in group 2. There was no significant statistical difference in response to sclerotherapy between groups 1 and 2 ($p = 0.317$).

The mean follow-up time was 11.9 months for group 1 and 10.5 months for group 2. For the complete success cases, six of the 19 cysts disappeared within the first 3

Table 2. Sclerotherapy Response (Group 1)

Treatment number	Response		
	Complete Success	Partial Success	Fail
1	0	3	0
2	6	5	0
3	4	4	0
4	1	4	0
Total ($n = 27$)	11	16	0

Table 1. Characteristics of Patients and Cysts for Each Group

Characteristics	Group 1 ($n = 27$)	Group 2 ($n = 20$)	<i>p</i> -Value
Age	61.5 ± 11.5	62.2 ± 12.0	0.545
Cyst volume (mL)	207.8 ± 101.5 (65 – 950)	205.7 ± 163.0 (70 – 810)	0.727
Volume of injected alcohol (mL)	47.8 ± 22.8 (15 – 100)	66.4 ± 25.4 (35 – 100)	0.317
% of injected alcohol	23.0 ± 5.1	32.4 ± 9.1	0.317
Follow up period (months)	11.9 ± 2.5	10.5 ± 2.5	0.987
Hospital stay (days)	7.2 ± 5.5	4.1 ± 7.2	0.547

Note– Values are expressed as means \pm SD and the ranges are given within parentheses.

months of follow-up, whereas 13 cysts had sequentially reduced in size (mean 9.5 months) (Fig. 1).

The cyst-related symptoms improved in all patients whether there was complete or partial resolution of the cysts. Most of the patients complained of mild tightness and nausea during the initial 30 minutes of alcohol retention, but these symptoms gradually subsided within an hour. Four patients in group 1 and two patients in group 2 complained of persistent abdominal pain and consequently prescribed analgesics.

The mean hospital stays lasted 7.2 days in group 1 and 4.1 days in group 2 ($p = 0.547$). This mean included two patients (one in each group) who stayed more than 30 days because of chemotherapy for lung cancer and ER-CP-related complications. Without the two patients, the mean hospital stays fell to 6.1 days in group 1 and 2.7

days in group 2, which was statistically significant ($p = 0.007$).

Discussion

Percutaneous sclerotherapy is generally accepted as the first line of treatment for renal cysts because they are lined with a secretory epithelium (9). Alcohol is a sclerosing agent that rapidly (1–3 minutes) inactivates the secretory cell of the cyst and slowly (4–12 hours) penetrates the fibrous capsule (7). Okeke et al. reported the failure of single-session alcohol sclerotherapy for the treatment of renal cysts in all six of the patients they studied (1). The recurrence of cysts after sclerotherapy is attributed to the incomplete ablation of the cyst wall. A longer contact time between the sclerosing agent and

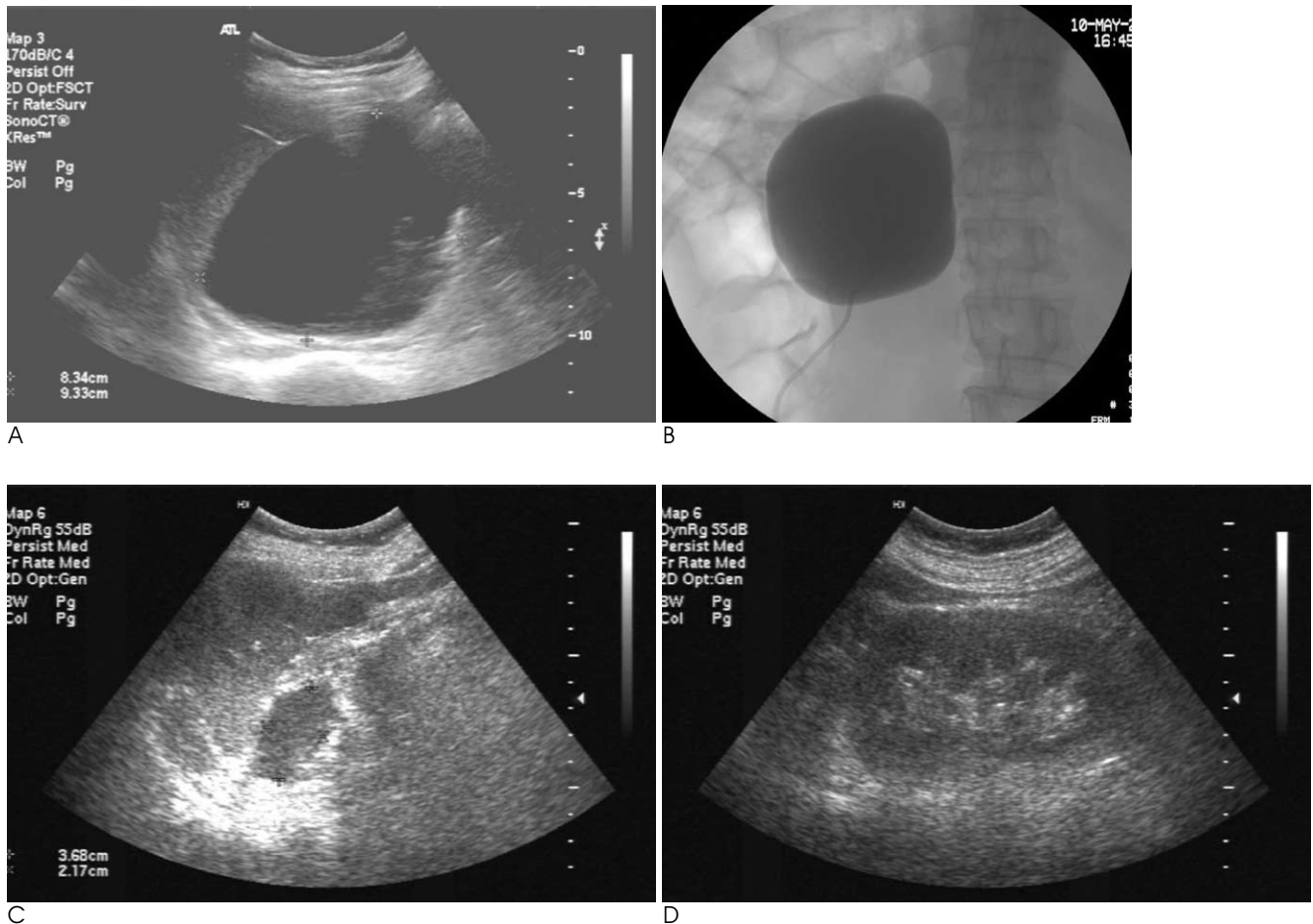


Fig. 1. A 47-year-old woman with a renal cyst treated with single-session prolonged sclerotherapy for 2 hours.

A. A renal cyst with a 9.3 cm long diameter is noted at the upper pole of the left kidney.

B. Cystogram after insertion of a 7 F pigtail catheter shows neither extravasation of contrast media nor a connection with the collecting system. After full aspiration of the contrast media, 90 mL of 95% alcohol was injected and single-session sclerotherapy was performed for 2 hours.

C. At the 3 month follow-up, the ultrasonographic findings showed the remaining cyst at 3.7 cm in long diameter.

D. At the 12 month follow-up, the ultrasonographic findings showed no remaining renal cyst.

the cyst epithelium may be the factor for inducing high success rates (7, 9). In a study comparing single and multiple session sclerotherapy of renal cysts, multiple sessions of sclerotherapy were regarded as an effective treatment for symptomatic cysts (8). However, multiple sessions of alcohol injection has several disadvantages including increased risk of alcohol leakage and patient discomfort and inconvenience (1).

Dominics et al. showed that the success rate of prolonged single session sclerotherapy technique with a alcohol retention time of 2 hours was at least comparable or superior to the single-session technique with a 60 minute retention time (10). Two other studies compared the therapeutic effect for a 2-hour retention single-session technique and a 4-hour retention single-session technique for symptomatic renal or hepatic cysts, and the results did not suggest a statistical difference between the therapeutic effects (11, 12). This result may suggest that almost all the cystic epithelium had been destroyed after the 2 hour period of alcohol retention and/or the concentration of alcohol after 2 hour of retention had been diluted to a level that failed to produce further coagulation-induced necrosis of the cyst epithelium. Therefore, we accepted the 2 hour alcohol retention sclerotherapy using alcohol (30-50% of cyst volume) for the comparison of therapeutic success between single-session prolonged and multi-session sclerotherapy.

Our study showed no therapeutic statistical difference between the multi-session and single-session prolonged sclerotherapy with 100% therapeutic response rates in both techniques. We think this comparable result comes from the longer contact time and wider contact area between the cyst lining cell and infused alcohol for the single-session prolonged sclerotherapy. In our study, the contact time was actually longer in single-session prolonged sclerotherapy (120 minutes) than the multi-session technique (about 50 minutes). Moreover, the contact area between the infused alcohol and the cyst wall was also wider in the single-session prolonged technique in which a greater volume of alcohol was infused (23.0% vs. 32.4% of cyst volume). With the lower cyst volume, the cyst has a greater likelihood to collapse or fold. However, there would be a concern that the greater the volume of infused alcohol, the higher the likelihood would be to induce more systemic intoxication. Previous investigators that used 100-150 mL of alcohol as the maximal alcohol dose showed a very low blood alcohol concentration and no cases of systemic intoxication (9, 11, 12). We also used 100 mL of alcohol as

a safety margin for sclerotherapy and no systemic intoxication was observed. However, 100 mL of alcohol as a safety margin resulted in an insufficient alcohol dose for three large cysts, which consisted of two cases from group 1 (10.5% and 11% of cyst volume) and one case from group 2 (12.5% of cyst volume). Moreover, all three cases showed partial success. Therefore, we think that repeated sclerotherapy may be necessary to induce complete success in cases with cysts larger than 300 mL.

The mean hospital stay was shorter in group 2. This represents the biggest merit of the single-session prolonged technique, because a shorter hospital stay provides a significant benefit to a patient, both economically and psychologically. However, the 4.1 day mean hospital stay for group 2 may be considered too long for only a single session therapy. We think that this long hospital stay is not related to the treatment itself, but rather to other factors such as the hospital administration process, the patient's other conditions, personal need for a health check-up, and so on.

Several limitations exist in this study. First, the sample size is small, which limits the generalization of the results. Second, this patient series is retrospective and lacks randomization; therefore, patient selection bias may have played a role in the findings. Third, the follow-up period is short and variable. Some of the residual cysts in our series became smaller in size as time went by, but we could not determine the proper follow-up interval. Fourth, we did not check up the concentration of blood or urine alcohol, so we could not suggest the safety margin for the amount of alcohol necessary to decrease the risk of systemic intoxication.

In conclusion, no statistical difference was observed between the therapeutic success rates for the single-session prolonged (2 hours) sclerotherapy and multi-session sclerotherapy. The single-session prolonged sclerotherapy has an effective therapeutic outcome in the treatment of symptomatic cysts. This technique is not only easy to perform but has the advantages of relatively lower cost and shorter hospital stay. Therefore, we recommend that single-session prolonged sclerotherapy be performed in patients with symptomatic simple cysts.

References

1. Okeke AA, Mitchelmore AE, Keeley FX, Timoney AG. A comparison of aspiration and sclerotherapy with laparoscopic de-roofing in the management of symptomatic simple renal cysts. *BJU Int* 2003;92:610-613
2. Hanna RM, Dahniya MH. Aspiration and sclerotherapy of symp-

- tomatic simple renal cysts: value of two injections of a sclerosing agent. *AJR Am J Roentgenol* 1996;167:781-783
3. Vauthey JN, Maddern GJ, Blumgart LH. Adult polycystic disease of the liver. *Br J Surg* 1991;78:524-527
 4. Saini S, Mueller PR, Ferrucci JT Jr, Simeone JF, Wittenberg J, Butch RJ. Percutaneous aspiration of hepatic cysts does not provide definitive therapy. *AJR Am J Roentgenol* 1983;141:559-560
 5. Newman KD, Torres VE, Rakela J, Nagorney DM. Treatment of highly symptomatic polycystic liver disease. Preliminary experience with a combined hepatic resection-fenestration procedure. *Ann Surg* 1990;212:30-37
 6. Kairaluoma MI, Leinonen A, Stahlberg M, Paivansalo M, Kiviniemi H, Siniluoto T. Percutaneous aspiration and alcohol sclerotherapy for symptomatic hepatic cysts. An alternative to surgical intervention. *Ann Surg* 1989;210:208-215
 7. Bean WJ. Renal cysts: treatment with alcohol. *Radiology* 1981;138:329-331
 8. Chung BH, Kim JH, Hong CH, Yang SC, Lee MS. Comparison of single and multiple sessions of percutaneous sclerotherapy for simple renal cyst. *BJU Int* 2000;85:626-627
 9. Delakas D, Karyotis I, Loumbakis P, Daskalopoulos G, Charoulakis N, Cranidis A. Long-term results after percutaneous minimally invasive procedure treatment of symptomatic simple renal cysts. *Int Urol Nephrol* 2001;32:321-326
 10. De Dominicis C, Ciccariello M, Peris F, Di Crosta G, Sciobica F, Zuccala A, et al. Percutaneous sclerotization of simple renal cysts with 95% ethanol followed by 24-48 h drainage with nephrostomy tube. *Urol Int* 2001;66:18-21
 11. Lin YH, Pan HB, Liang HL, Chung HM, Chen CY, Huang JS, et al. Single-session alcohol-retention sclerotherapy for simple renal cysts: comparison of 2- and 4-hr retention techniques. *AJR Am J Roentgenol* 2005;185:860-866
 12. Yang CF, Liang HL, Pan HB, Lin YH, Mok KT, Lo GH, et al. Single-session prolonged alcohol-retention sclerotherapy for large hepatic cysts. *AJR Am J Roentgenol* 2006;187:940-943

대한영상의학회지 2009 ; 61 : 215-220

단순 신낭종 치료에서 1회 지연 알코올 경화술과 다중 알코올 경화술의 비교¹

¹국민건강보험공단 일산병원 영상의학과

²국민건강보험공단 일산병원 내과

박소희 · 양희철 · 신석균² · 김도중 · 박수미

목적: 단순 신낭종의 치료에 있어서 1회 지연 알코올 경화술과 다중 알코올 경화술의 치료 결과를 비교하고자 하였다.

대상과 방법: 95%의 알코올로 경화술을 시행한 47명 환자의 47개 신낭종을 분석하였다. 모든 낭종은 초음파와 CT를 통해 진단되었다. 27명의 환자에서는 낭종의 액체를 모두 제거한 후 낭종 크기의 20~30%에 해당하는 알코올을 주입하여 20분간 경화술을 시행하였고 배액량이 10 mL 미만이 될때까지 반복 경화술을 시행하였다(그룹1). 20명의 환자는 낭종 크기의 30~50%의 알코올을 주입하여 2시간 동안 지연 경화술을 1회 시행하였다(그룹2). 모든 환자는 6개월 이상의 추적 초음파검사를 시행하였고 추적검사서 남아있는 낭종이 없을 때 성공, 낭종의 구경이 50% 이상 감소시 부분적 성공, 50% 이내 감소시 실패로 결과를 평가하였다.

결과: 그룹1과 그룹2에서의 성공은 각각 41%, 40%였으며 부분적 성공은 59%, 60%였다. 두 그룹 모두에서 실패는 없었으며 두 그룹 간 치료 성공률 사이에 통계학적 유의한 차이는 없었다($p = 0.317$).

결론: 단순 신낭종의 치료에 있어 1회 지연 경화술은 다중 경화술과 비슷한 치료 성적을 보였던 바 환자의 편의성과 비용을 고려하여 1회 지연 경화술을 추천하고자 한다.