

Ossifying Lipoma in the Inguinal Region : A Case Report¹

Chun-Ai Li, M.D., In Hwan Kim, M.D., Sang Yong Lee, M.D.

Ossifying lipoma is a rare benign tumor, and most of the previously reported ossifying lipomas have been found in the head and neck region. We report here on the case of a 35-year-old female with an ossifying lipoma in the inguinal region. To the best of our knowledge, this case of ossifying lipoma may be the first one that's occurred in the inguinal region. Here we present the CT and MR imaging findings of ossifying lipoma and we correlate them with the pathologic findings. We discuss making the differential diagnosis of this rare lipoma variant lesion according to this lesion's characteristic findings on the CT and MR, and we correlate these findings with the histopathology.

Index words : Soft tissues, neoplasms

Lipoma

Soft tissues, MR

Ossifying lipoma is a rare benign tumor and a variant of lipoma. This tumor is histologically composed of mature adipose tissue separated by strands of fibroconnective tissue. Trabecular bony structures can also be detected in this tumor. Most of the reported ossifying lipomas have been found in the head and neck. There have been 2 recently reported cases that were found adjacent to the sternoclavicular joint and distal thigh (1).

We present here the case of a 35-year-old female with ossifying lipoma in the inguinal region. To the best of our knowledge, this case may be the first ossifying lipoma that has occurred in the inguinal region. We also correlate the CT and MRI findings with the histopathologic

findings.

Case Report

A 35-year-old female presented to our hospital because of a palpable mass in the right inguinal region that she'd had for one year. The mass was incidentally palpated in the upper thigh and it had slowly increased in size. There was no history of trauma to the site and no tenderness over the mass on the physical examination. The palpable mass was 6 × 5 cm in size, hard and fixed. All the laboratory findings were within the normal limits.

Plain radiography revealed an ossified round soft tissue mass in the right inguinal region. MRI (Siemens Medical Systems, Erlangen, Germany) was performed to characterize the ossified mass seen on plain radiography. The coronal MR images showed a well-defined mass with heterogeneous internal signal intensities on both the T1-weighted (TR/TE, 420/12 msec; slice thickness, 3 mm; matrix, 512 × 342; FOV, 380 × 362 mm) and

¹Department of Radiology, Chonbuk National University Medical School, Korea

본 연구는 전북대학교병원 임상연구소 지원으로 이루어 졌음
Received April 3, 2009; Accepted May 11, 2009

Address reprint requests to : Sang Yong Lee, M.D., Department of Radiology, Chonbuk National University Medical School, 634-18 Keumam-dong, Dukjin-ku, Jeonju, Jeonbuk 561-712, Korea.

Tel. 82-63-250-1178 Fax. 82-63-272-0481

E-mail: sangyleekr@gmail.com

T2-weighted (TR/TE, 3700/99 msec; slice thickness, 3 mm; matrix, 512×342 ; FOV, 380×362 mm) images. On the MR images, the signal intensity of the background of the mass was bright and it was the same as that of subcutaneous fat tissue. There was no enhancement in the mass on the T1-weighted MR image obtained after intravenous injection of contrast material. The signal intensity of the internal serpiginous structures of the mass was low on the T1 and T2-weighted MR images. The coronal T2-weighted MR image also revealed area of focal high signal intensity. There was no abnormal signal intensity in the surrounding muscle

and bone marrow cavity (Fig. 1A, B).

The CT (Somatom plus 4, Siemens, Erlangen, Germany) images were obtained to further determine the nature of the low-signal-intensity structures on the MR images, which showed a well-defined ossified mass that was located between the right pectineus and adductor brevis muscles. Irregular linear bony components were mixed with a hypodense background on the CT images. There was no continuity between the mass and the adjacent pelvic bone. The CT images obtained after intravenous injection of contrast material showed no enhancement in the tumor (Fig. 2A, B).

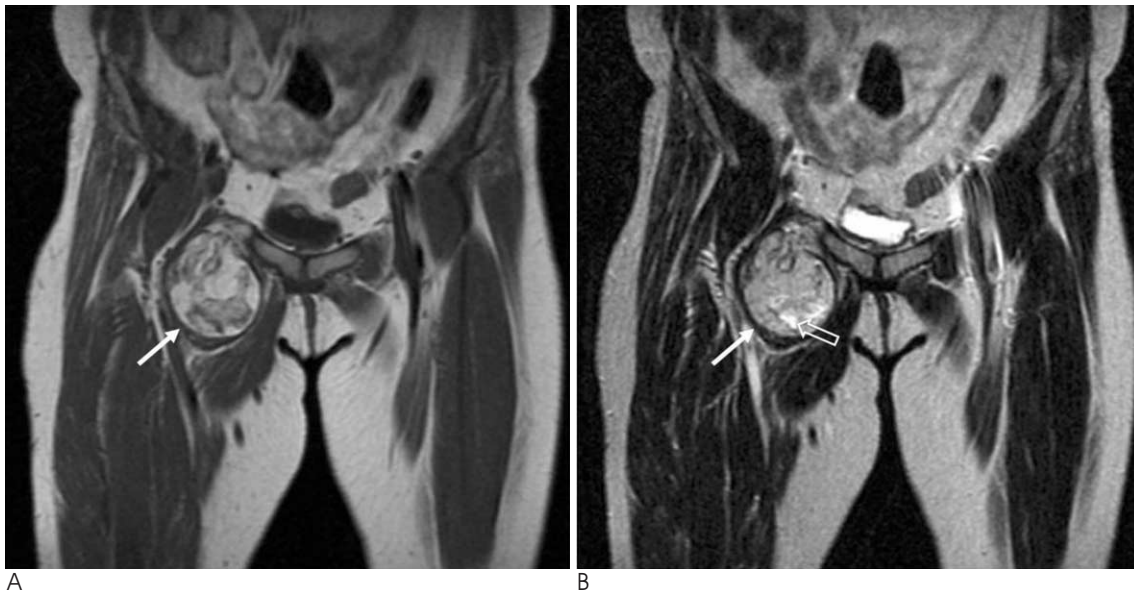

Fig. 1. MR Images of a 35-year-old female with ossifying lipoma in the right inguinal region.

A, B. The coronal T1-weighted (A) and T2-weighted (B) MR images show a well-defined mass with heterogeneous internal signal and bright background signal intensity (solid arrow). The signal intensity of the internal serpiginous structures of the mass was low on the T1 and T2-weighted images. The coronal T2-weighted MR image also revealed areas of focal high signal intensity (open arrow).

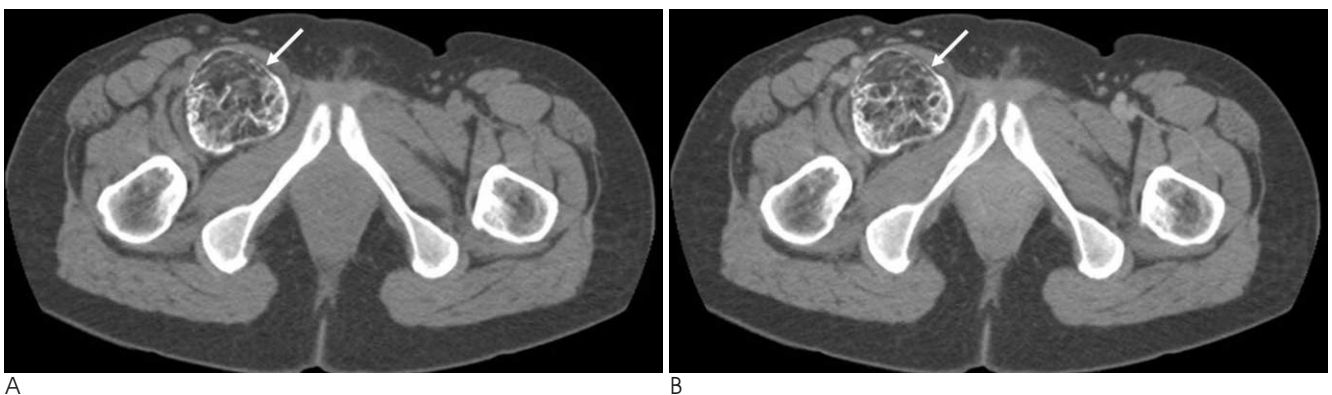


Fig. 2. The CT Images of a 35-year-old female with ossifying lipoma in the right inguinal region.

A. The pre-contrast CT image shows a well-defined ossified mass (arrow) that is located between the right pectineus and adductor brevis muscles. Irregular linear bony components are mixed with a hypodense fatty background.

B. CT image after contrast injection shows no enhancement within the tumor (arrow).

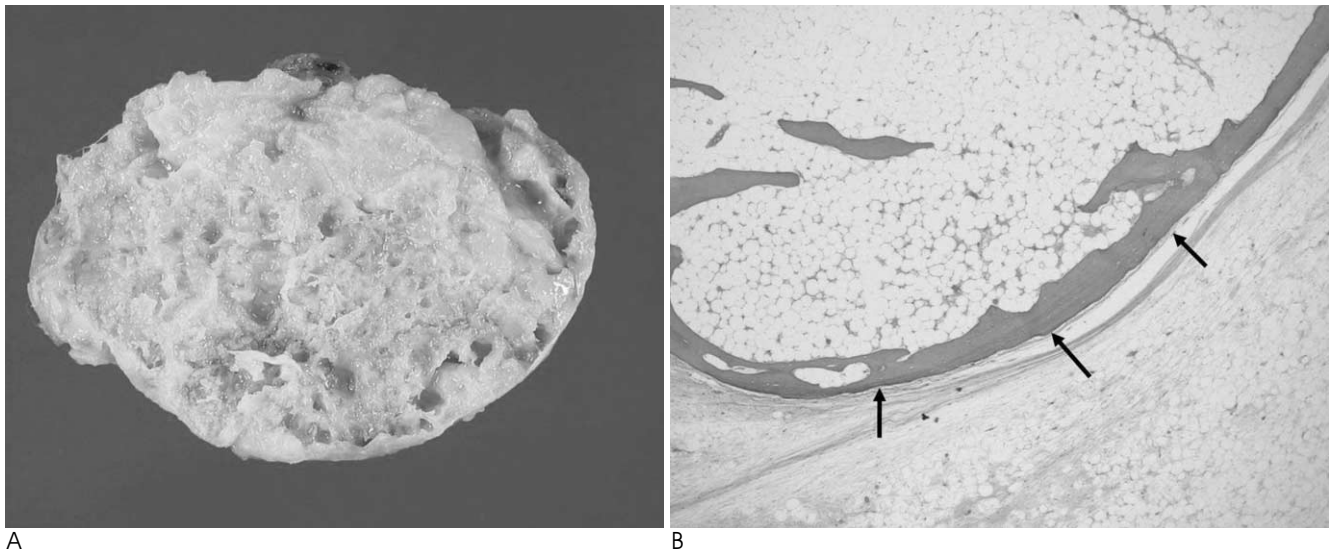


Fig. 3. The pathologic specimen of the excised ossifying lipoma from the right inguinal region of a 35-year-old female.
 A. There are areas of bright yellowish adipose tissue and serpiginous whitish bony tissue within the mass on the gross specimen.
 B. The mass is mainly composed of mature lamellar bony components with bone marrow (arrows), mature adipose tissue and strands of fibrous connective tissue (H & E, $\times 40$).

The diagnostic impression was a benign tumor containing a fatty tissue component, and so we totally removed the tumor. The bright yellowish portions of the mass on the gross specimens were areas of adipose tissue and the serpiginous whitish areas were osseous structures on the pathological examinations. The mass was mainly composed of mature lamellar bony components with bone marrow, mature adipose tissue and strands of fibrous connective tissue (Fig. 3A, B).

Discussion

Lipoma is the most common benign tumor that's composed of mature adipose cells. Variants of lipoma have been classified according to the combinations of various tumor components as angiolipoma, fibrolipoma, myxolipoma, myelolipoma, myolipoma, chondroid lipoma, pleomorphic lipoma and ossifying lipoma (2). Lipomas with ossification have been referred to as ossifying lipoma or osteolipoma, and they are very rare variants of lipoma. Only one case was found in a previous series of 126 fatty masses (1). Lipomas with ossification and a predominant fatty component are referred to as ossifying lipomas, and those without a predominant fatty component are referred to as osteolipoma (3). However, in the previously reported cases, the terms ossifying lipomas and osteolipomas have been used interchangeably (3, 4).

Since the first description by Plaut et al in 1959 (5), os-

sifying lipomas have been frequently found in the head and the neck, including the region of the tuber cinereum, the hypothalamus, the suprasellar region and the oral cavity (6). Other locations for this tumor have been the hand, the thigh and adjacent to the sternoclavicular joint and the knee joint (1, 7). To the best of our knowledge, our case is the first case of ossifying lipoma occurring in the inguinal region.

Lipomas with ossification can be attached to long bones and these have been referred to as parosteal lipoma (8). The osseous components in parosteal lipoma are usually connected to the cortex of the adjacent bone and not to the bone marrow cavity. Our case displayed no attachment to the adjacent pelvic bone or femur on the images and on the operation field. The previous reported cases in thigh (1) also had a direct connection to the periosteum of the adjacent bone seen on either on the images or on the operation field.

The pathologic examination in our case showed adipocytes, fibrous septae and thin trabeculae, which were especially located along the tumor margin. In contrast to the previous reports (7), there was no cartilage component or osteoblasts lining the trabeculae. There are two main theories concerning the origin of the ossification in ossifying lipoma. One is that the lipoblasts, chondroblasts, fibroblasts and osteoblasts come from neoplastic transformation of different mesenchymal cells, and the other theory is that the cartilage and bony components come from metaplasia of pre-existing fibro-

fatty mesenchymal components (9). Researchers who support the second theory for the origin of the osseous component call this tumor ossifying lipoma instead of osteolipoma.

MR images are known to be useful in differentiating simple lipoma from liposarcoma, and especially for differentiating the lipoma-like subtype of well-differentiated liposarcoma (1, 10). Galant et al. (10) reported that overdiagnoses of well-differentiated liposarcoma can occur due to the presence of non-lipomatous areas within lipomas. In our case, coronal T2-weighted MR image revealed high-signal-intensity foci in the tumor and the T1-weighted MR image showed thickened or nodular septa with surrounding high-signal-intensity adipose tissue (Fig. 1). The lack of awareness about the MR signal intensities of the nonadipose tissue components can lead to misinterpreting the MR images of the variants of lipoma. Furthermore, no matter how low the incidence of the variants of lipoma is, a thorough understanding of the various MR findings of those tumors is needed to prevent overdiagnosis, and especially for the case that has no available plain radiography or CT scans.

The CT images of ossifying lipoma may be useful to characterize the lipoma variants before an operation. Problems may arise when CT images are used to evaluate soft tissue tumors that contain osseous components, including a dermoid component, tumoral calcinosis, teratoma, calcification in a bursa, ossifying fibroma, myositis ossificans and osteosarcoma (9). In our case, the CT images showed a honeycomb-like osseous component and surrounding low-density fatty components.

Although the differential diagnosis of a tumor that contains osseous and fatty components is sometimes difficult based solely on the radiological images, a diffuse fine pattern of mature ossification and bland mature fatty tissue is of great value for making the diagnosis of ossifying lipoma.

References

1. Gaskin CM, Helms CA. Lipomas, lipoma variants, and well-differentiated liposarcomas (atypical lipomas): results of MRI evaluations of 126 consecutive fatty masses. *AJR Am J Roentgenol* 2004; 182:733-739
2. Mentzel T, Fletcher CD. Lipomatous tumours of soft tissues: an update. *Virchows Arch* 1995;427:353-363
3. Jaiswal AK, Garg A, Mahapatra AK. Spinal ossifying lipoma. *J Clin Neurosci* 2005;12:714-717
4. Minutoli F, Mazziotti S, Gaeta M, Vinci S, Mastroeni M, Blandino A. Ossifying lipoma of the parapharyngeal space: CT and MRI findings. *Eur Radiol* 2001;11:1818-1821
5. Plaut GS, Salm R, Truscott DE. Three cases of ossifying lipoma. *J Pathol Bacteriol* 1959;78:292-295
6. Piattelli A, Fioroni M, Iezzi G, Rubini C. Osteolipoma of the tongue. *Oral Oncol* 2001;37:468-470
7. Lee F, Keel SB, Gebhardt MC, Rosenthal DI. Intra-articular lipoma with osteochondroid metaplasia in the knee joint. *Skeletal Radiol* 2001;30:230-233
8. Aydingoz U, Tutar E, Gedikoglu G, Senaran H. Parosteal ossifying lipoma. *Eur Radiol* 2000;10:1205-1206
9. Obermann EC, Bele S, Brawanski A, Knuechel R, Hofstaedter F. Ossifying lipoma. *Virchows Arch* 1999;434:181-183
10. Galant J, Marti-Bonmati L, Saez F, Soler R, Alcala-Santaella R, Navarro M. The value of fat-suppressed T2 or STIR sequences in distinguishing lipoma from well-differentiated liposarcoma. *Eur Radiol* 2003;13:337-343

대한영상의학회지 2009 ; 61 : 123 - 126

서혜부에서 발생한 골지방종: 증례 보고¹

¹전북대학교 의학전문대학원 영상의학과

이춘애 · 김인환 · 이상용

골지방종은 드문 양성 종양으로 대부분 두경부에서 발생하는 종양으로 보고되었다. 하지만, 저자들은 35세 여자 환자의 서혜부에 발생한 골지방종 증례의 전산화단층촬영, 자기공명영상 소견과 조직병리소견을 함께 보고하고자 한다. 변이성 종양인 골지방종을 감별진단 하는데 있어서 도움이 되는 영상검사 특성을 문헌 고찰과 함께 보고한다.