

MR Imaging Features of a Solitary Subcutaneous Metastasis from a Gastric Adenocarcinoma: A Case Report¹

Jung-Im Kim, M.D., Jung-Ah Choi, M.D.^{1,2}, Jin-Haeng Chung, M.D.³, Joo Han Oh, M.D.⁴,
Ja-Young Choi, M.D., Sung Hwan Hong, M.D., Heung Sik Kang, M.D.^{1,2}

Subcutaneous tissue is an unusual site for a metastasis from a gastric carcinoma. We present a case of a patient with a nodular solitary subcutaneous metastasis from a gastric cancer and describe its magnetic resonance imaging (MRI) features.

Index words : Soft tissue neoplasms
Neoplasm metastasis
Diagnosis
Magnetic resonance (MR)
Stomach neoplasms

The most common metastatic sites of gastric carcinoma include the liver, lung, lymph nodes and peritoneum. A metastasis to soft tissue such as skeletal muscle or subcutaneous fatty tissue from a gastric carcinoma is extremely rare. This ominous complication usually occurs only late in the disease course of most patients. With improvement in gastric cancer treatment, a subcutaneous metastasis may be more frequently found due to prolonged patient survival. As gastric carcinoma metastases are rare, presumptive pathophysiology and imaging features have not been well characterized. Few reports in the literature have described computed tomography (CT) and MR findings of skeletal muscle metastases of gastric cancer (1, 2). However, there are

no known studies in the clinical literature concerning MR imaging findings of a subcutaneous metastasis from gastric cancer to the best of our knowledge. We present a case of a nodular solitary subcutaneous metastasis from a gastric carcinoma with a description of the MR imaging features, which were helpful to characterize the lesion as well as to define the extent of the metastasis for the excision of the mass.

Case Report

A 78-year-old woman visited our institution with complaints of poor oral intake and weight loss over the previous few months. The patient was diagnosed as having advanced gastric cancer based on CT scans and an endoscopic study with pathological confirmation. The patient underwent a curative subtotal gastrectomy with a lymphadenectomy. A 7 × 6.5 × 2.5 cm sized tumor in the antrum of the greater curvature was classified macroscopically as Borrmann type 3 and was microscopically classified as a moderately to poorly differentiated adenocarcinoma with regional lymph node invasion (T2N1). There was no evidence of the presence of a distant metastasis on the initial preoperative work-up and the results of all the blood chemistries were within normal

¹Department of Radiology and Institute of Radiation Medicine, Seoul National University College of Medicine, Seoul, Korea

²Department of Radiology, Seoul National University Bundang Hospital, Seongnam-si, Gyeonggi-do, Korea

³Department of Pathology, Seoul National University Bundang Hospital, Seongnam-si, Gyeonggi-do, Korea

⁴Department of Orthopedic Surgery, Seoul National University Bundang Hospital, Seongnam-si, Gyeonggi-do, Korea

Received July 1, 2008 ; Accepted December 29, 2008

Address reprint requests to : Jung-Ah Choi, M.D., Department of Radiology, Seoul National University Bundang Hospital, 300 Gumi-dong, Bundang-gu, Seongnam-si, Gyeonggi-do, 463-707, Korea.

Tel. 82-31-787-7609 Fax. 82-31-787-4011

E-mail: jacrad@radiol.snu.ac.kr

limits. The patient was discharged two weeks after the gastrectomy and the patient received no further adjuvant chemotherapy.

Six months later, the patient visited our institution with a complaint of a newly appeared palpable nodule

in the right upper thigh. On a physical examination, an approximately 2.5 cm sized subcutaneous mass was discovered; the mass was well demarcated, non-tender and mobile. There were no additional findings such as swelling, heating sensation and skin ulceration.

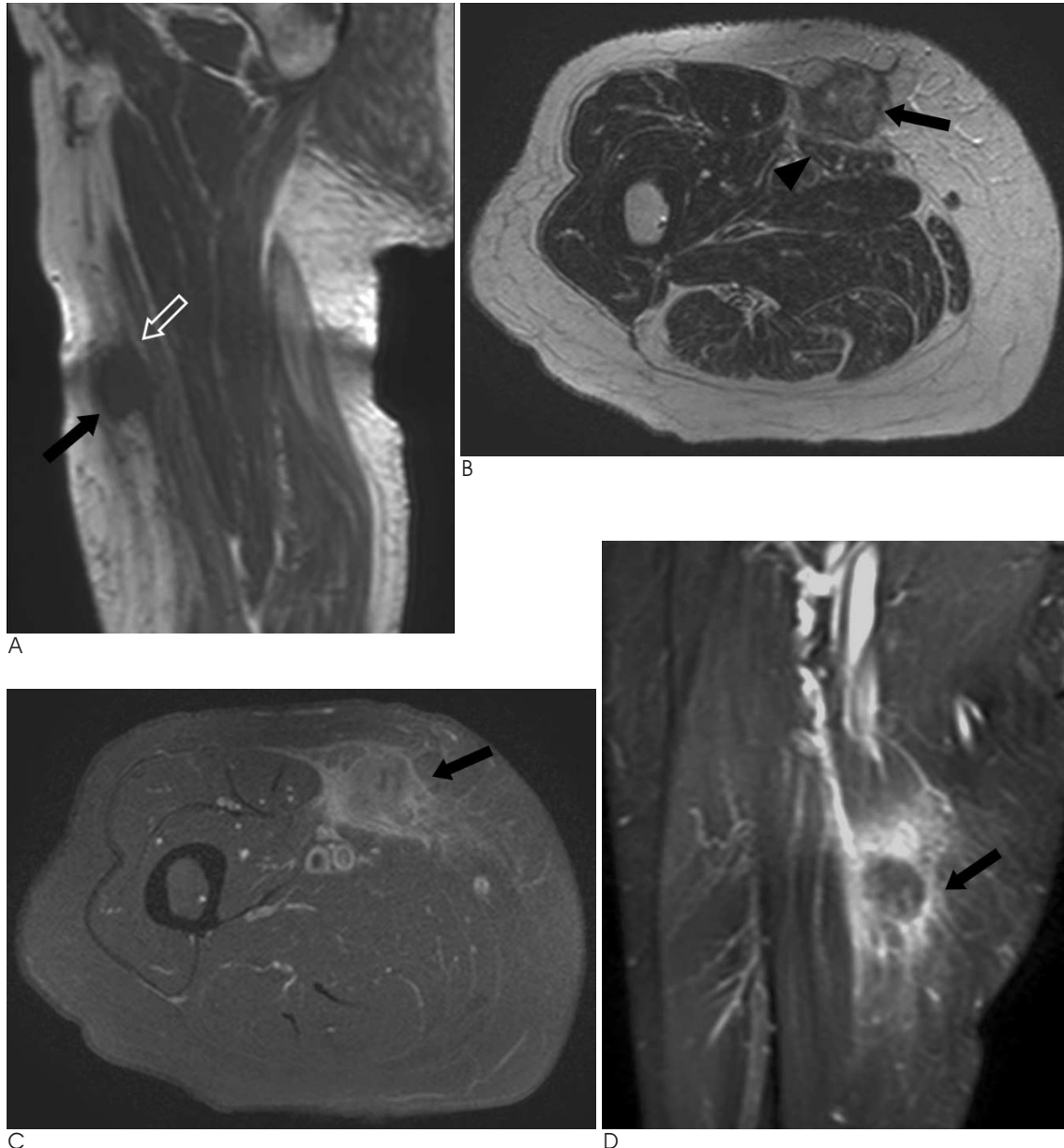


Fig. 1. A. A sagittal T1-weighted spin-echo MR image shows a round, partially ill-margined hypointense mass (arrow) in the right thigh. Note the focal fascial thickening (open arrow) that is visualized at the interface between the mass and the sartorius muscle. B. An axial T2-weighted MR image shows the mass (arrow) is located mainly within the subcutaneous fatty tissue with heterogeneous intermediate to high signal intensity. Note the indistinct interface between the mass and compressed sartorius muscle (arrowhead). C. On an axial GD-DTPA-enhanced MR image, the mass (arrow) is enhanced heterogeneously and has a focal poor enhancing area related with tumor necrosis in the center of the mass. Focal enhancement of the fascial plane of the sartorius muscle indicates invasion. D. On a coronal GD-DTPA-enhanced MR image, adjacent soft tissue is strongly enhanced including the fascial plane; the enhancement is probably related to peritumoral edema and invasion. Note the mass (arrow) with a lobulated border, central necrosis and relatively extensive peritumoral enhancement.

Subsequent MRI demonstrated the presence of a lobulated infiltrative mass with a poorly defined margin in the anterior aspect of the right thigh. The mass was located mainly within the subcutaneous tissue with partial invasion of the adjacent right sartorius muscle and measured $3.7 \times 2.6 \times 2.0$ cm. The mass was seen with low signal intensity (SI) on a T1-weighted image (T1WI) (TR = 544.7 ms, TE = 25 ms) and high to intermediate SI on a T2-weighted image (T2WI) (TR = 4553 ms, TE = 100 ms) (Fig. 1A, B). After injection of gadolinium-diethylenetriamine penta-acetic acid (Gd-DTPA), the subcutaneous mass showed heterogeneous enhancement with concomitant surrounding soft tissue and fascial plane enhancement (Fig. 1C, D). The preoperative differential diagnosis included a soft tissue sarcoma such as a malignant fibrous histiocytoma (MFH); a soft tissue metastasis was also included for the differential diagnosis in consideration of the medical history of the patient.

After an excisional biopsy was performed, a mass with multifocal hemorrhage was identified and was found to have considerably infiltrated the adjacent soft tissue. A histopathological examination confirmed the mass as a metastatic, infiltrating, poorly differentiated adenocarcinoma (Fig. 2A, B). The mass showed similar histopathological features as the previous gastric biopsy specimen. The patient underwent adjuvant chemotherapy, and there has been no further evidence of a newly appeared distant metastasis or local tumor recurrence.

Discussion

Soft tissue is defined as the supportive tissue of various organs and as an extraskeletal, nonepithelial structure except for lymphohematopoietic tissue. Soft tissue consists of fibrous connective tissue, adipose tissue, skeletal muscle, blood/lymph vessels and the peripheral nervous system and is mainly derived from the mesoderm with a neuroectodermal contribution. In the radiological clinical imaging practice, benign conditions generally represent approximately 70% of soft tissue lesions, and are seen with a 50–100 times higher incidence than malignancies in pathological series (3, 4). Among the malignancies, soft tissue metastases have been reported to be quite rare because of the strong resistance of soft tissue as a site for a metastasis in spite of a large volume that constitutes nearly 40% of the total body mass (5). Thus, it has not been common to include a soft tissue metastasis as part of the ordinary differential diagnosis for a solitary soft tissue mass, even if the patient had a history of primary cancer.

For relatively uncommon soft tissue metastases, skeletal muscle involvement is more common than subcutaneous involvement by a ratio of nearly 4:1 as reported in previously described cases. However, Damron et al. reported the ratio just exceeded 1.5:1 in 30 patients with soft tissue metastases. These investigators speculated that the ratio difference was probably related to the tendency of subcutaneous metastases to be pain-free as

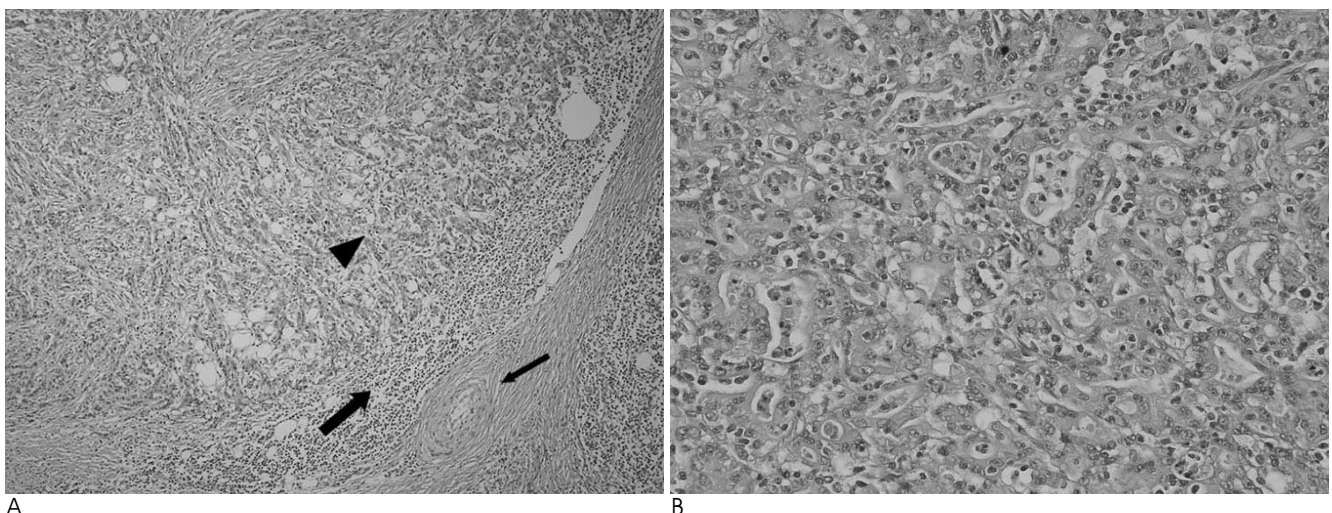


Fig. 2. A. Microscopic appearances of the metastatic gastric adenocarcinoma (arrowhead) in the subcutaneous fat of the right anterior thigh are shown. There is peritumoral inflammatory cell infiltration (large arrow) and a desmoplastic reaction secondary to fascial invasion (small arrow). Hematoxylin and eosin staining; original magnification, $\times 100$
 B. Microscopic appearances of the metastatic gastric adenocarcinoma are shown (area of the arrowhead in A). Hematoxylin and eosin staining; original magnification, $\times 400$

compared to painful skeletal metastases. The lack of pain associated with subcutaneous metastases has resulted in less clinical attention of the lesions, masking the detection of subcutaneous metastases with an underestimation of the true incidence (6). Under these circumstances, imaging findings of subcutaneous metastases have been rarely presented.

Kauffman et al. (7) have suggested that metastatic spread of an adenocarcinoma to the skin and subcutaneous tissue could be due to lymphatic and hematogenous spread. Metastatic spread was believed to be secondary to intralymphatic tumor spread initially and spread by both intralymphatic and intravascular routes. Retrograde tumor spread producing capillary congestion combined with partial vascular and lymphatic obstruction by tumor cells could result in prominent perilesional edema.

Multiple imaging modalities including CT, MRI, ultrasonography, and gallium scintigraphy have been used for the diagnosis of soft tissue lesions. Among these diagnostic tools, MRI is the most useful modality for the diagnosis and decision of treatment planning to define the relationship between a tumor and adjacent anatomic structures, such as compartment boundaries, nerves, vessels and muscle with relatively high accuracy (2, 8). The differential diagnosis based on MR images of this case included a soft tissue sarcoma such as a malignant fibrous histiocytoma, nodular fasciitis, hematoma and soft tissue infection. The clinical manifestation and medical history of the patient lowered the possibility of a hematoma and infectious condition. It was difficult to distinguish between a soft tissue sarcoma and metastasis from the MR imaging features.

In previous studies that have considered muscular metastases from various primary origins including gastric carcinoma (9, 10), MR imaging features of a metastatic carcinoma have closely resembled features of soft tissue sarcomas in many respects, but an extensive peritumoral enhancement pattern was the most common feature for a metastatic carcinoma. Kondo et al. (1) reported that a non-hemorrhagic soft-tissue sarcoma has less

necrosis, peritumoral edema and lobulation; these features help to differentiate a non-hemorrhagic soft-tissue sarcoma from an intramuscular metastasis. Similar to a muscular metastasis, the subcutaneous metastasis in this case also showed prominent peritumoral edema as seen on gadolinium-enhanced images. We suggest that prominent peritumoral enhancement can be one characteristic feature favoring a subcutaneous metastasis rather than a primary mass, especially in patients with a history of a previous primary cancer.

In conclusion, a solitary metastasis should be included in the possible differential diagnosis of a soft tissue mass in patients with a history of cancer, especially when MR images show the presence of a lobulated, necrotic mass with prominent peritumoral edema.

References

1. Kondo S, Onodera H, Kan S, Uchida S, Toguchida J, Imamura M. Intramuscular metastasis from gastric cancer. *Gastric Cancer* 2002;5:107-111
2. Amano Y, Kumazaki T. Gastric carcinoma metastasis to calf muscles: MR findings. *Radiat Med* 1996;14:35-36
3. *General considerations*. In Enzinger FM, Weiss SW. *Soft tissue tumors*. 3rd ed. St. Louis: Mosby Year Book, 1995;1-16
4. Sundaram M, Sharafuddin MJ. MR imaging of benign soft-tissue masses. *Magn Reson Imaging Clin N Am* 1995;3:609-627
5. Kransdorf MJ, Murphey MD. Radiologic evaluation of soft-tissue masses: a current perspective. *AJR Am J Roentgenol* 2000;175:575-587
6. Damron TA, Heiner J. Distant soft tissue metastases: a series of 30 new patients and 91 cases from the literature. *Ann Surg Oncol* 2000;7:526-534
7. Kauffman LC, Sina B. Metastatic inflammatory carcinoma of the rectum: tumor spread by three routes. *Am J Dermatopathol* 1997;19:528-532
8. Williams JB, Youngberg RA, Bui-Mansfield LT, Pitcher JD. MR imaging of skeletal muscle metastases. *AJR Am J Roentgenol* 1997;168:555-557
9. Tuoheti Y, Okada K, Osanai T, Nishida J, Ehara S, Hashimoto M. Skeletal muscle metastases of carcinoma: a clinicopathological study of 12 cases. *Jpn J Clin Oncol* 2004;34:210-214
10. Stoller DW, Steinkirchner TM, Johnston JO. *Bone and soft-tissue tumors*. In Stoller DW. *Magnetic resonance imaging in orthopaedics and sports medicine*. 2nd ed. Philadelphia: Lippincott, 1997:1232-1234

위선암의 피하조직에 단독전이한 1예의 자기공명영상소견¹

¹서울의대 영상의학교실

²분당서울대병원 영상의학과

³분당서울대병원 병리과

⁴분당서울대병원 정형외과

김정임 · 최정아^{1,2} · 정진행³ · 오주한⁴ · 최자영 · 홍성환 · 강홍식^{1,2}

피하조직은 위암 전이의 부위로는 예외적인 곳이다. 본문에서 우리는 위암환자에서 피하조직에 단독 전이된 1예를 자기공명영상소견과 보고하고자 한다.