

Double Minimal Incision Release for Carpal Tunnel Syndrome: A Comparative Study to the Standard Open Technique

Eun Ho Shin, Yeop Na,
Tong Joo Lee

Department of Orthopedic Surgery, Inha
University School of Medicine, Incheon, Korea

Received: March 29, 2017

Revised: [1] May 6, 2017
[2] May 28, 2017

Accepted: May 29, 2017

Correspondence to: Tong Joo Lee
Department of Orthopedic Surgery, Inha
University Hospital, 27 Inhang-ro, Jung-gu,
Incheon 22332, Korea
TEL: +82-32-890-3043
FAX: +82-32-890-3047
E-mail: TJLEE@inha.ac.kr

*This paper was supported by Inha University
research grant.

This is an Open Access article distributed under the terms
of the Creative Commons Attribution Non-Commercial
License (<http://creativecommons.org/licenses/bync/3.0/>) which permits unrestricted noncommercial use,
distribution, and reproduction in any medium, provided
the original work is properly cited.

Purpose: A minimally invasive surgical technique has been introduced to treat carpal tunnel syndrome that causes less pain, minimal scarring, and a rapid recovery. This study was designed to evaluate the safety and effectiveness of the double minimal incision release compared with the open surgery technique.

Methods: A study was performed on 175 cases in 111 patients who were operated on for carpal tunnel syndrome from January 2010 to December 2014. The patients were classified into 2 groups according to the type of surgical technique: 82 cases underwent standard open surgery in group A and 93 cases underwent double minimal incision release in group B. Grip strength and postoperative pain were evaluated 4 and 8 weeks and 6 and 12 months after surgery, and the period of numbness and time needed to resume normal activities were investigated.

Results: Group B patients showed better outcomes during the 2 first months after surgery than those of group A patients in numbness, pain, stiffness ($p<0.05$), less scar pain and tenderness ($p<0.001$), and shorter time needed to resume normal activities. However, no differences in these parameters were observed between the 2 groups after 6 months ($p>0.05$).

Conclusion: Double minimal incision release offered better clinical outcomes until 2 months after surgery compared to the standard open surgery technique and reduced incipient postoperative pain and allowed for earlier resumption of normal activities.

Keywords: Carpal tunnel syndrome, Minimally invasive surgical procedures

INTRODUCTION

Open carpal tunnel release is one of the most commonly performed procedures in patients who have idiopathic carpal tunnel syndrome^{1,2}. Most hand surgeons have been trained to perform open release of the transverse carpal ligament under direct visualization with a longi-

tudinal incision. Although excellent results have been reported, some authors have suggested that scar tenderness, pain in the thenar or hypothenar area (pillar pain), and persistent weakness may occur frequently after standard open procedures³⁻⁸. Thus, minimally invasive surgical techniques, such as the limited open single incision and an approach through the flexor carpi radialis, have

become widespread to treat carpal tunnel syndrome. Minimally invasive techniques include endoscopic carpal tunnel release (ECTR) and double minimal incision release. Nazzi et al.⁹ introduced a minimally invasive surgical technique for carpal tunnel release, which has been attributed to less surgical trauma, thereby reducing pillar pain and postoperative scar tenderness and providing better grip strength and more rapid return to work. However, surgeons considering a minimally invasive surgical technique should be aware of the complications, such as nerve injury, vascular injury, or incomplete release. Technical improvements in endoscopic techniques and subsequent reports have demonstrated fewer complications¹⁰. Many studies have compared the results of open carpal tunnel release and ECTR procedures; however, only a few studies have described the results of open carpal tunnel release against a minimally invasive technique. The purpose of the present study was to compare results of the double minimal incision technique with those of open carpal tunnel release using validated outcome questionnaires, standardized functional tests, and physical measurements.

MATERIALS AND METHODS

This was a retrospective cross-sectional clinical trial conducted from January 2010 to December 2014 at Inha University Hospital. We considered the clinical diagnosis of carpal tunnel syndrome based on the presence of three or more of the following factors: (1) history of recurrent

or persistent paresthesia in the median nerve distribution; (2) worsening of symptoms (numbness, weakness, wrist pain, and stiffness); (3) nocturnal awakening with paresthesia; (4) presence of a positive Tinel's and/or Phalen's sign on physical examination; and (5) absence of a response to nonsurgical treatments (night splint, non-steroidal anti-inflammatory drugs, or steroid injections) for at least 6 months since the start of symptoms in patients >50 years old. Patients who entered the study were evaluated with electrodiagnostic studies.

In total, 111 patients with carpal tunnel syndrome were enrolled in this study. Of them, 47 had unilateral involvement and 64 were bilateral cases. Therefore, the study was comprised of 175 hands. Both methods were explained to each patient. The patients were divided into 2 groups and underwent one of the two procedures for carpal tunnel release surgery. A longitudinal incision was used in 53 patients (82 hands), designated as group A. Fifty-eight patients (93 hands) in group B were treated with the double minimal incision technique described below. Mean age, female-to-male ratio, and dominance of the operated hand were similar between the groups and electrodiagnostic studies were performed on all wrists prior to surgery (Table 1). This study protocol was approved by the Institutional Review Board of Inha University Hospital (No. 2016-08-019).

1. Assessment

We conducted the surgery and evaluated the outcomes on an outpatient basis. Clinical assessment was made

Table 1. Demographics of patients grouped into the standard open surgery technique (group A) and the double minimal incision release (group B)

Demographics	Group A	Group B	p-value
No. (procedure)	82	93	-
Unilateral (hands)	24	23	-
Bilateral (hands)	29	35	-
Age (yr)	59.5±13.8	59.6±9.7	0.825
Ratio (female:male)	49:4	52:6	0.681
Right:left	43:39	44:49	0.376
Electrodiagnostic study			
Sensory latency (msec)	4.7±1.37	4.9±1.54	0.731
Motor latency (msec)	5.7±1.24	5.8±1.38	0.508

Values are presented as number or mean±standard deviation.

retrospectively at every outpatient visit after patients subjective symptoms consulting Boston Carpal Tunnel Questionnaire; numbness, nocturnal pain, wrist and hand pain, weakness, and stiffness were investigated. Patients were examined for subjective symptoms at the every outpatient visit and were considered positive if there was symptom. The visual analogue scale (VAS) were completed postoperatively and diagnostic tests (Tinel's and Phalen's tests) were performed. Pillar tenderness was measured with a 2.0 kg plunger for 30 seconds at the level of the distal wrist crease (Fig. 1). Hand grip strength was measured with a Jamar dynamometer (Fabrication Enterprises, Elmsford, NY, USA). Return to work was the mean time to perform normal daily life activities without subjective discomfort after surgery. We also checked nerve or vascular injury and persistent neurological symptoms as complications.

These tests and examinations were repeated 2, 4, and 8 weeks and 3, 6, and 12 months postoperatively. We also evaluated the patients' satisfaction levels with their scars 12 months postoperatively at the outpatient clinic in connection with the reduced size of the incision.



Fig. 1. Measurement of pillar tenderness.

2. Statistics

We compared the outcomes of the 2 groups with analysis of covariance at each postoperative interval. The data were analyzed with SPSS ver. 17.0 (SPSS Inc., Chicago, IL, USA). A p-value less than 0.05 was considered significant. The chi-square test was used to assess numbness, nocturnal pain, wrist and hand pain, thenar atrophy, the Tinel's sign, and the Phalen's test. Linear-by-linear association was employed to assess the VAS scores, and the t-test was used to evaluate grip strength and the days required for the patient to return to work.

3. Operative technique

The operation was performed under general anesthesia or regional anesthesia (brachial plexus block) using a pneumatic tourniquet.

1) Standard open surgery technique

The transverse carpal ligament was exposed through a short longitudinal incision along the axis of the ring finger (Fig. 2). Neither the motor branch of the median nerve nor the palmar cutaneous branch was routinely

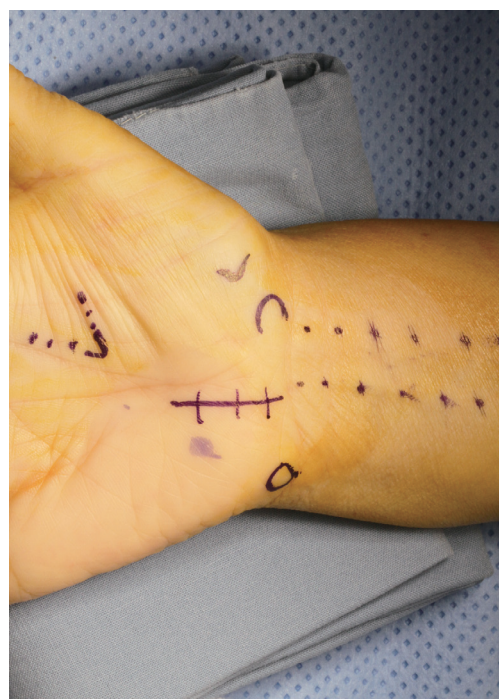

Fig. 2. Skin incision of standard open technique.

identified. The carpal tunnel was decompressed from the antebrachial fascia to the distal edge of the transverse carpal ligament and any pathological features were noted and investigated. The skin was closed after releasing the tourniquet and performing meticulous hemostasis.

2) Double minimal incision release

Two skin incisions were used to decompress the carpal tunnel (Fig. 3); thus, leaving a 2-cm bridge of skin intact at the base of the palm. First, a 1-cm distal incision (A in Fig. 3) was made longitudinally along the proximal portion of median crease to expose the distal margin of the transverse carpal ligament, which was divided under direct vision. Secondly, a 1-cm incision was made transversely (B in Fig. 3) at the wrist crease over the palmaris longus tendon. Care was taken to avoid injury to the median palmar cutaneous nerve. We retracted the palmaris longus tendon radially using a skin hook. Blunt dissection with a freer (scalpel) was performed initially toward the distal incision site between the skin and transverse carpal ligament to make sufficient room for introducing sharp Metzenbaum scissors. The area beneath the transverse carpal ligament was probed with the freer to protect the median nerve. Then, the proximal two-thirds of the transverse carpal ligament was released by cutting with

sharp Metzenbaum scissors. The remaining distal part of the transverse carpal ligament was released through the distal incision site.

We introduced mosquito forceps along the median nerve beneath the incised transverse carpal ligament to confirm complete release and then palpated with the mosquito forceps over the skin from proximally to distally (Fig. 4). All patients were discharged home either on the same day or the following day. Wool bandages were retained for 4–7 days.

RESULTS

1. Electrodiagnostic studies

Mean sensory latency in group A was 4.7 milliseconds, and mean motor latency was 5.7 milliseconds preoperatively. Mean sensory latency in group B was 4.9 milliseconds, and mean motor latency was 5.8 milliseconds ($p>0.05$).

2. Outcome measurements

1) Clinical symptoms

No differences in numbness, nocturnal pain, wrist and

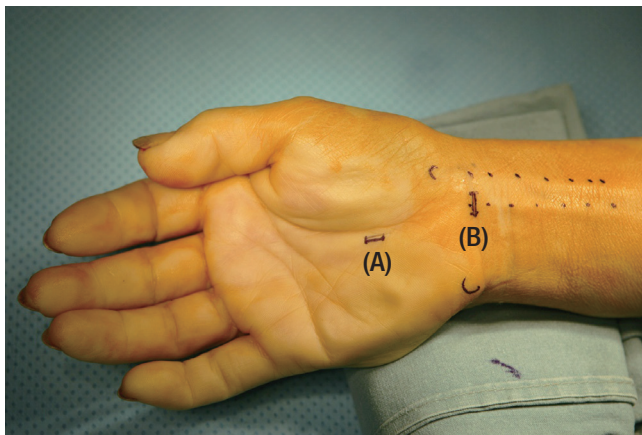


Fig. 3. Skin incision of double minimal incision technique. A 1-cm distal incision (A) was made longitudinally along the proximal portion of median crease to expose the distal margin of the transverse carpal ligament, which was divided under direct vision. And a 1-cm incision (B) was made transversely at the wrist crease over the palmaris longus tendon.

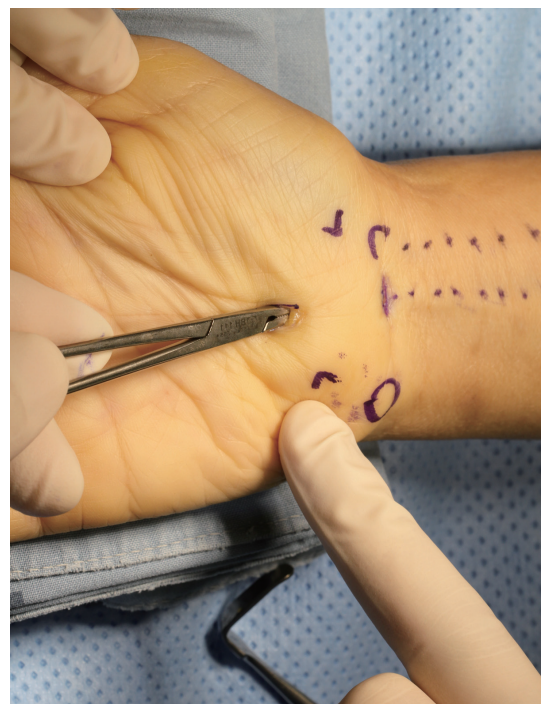

Fig. 4. Confirmation of complete release of transverse carpal ligament with curved mosquito forceps.

hand pain, weakness and stiffness were observed pre-operatively between groups A and B (Table 2). Group B had significantly less numbness, wrist and hand pain, and stiffness 2, 4, and 8 weeks postoperatively than those in group A ($p < 0.05$). However, these differences disappeared ≥ 3 months after surgery. There was no difference in nocturnal pain and weakness between 2 groups.

2) Visual analog scale

Preoperative VAS scores were not different between groups A and B (Table 3). Both groups had a gradual decrease in VAS score. Group B showed significantly better results after 2, 4, and 8 weeks than those in group

A ($p < 0.05$). However, these differences disappeared ≥ 3 months after surgery.

3) Tinel's sign/Phalen's test

Positive Tinel's and Phalen's test results were observed in approximately 50% of group A and B patients 2 weeks postoperatively. No differences were observed between the 2 groups after 2 weeks.

4) Pillar tenderness/grip strength

Only 5.3% (hands, 5) of the double minimal incision release group complained of pillar tenderness with loads of 2.0 kg over the carpal tunnel 2 weeks after surgery,

Table 2. Interval change of numbness, wrist and hand pain, and stiffness between the standard open surgery technique (group A) and the double minimal incision release (group B)

Clinical symptom (No. of hands)	Presurgery	Postsurgery					
		2 Week	4 Week	8 Week	3 Month	6 Month	12 Month
Numbness							
Group A	76	14	6	6	3	3	1
Group B	78	2	1	1	2	2	1
p-value	>0.05	<0.001	0.035	0.035	>0.05	>0.05	>0.05
Wrist and hand pain							
Group A	42	21	10	6	2	2	0
Group B	45	5	1	1	5	2	1
p-value	>0.05	<0.001	0.002	0.035	>0.05	>0.05	>0.05
Stiffness							
Group A	25	11	9	9	4	2	2
Group B	19	2	2	2	6	2	3
p-value	>0.05	0.005	0.016	0.016	>0.05	>0.05	>0.05

Table 3. Interval change of VAS score and pillar tenderness between the standard open surgery technique (group A) and the double minimal incision release (group B)

Variable	Presurgery	Postsurgery					
		2 Week	4 Week	8 Week	3 Month	6 Month	12 Month
VAS (score)							
Group A	7.8	4.3	3.3	3.2	1.3	0.9	0.3
Group B	7.5	2.1	1.1	1.1	1.0	1.1	0.4
p-value	>0.05	<0.001	<0.001	<0.001	>0.05	>0.05	>0.05
Pillar tenderness (No. of hands)							
Group A	75	24	12	9	2	2	2
Group B	80	5	2	2	2	2	2
p-value	>0.05	<0.001	<0.001	<0.001	>0.05	>0.05	>0.05

VAS, visual analogue scale.

whereas 29.2% (hands, 24) of the minimal open group complained of pillar tenderness. Mean preoperative grip strength was 13.2 kg in the double minimal incision procedure group and 13.8 kg in the open-release group. Grip strength had decreased significantly in both groups to 10.8 kg ($p<0.05$) 2 weeks after surgery in the double minimal incision procedure group and to 10.8 kg in the open-release group ($p>0.05$).

5) Return to work and cosmetic result

The median time for patients to return to work was 38 days (range, 15–77 days) in the open-release group compared with 25 days (range, 8–60 days) in the double minimal incision release group ($p<0.01$). The scars in the double minimal incision release group remained significantly less tender than those in the open-release group until 2 months postoperative. Both groups had equally mild persistent scar tenderness 1 year after surgery.

Patients who underwent the double minimal incision procedure had better cosmetic satisfaction (satisfaction rate, 95%) than those in the open-release group. They were questioned at the outpatient clinic for their satisfaction/dissatisfaction with the reduced size of the incision scar.

6) Complication

No major nerve or vascular injury occurred in any patient. However, 3 patients developed complications. Symptoms consistent with reflex sympathetic dystrophy, including redness, swelling, and sweating occurred in 2 patients in the open-release group. The symptoms resolved in 1 patient after physical therapy. The symptoms remained in the other patient, and a regular therapy program was required. Two patients finally returned to regular work. One patient in the open release group required revision surgery due to long-lasting symptoms from a hematoma in the surgical lesion.

DISCUSSION

Carpal tunnel syndrome is one of the most common compressive neuropathies of the upper limbs and re-

quires conservative treatment and occasionally carpal tunnel release surgery. Different surgical techniques can be used and both open techniques and ECTR are employed.

Most surgeons use a short, continuous, curved incision directly over the carpal tunnel for decompression and do not routinely look for the palmar cutaneous branch of the median nerve. Taleisnik¹¹ recommended a skin incision on the ulnar side of the axis of the ring finger, and damage to the branches of the palmar cutaneous nerve can be avoided if the skin incision is made in the axis of the ring finger. However, these incisions leave a scar in the pressure-bearing area at the base of the palm and may contribute to symptoms in a heavy manual labor worker. Previous studies have suggested that open carpal tunnel release is associated with considerable morbidity, including prolonged tenderness of the scar and grip weakness for as long as 3–6 months after the operation^{3,4,6}.

Chow¹² introduced an endoscopic technique to decompress the carpal tunnel, which allows rapid recovery. Early results are satisfactory with reduced scarring and postoperative pain. Trumble et al.¹³ compared results from open and endoscopic surgeries techniques. In their evaluation of satisfaction level, symptomatic and functional improvement after surgery was greater during 3 months in patients who received the endoscopic technique than in those who underwent open surgery. However, this technique requires specialized, expensive equipment, and is difficult to perform. The ulnar nerve, digital nerves, superficial palmar arch, and the motor branch of the median nerve may be damaged by the endoscopic blade^{5,10,12}. Thus, safety of the endoscopic technique has been a major concern, but few complications occur after learning the technique¹³.

The double minimal incision technique has the various advantages of an endoscopic procedure but also has some disadvantages. The double-incision technique is relatively easy to perform and allows rapid postoperative recovery¹⁴. This technique did not result in a higher risk of postoperative complications, expense, or increase in surgical time compared to the single-incision technique^{9,15}.

Our double minimal incision release was easy and safe for carpal tunnel release and resulted in good-to-excellent clinical outcomes. No special equipment is necessary, and no extended learning curve for the use of equipment are needed, thereby making the learning curve short. This procedure allows the distal portion of the transverse carpal ligament to be divided under direct vision to avoid any neurovascular damage. In addition, this procedure has the advantages of during endoscopic release. The pressure-bearing area is protected by leaving an intact bridge of skin at the base of the palm and it does not divide the palmaris brevis muscle or the palmaris fascia. Thus, our group B patients had less scar tenderness and greater symptom relief for the first 8 weeks following the surgery.

One of the most important functional outcomes is the interval between the operation and the patient's resumption of daily living and work activities. In a previous study, industrial employees lost an average of 54 days of work after open carpal tunnel release¹⁶. In contrast, Chow¹⁶, who retrospectively studied the results of ECTR in 456 patients, noted that 269 patients (59%) returned to normal activity and work after 2 weeks and 392 (86%) returned after 4 weeks. As in previous studies of ECTR, our patients who underwent the double minimal incision release procedure returned to work earlier (mean, 25 days after the operation) than those who underwent open release (mean, 38 days after the operation). There was no loss to follow up (111 patients, 176 hands) during the 12-month study period. Our technique led to less pain due to the minimal incision and better cosmetic satisfaction because of little scarring. Moreover, the double minimal incision procedure does not require expensive equipment and can decrease costs because the patient returns to work in a shorter period of time.

Several limitations of this study should be mentioned. We were unable to employ any self-reported questionnaires or systemic interviews to evaluate the patients' outcome preoperatively. Moreover, we did not compare the groups regarding factors that should be pair-matched, such as gender, age, or profession.

CONCLUSION

We conclude that the double minimal incision procedure is an easy, safe, and cost-effective method for carpal tunnel syndrome and provides better clinical outcome in the first 2 months following treatment than open carpal tunnel release.

CONFLICT OF INTEREST

No potential conflict of interest relevant to this article was reported.

REFERENCES

1. Brown RA, Gelberman RH, Seiler JG 3rd, et al. Carpal tunnel release: a prospective, randomized assessment of open and endoscopic methods. *J Bone Joint Surg Am.* 1993;75:1265-75.
2. Phalen GS. The carpal-tunnel syndrome: seventeen years' experience in diagnosis and treatment of six hundred fifty-four hands. *J Bone Joint Surg Am.* 1966;48:211-28.
3. Kulick MI, Gordillo G, Javid T, Kilgore ES Jr, Newmayer WL 3rd. Long-term analysis of patients having surgical treatment for carpal tunnel syndrome. *J Hand Surg Am.* 1986;11:59-66.
4. Kuschner SH, Brien WW, Johnson D, Gellman H. Complications associated with carpal tunnel release. *Orthop Rev.* 1991;20:346-52.
5. Seiler JG 3rd, Barnes K, Gelberman R. Endoscopic carpal tunnel release: an anatomic study of the two-incision method in human cadavers. *J Hand Surg Am.* 1992;17:996-1002.
6. Seradge H, Seradge E. Pisto-triquetral pain syndrome after carpal tunnel release. *J Hand Surg Am.* 1989;14:858-62.
7. MacDonald RI, Lichtman DM, Hanlon JJ, Wilson JN. Complications of surgical release for carpal tunnel syndrome. *J Hand Surg Am.* 1978;3:70-6.
8. Elsharif M, Papanna M, Helm R. Long-term follow up outcome results of Knifelight carpal tunnel release and conventional open release following a departmental randomized controlled trial: a prospective study. *Pol Orthop Traumatol.* 2014;79:67-70.
9. Nazzi V, Franzini A, Messina G, Broggi G. Carpal tunnel

- syndrome: matching minimally invasive surgical techniques: technical note. *J Neurosurg.* 2008;108:1033-6.
10. Agee JM, Peimer CA, Pyrek JD, Walsh WE. Endoscopic carpal tunnel release: a prospective study of complications and surgical experience. *J Hand Surg Am.* 1995;20:165-71.
11. Taleisnik J. The palmar cutaneous branch of the median nerve and the approach to the carpal tunnel: an anatomical study. *J Bone Joint Surg Am.* 1973;55:1212-7.
12. Chow JC. Endoscopic release of the carpal ligament: a new technique for carpal tunnel syndrome. *Arthroscopy.* 1989;5:19-24.
13. Trumble TE, Diao E, Abrams RA, Gilbert-Anderson MM. Single-portal endoscopic carpal tunnel release compared with open release: a prospective, randomized trial. *J Bone Joint Surg Am.* 2002;84:1107-15.
14. Macdermid JC, Richards RS, Roth JH, Ross DC, King GJ. Endoscopic versus open carpal tunnel release: a randomized trial. *J Hand Surg Am.* 2003;28:475-80.
15. Masear VR, Hayes JM, Hyde AG. An industrial cause of carpal tunnel syndrome. *J Hand Surg Am.* 1986;11:222-7.
16. Chow JC. Endoscopic release of the carpal ligament for carpal tunnel syndrome: 22-month clinical result. *Arthroscopy.* 1990;6:288-96.

수근관증후군을 위한 이중 최소 절개 감압술: 개방적 감압술 기법에 대한 비교 연구

신은호 · 나엽 · 이동주

인하대학교 의과대학 정형외과

목적: 최소 절개를 통한 수근관 유리술은 적은 통증, 흉터 및 조기 회복이 가능한 수근관증후군의 치료법으로 소개되어 왔다. 본 연구는 개방형 수근관 유리술과 이중 최소 절개 유리술의 안전성과 효율성을 비교하고자 한다.

방법: 2010년부터 2014년 12월까지 수근관증후군으로 수술을 시행한 환자 111명, 175예를 대상으로 분석하였다. 환자를 수술 기법에 따라 2그룹으로 나누고, 개방적 유리술을 받은 82예는 그룹A, 이중 최소 절개 유리술 받은 93예는 그룹B로 분류하였다. 수술 후 4주, 6주, 6개월, 1년에 수술 부위 무감각, 통증 및 악력을 평가하였고, 일상 생활 복귀 시간도 평가하였다.

결과: 수술 후 2개월까지 이중 최소 절개술을 받은 환자군에서 개방형 유리술 받은 환자 군보다 무감각, 통증, 경직에 대해 더 좋은 결과를 보였으며($p < 0.05$), 반흔부 통증과 압통이 적었고($p < 0.001$), 일상 생활 복귀 시간이 짧았다. 하지만 6개월 후에는 두 군간 유의한 차이는 없었다($p > 0.05$).

결론: 이중 최소 절개 유리술은 개방형 유리술 보다 수술 후 2개월까지 더 좋은 임상 결과를 보이고 부작용이 적어 조기 통증 감소 및 조기 일상 복귀를 가능하게 하는 효과적인 수술 기법이다.

색인단어: 수근관증후군, 이중 최소 절개 유리술, 개방형 수근관 유리술

접수일 2017년 3월 29일 **수정일** 1차: 2017년 5월 6일, 2차: 2017년 5월 28일

게재확정일 2017년 5월 29일

교신저자 이동주

인천광역시 중구 인항로 27

인하대학교 의과대학 정형외과

TEL 032-890-3043 **FAX** 032-890-3047

E-mail TJLEE@inha.ac.kr