

Synovial Chondromatosis of the Ulnocarpal Joint

Sung-Guk Kim

*Department of Orthopaedic Surgery, Daegu
Catholic University Medical Center, Daegu, Korea*

Synovial chondromatosis is a rare, benign and progressive metaplasia of the synovial membranes associated with the formation of cartilage in joints, tendon sheaths, or bursae. There are a few reports of synovial chondromatosis with wrist involvement. Here, we report a case of a 59-year-old woman with synovial chondromatosis of the ulnocarpal joint of the right wrist, with an 18-month follow-up and review of the literature.

Keywords: Wrist, Ulnocarpal joint, Synovial chondromatosis

Received: August 21, 2015

Revised: [1] September 12, 2015
[2] October 8, 2015

Accepted: October 10, 2015

Correspondence to: Sung-Guk Kim
Department of Orthopaedic Surgery,
Daegu Catholic University Medical Center,
33 Duryugongwon-ro 17-gil, Nam-gu,
Daegu 42472, Korea
TEL: +82-53-650-4276
FAX: +82-53-626-4272
E-mail: p10001@hanmail.net

This is an Open Access article distributed under the terms of the Creative Commons Attribution Non-Commercial License (<http://creativecommons.org/licenses/bync/3.0/>) which permits unrestricted noncommercial use, distribution, and reproduction in any medium, provided the original work is properly cited.

INTRODUCTION

Synovial chondromatosis is a rare, benign and progressive metaplasia of the synovial membranes associated with the formation of cartilage in joints, tendon sheaths, or bursae. Loose bodies are produced by detached metaplastic foci. Synovial chondromatosis is mostly monoarticular and commonly affects large joints, such as those involving the knee, hip, and shoulder. Few reports of

synovial chondromatosis with wrist involvement been reported. Here, we report a case of a 59-year-old woman with synovial chondromatosis of the right wrist, with an 18-month follow-up and review of the literature.

CASE REPORT

The patient was a 59-year-old, right-hand-dominant woman with a 20-year history of a palpable mass and

mild pain in her right wrist during pronation and supination of the forearm. The symptoms were progressively worsening, particularly with housework. The patient reported no trauma to the wrist and did not have any relevant family history.

On physical examination, the patient had tenderness on the dorsal aspect of the ulnocarpal joint. An approximately 2-cm sized mass was palpable on the dorsal and ulnar aspect of the wrist. On checking range of motion of the wrist, the patient showed 70° of flexion, 60° of extension, 60° of supination, 55° of pronation, 20° of radial deviation, and 10° of ulnar deviation of the wrist. The patient complained of dull pain during ulnar deviation of the wrist.

Plain radiographs showed loose bodies in the ulnocarpal joint and at the dorsoulnar aspect of the ulnocarpal joint (Fig. 1). Magnetic resonance imaging revealed an intrasynovial osseous mass and lateral deviation of the torn triangular fibrous cartilage, which is consistent with

synovial chondromatosis (Fig. 2).

At operation, the ulnocarpal joint was exposed through a small longitudinal incision between the extensor digiti quinti and the extensor carpi ulnaris. The posterolateral capsule of the ulnocarpal joint was protruded and hypertrophied. After an angular incision of the capsule, a movable, irregular and firm mass was felt inside the capsular tissue. The synovium was hypertrophied. There were a 2×2 cm sized round, lobulated mass and 2 osseous bodies in the ulnocarpal joint. Wide curettage of the synovium including the masses was done. The extensor carpi ulnaris tendon was left in situ. Abnormal osteophytes were found at the tip of the styloid process. The osteophytes of the styloid process were removed. The palmar radioulnar ligament was intact but the dorsal radioulnar ligament was not torn but slack not to cause the distal radioulnar joint instability. Small osseous bodies which had stuck into the triangular fibrous cartilage were debrided not to give the damage to the remained triangular fibrous car-

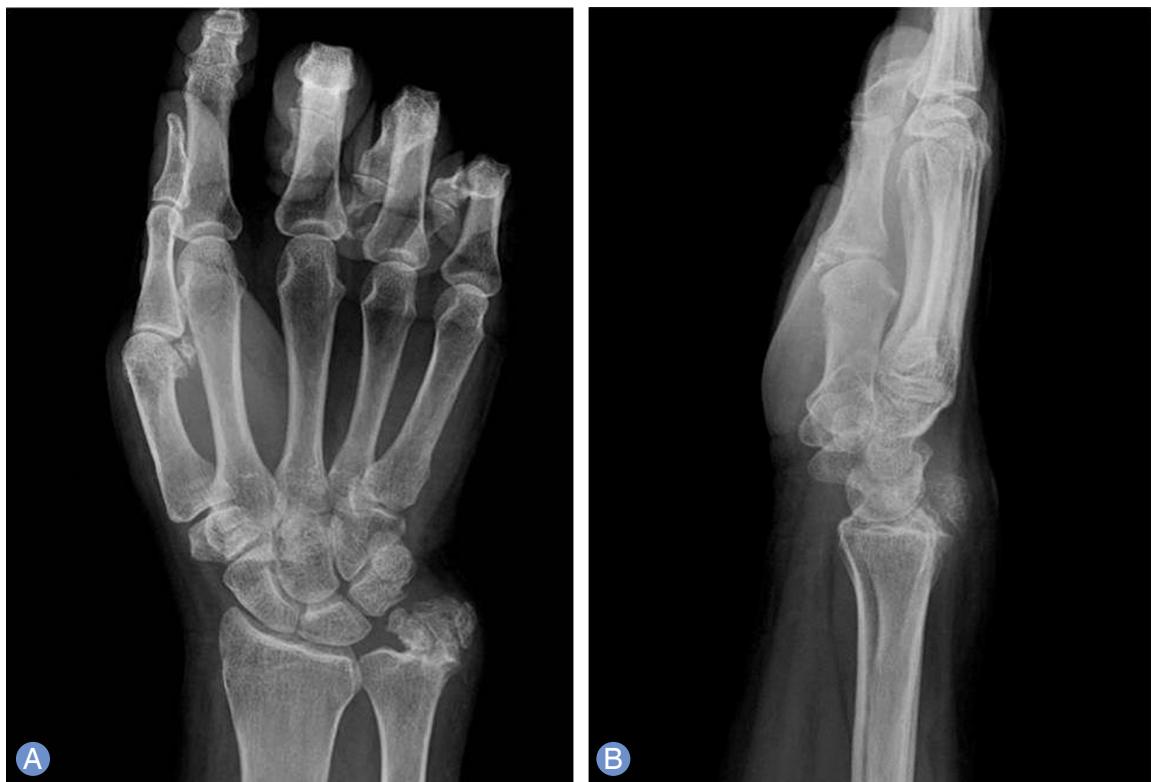

Fig. 1. Multiple osseocartilaginous masses can be observed in the ulnocarpal joint on an anteroposterior radiograph (A) and in the dorsal aspect of the wrist on a lateral radiograph (B).

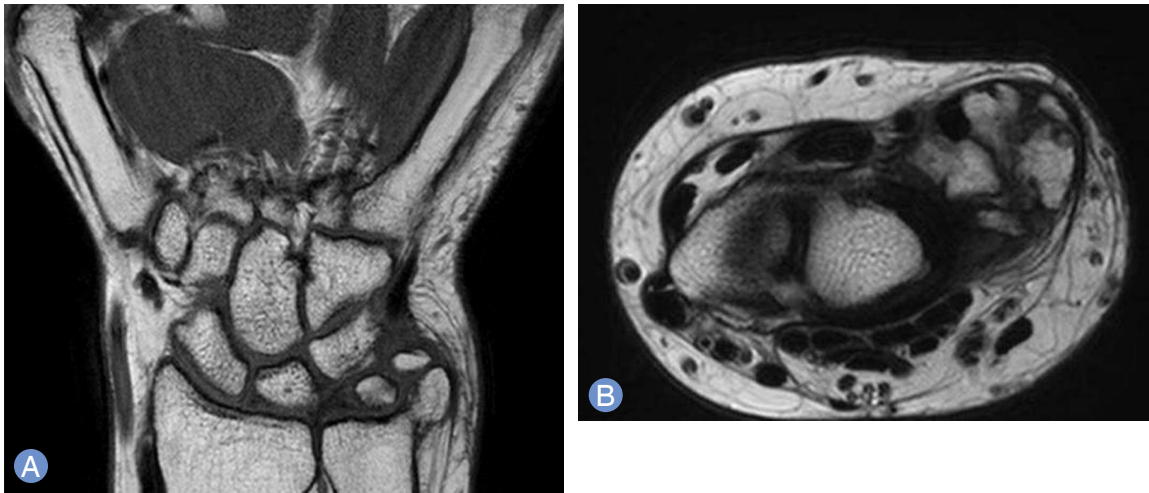

Fig. 2. T1-weighted coronal (A) and axial (B) images showing loose bodies in the ulnocarpal joint.

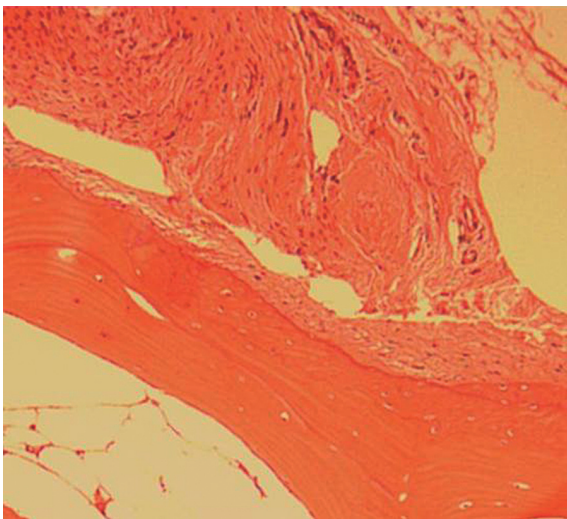


Fig. 3. Low power view reveals that a thick proliferating cartilaginous cap overlying poorly organizing cancellous bone (H&E, $\times 100$).

tilage, which was reattached to the capsule and the soft tissues around the ulnar styloid to keep the stability of the distal radioulnar joint. The deep of a triangular fibrous cartilage attached to the fovea of the ulna. The histopathologic report of the loose bodies and resected synovium revealed primary synovial chondromatosis (Fig. 3).

After 2 weeks of splint immobilization, the patient started active and passive range of motion. She returned to full wrist range of motion within 4 weeks of surgery. At the last follow-up, 18 months after surgery, there was no

pain, no motion deficit in the wrist, and no radiographic evidence of recurrent disease (Fig. 4).

DISCUSSION

Although synovial chondromatosis is known to affect large joints, such as those involving the hip, knee, elbow, shoulder and ankle, few reports of synovial chondromatosis with wrist involvement were reported¹⁻³. Our review of the literature revealed only 29 cases with wrist or hand involvement, especially only 4 cases with radiocarpal joint involvement¹⁻³. However, there was just one report of synovial chondromatosis with ulnotriquetral joint involvement except our case⁴.

The peak incidence of synovial chondromatosis of the wrist occurs in the third and fourth decade of life. There is no preference for the left or right hand⁵, but men are more frequently affected than women⁶. The clinical features of synovial chondromatosis include the gradual onset of pain, swelling of the joint, stiffness, degenerative arthritic change, clicking, and locking which are all due to loose bodies. Based on these clinical features, the differential diagnosis of synovial chondromatosis includes septic arthritis, chondrocalcinosis, rheumatoid arthritis, osteoarthritis, synovial chondrosarcoma, nonunion of the ulnar styloid and hereditary multiple exostoses⁵. Unlike synovial chondromatosis, the bony fragment is usu-

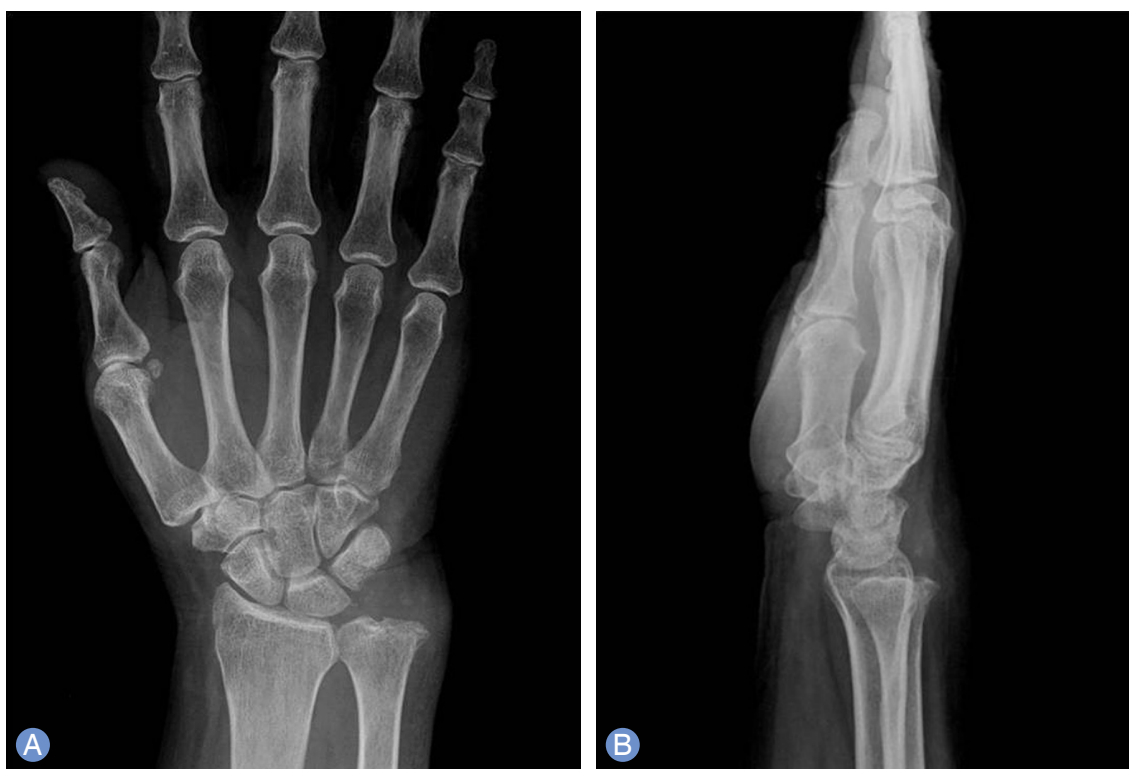

Fig. 4. Anteroposterior (A) and lateral (B) radiographs demonstrating no evidence of recurrent disease at 18 months post-operative follow-up.

ally single and has round marginal articulation with the proximal ulna and located extraarticular to the ulnocarpal joint in nonunion of the ulnar styloid⁷.

The standard treatment for synovial chondromatosis is the removal of loose bodies with synovectomy, either by arthroscopy or open surgery. The recurrence of synovial chondromatosis with wrist involvement has been reported from 13% to 17%^{5,8}. In a review of the literature by Loonen and Schuurman⁵, recurrence occurred 18 months postoperatively in early recurred case and also occurred 5 years postoperatively. Therefore, follow-up should be longer than 18 months to check for recurrence.

The malignant transformation of synovial chondromatosis into chondrosarcoma is unusual and occurs frequently in the knee joint⁹. We found no report involving the wrist, but only a few case reports of malignant transformation in the hand¹⁰. In both synovial chondromatosis and a differentiated chondrosarcoma, the patients have a similarly prolonged history of pain, swelling and decrease in range of motion. It is difficult to differentiate synovial

chondromatosis from well-differentiated chondrosarcoma due to their similar clinical and histologic features⁶. Inadequate surgical excision in synovial chondromatosis can lead to a high incidence of local recurrence, and over the course of time, malignant change may manifest⁶. A detailed preoperative investigation should be performed to increase the likelihood of complete excision. Computerized tomography will be helpful to confirm the location of the loose body. As with other joints in the body, Magnetic resonance arthrography of the wrist may also depict intraarticular loose bodies, osteochondral abnormalities, and abnormalities of the supporting soft-tissue structures including a triangular fibrous cartilage.

In summary, in the case of synovial chondromatosis, adequate surgery should be performed after a detailed preoperative investigation in order to decrease the probabilities of recurrence and malformation. Furthermore, follow-up should be at least 18 months to check for recurrence and malformation.

REFERENCES

1. Ballet FL, Watson HK, Ryu J. Synovial chondromatosis of the distal radioulnar joint. J Hand Surg Am. 1984;9:590-2.
2. Tudor A, Sestan B, Miletic D, et al. Synovial chondromatosis of the pisotriquetral joint with secondary osteoarthritis: case report. Coll Antropol. 2007;31:1179-81.
3. Lee SK, Choy WS, Lee KW, Bae KJ. Synovial chondromatosis of the radiocarpal joint. Orthopedics. 2008;31:811.
4. Inada Y, Fukui A, Maeda M, Tamai S, Inada M. Reconstruction of the triangular fibrocartilage complex after surgery for treatment of synovial osteochondromatosis of the distal radioulnar joint. J Hand Surg Am. 1990;15:921-4.
5. Loonen MP, Schuurman AH. Recurrent synovial chondromatosis of the wrist: case report and literature review. Acta Orthop Belg. 2005;71:230-5.
6. Wuisman PI, Noorda RJ, Jutte PC. Chondrosarcoma secondary to synovial chondromatosis: report of two cases and a review of the literature. Arch Orthop Trauma Surg. 1997;116:307-11.
7. Burgess RC, Watson HK. Hypertrophic ulnar styloid non-unions. Clin Orthop Relat Res. 1988;(228):215-7.
8. Reverte Vinaixa MM, Singh R, Monyart JM, et al. Wrist synovial chondromatosis: case report and literature review. Hand Surg. 2012;17:233-8.
9. Hallam P, Ashwood N, Cobb J, Fazal A, Heatley W. Malignant transformation in synovial chondromatosis of the knee? Knee. 2001;8:239-42.
10. Constant E, Harebottle NH, Davis DG. Synovial chondromatosis of the hand: case report. Plast Reconstr Surg. 1974;54:353-8.

척수근 관절에 발생한 윤활성 연골종증

김성국

대구가톨릭대학교 정형외과학교실

활액성 연골종증은 관절, 건막, 활액낭 등에서 연골을 형성과 연관된 윤활막의 드물고 양성이며 진행성 이형성 병변이다. 완관절에 이환된 활액성 연골종증은 몇 예가 보고되었다. 척수근 관절에 활액성 연골종증이 발생 후 수술적 치료를 받았고 18개월간 외래 추시 관찰하였던 59세 여자 환자를 문헌 고찰과 함께 보고 한다.

색인단어: 완관절, 척수근 관절, 윤활성 연골종증

접수일 2015년 10월 15일 수정일 1차: 2015년 11월 4일, 2차: 2015년 12월 3일

게재확정일 2015년 12월 10일

교신저자 김성국

대구광역시 남구 두류공원로 17길 33

대구가톨릭대학교 정형외과학교실

TEL 053-650-4276 FAX 053-626-4272

E-mail p10001@hanmail.net