

Identification of Double Compression Lesion of Ulnar Nerve after Cubital Tunnel Release

**Joon Yub Kim, Ho Il Kwak,
Jeong Hyun Yoo, Joo Hak Kim,
Dong Wook Sohn, Jae Ho Cho**

*Department of Orthopedic Surgery, Myongji
Hospital, Seonam University College of
Medicine, Goyang, Korea*

Received: May 27, 2015

Revised: [1] August 13, 2015
[2] August 28, 2015

Accepted: August 31, 2015

Correspondence to: Ho Il Kwak
Department of Orthopedic Surgery,
Myongji Hospital, Seonam University College
of Medicine, 55 Hwasu-ro 14 beon-gil,
Deogyang-gu, Goyang 10475, Korea
TEL: +82-31-810-5114
FAX: +82-31-969-0500
E-mail: khinael@naver.com

This is an Open Access article distributed under the terms
of the Creative Commons Attribution Non-Commercial
License (<http://creativecommons.org/licenses/by-nc/3.0/>) which permits unrestricted noncommercial use,
distribution, and reproduction in any medium, provided
the original work is properly cited.

The double compression syndrome of the ulnar nerve is a rare condition. Herin, we experienced double compression of ulnar nerve at cubital tunnel and Guyon's canal by re-evaluation after surgical decompression of cubital tunnel. We might suspect the double compression lesion in cases of worsening of symptom or nerve conduction velocity findings in a relative short duration of symptom as in our case. Meticulous physical examination might be needed to detect the Guyon's canal syndrome as a comorbidity in the treatment of cubital tunnel syndrome and re-evaluation for dual compression might be recommended if the resolution of symptom was not achieved after surgical decompression of single nerve lesion.

Keywords: Cubital tunnel syndrome, Guyon's canal syndrome, Double crushing syndrome, Double compression syndrome, Surgical decompression

INTRODUCTION

Ulnar neuropathy is a common condition and cubital tunnel syndrome is the second most common nerve compression syndrome in the upper extremity after carpal tunnel syndrome¹. The double compression or crushing syndrome was first described by Upton and McComas² and it is a compression neuropathy with dual compression of the single nerve along with its pathway. The proximal compression

lesion of a single nerve might cause the disruption of axonal flow and neurofilament architectures resulting in the distal nerve to be vulnerable to the compression and make clinical symptom worse than the simple addition of symptoms of two compression lesions¹. Both surgical releases of double compression lesion were thought to be optimal rather than the single lesion release¹. The double compression syndrome of the ulnar nerve, especially occurring at the cubital tunnel and Guyon's canal simultaneously was reported

before but is rare^{3,4}. Herein, we experienced the double compression syndrome of ulnar nerve which was diagnosed late after the surgical decompression of the cubital tunnel. The blind faith to the result of nerve conduction study which was the compression of ulnar nerve at distal cubital tunnel and mild compression of median nerve at wrist as well as non-meticulous initial physical examination and rarity of the disease itself made authors miss the compression lesion at Guyon's canal.

CASE REPORT

A 56-year-old female patient, who was a housewife, visited the outpatient clinic with a complaint of tingling sensation in her ring and little fingers for the last eight months. On physical examination, the Tinel's sign in the medial elbow was positive and the elbow flexion test induced tingling sensation in the ring and little fingers. Also, there was a diminished sensation of dorsoulnar aspect of hand with a light touch. The Tinel's sign at the level of the wrist for median nerve was positive and tapping induced tingling sensation in the middle and ring fingers, however the Tinel's test for ulnar nerve at wrist was not performed initially. The Phalen's test was positive and no definite motor compromise was found, such as atrophy of the thenar, hypothenar, and interossei muscles, decrease in pinching power, and difficulty in finger abduction. A nerve conduction velocity (NCV) study revealed a decrease in conduction velocity, between the mid-forearm and elbow segment of the motor component of the ulnar nerve, to 43.2 m/sec, compared with the contralateral side of 63.1 m/sec; and a decrease in conduction velocity, of the sensory component of the ulnar nerve, to 39.6 m/sec at the elbow to wrist segment and 41.5 m/sec at the wrist to finger segment, compared with 56.7 m/sec for the contralateral side of the elbow to the wrist and the wrist to finger segments. Decreased conduction velocity of sensory component of median nerve was also observed. Conservative treatment was prescribed, as follows: a night splint for the elbow for five months and non-steroidal anti-inflammatory drugs (NSAIDs, Aceclofenac 100 mg, twice a day) for two months. However, the patient still complained of discomfort and tingling sensations in the wrist, and mid-

dle, ring, and little fingers. The patient's main complaint was tingling in the ring and little fingers, and the NCV study supported the diagnosis of cubital tunnel syndrome with mild carpal tunnel syndrome. A surgical decompression of the cubital tunnel with subcutaneous ulnar nerve anterior transposition was performed and a mild fusiform swelling of ulnar nerve, distal to cubital tunnel, was observed (Fig. 1). For the carpal tunnel syndrome, 1 mL of triamcinolone was injected into the carpal tunnel. After the operation, the Tinel's sign at distal cubital tunnel was completely disappeared; but, the tingling sensation in the ring and little fingers persisted with a little improvement. Six months after the operation, the patient still complained of tingling sensations in the middle, ring, and little fingers. In the follow-up nerve conduction study, the motor component conduction velocity of the ulnar nerve between elbow and forearm had recovered to 56 m/sec; however, the sensory component conduction velocity of ulnar nerve between wrist and finger were still decreased to 48.9 m/sec, and conduction velocity of dorsal sensory branch of ulnar nerve was recovered from 38.6 to 47.3 m/sec but still decreased compared with 60.9 m/sec of the contralateral side. On repeated physical examination, the meticulous compression around the Guyon's canal evoked abrupt aggravation of the tingling sensation in the ring and little fingers. After this, a wrist magnetic resonance imaging was performed. It revealed a dumbbell-shaped ganglion at the pisotriquetral joint volarly abutting the Guyon's canal (Fig. 2). The surgical decompression of

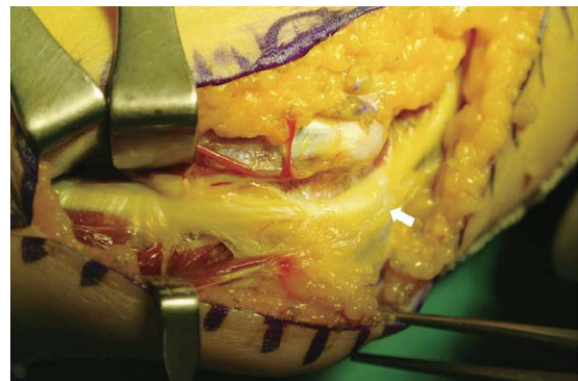


Fig. 1. Surgical decompression of cubital tunnel and subcutaneous ulnar nerve anterior transposition were performed. Focal mild swelling of the ulnar nerve was observed (white arrow).

Guyon's canal with excision of the ganglion and transverse carpal ligament release were performed (Fig. 3). After the surgery, the tingling sensation was almost completely disappeared.

DISCUSSION

The most common compression site of the ulnar nerve is the cubital tunnel⁵ and compression at the Guyon's canal is infrequent but it can occur. The double compression syndrome, including the combination of cervical radiculopathy with carpal tunnel syndrome, has been reported earlier by several authors^{2,6}. However, the double compression syndrome of the ulnar nerve at the cubital tunnel and Guyon's

canal was seldom reported before^{3,4}. In our case, we experienced the double compression syndrome of the ulnar nerve, which was diagnosed late after the surgical decompression of the cubital tunnel. Pearce et al.⁷ emphasized the importance of electrodiagnosis and stated that the electrodiagnostic study was sensitive in the detection of compression of the ulnar nerve at Guyon's canal. However, Osterman⁸ reported that similar motor latencies were demonstrated between an isolated carpal tunnel syndrome and double compression syndrome and it seemed difficult to classify a single nerve lesion as the double crush syndrome by an electrodiagnostic study. We also experienced the double compression syndrome of the ulnar nerve that could not be correctly diagnosed at initial work up although the NCV study was per-

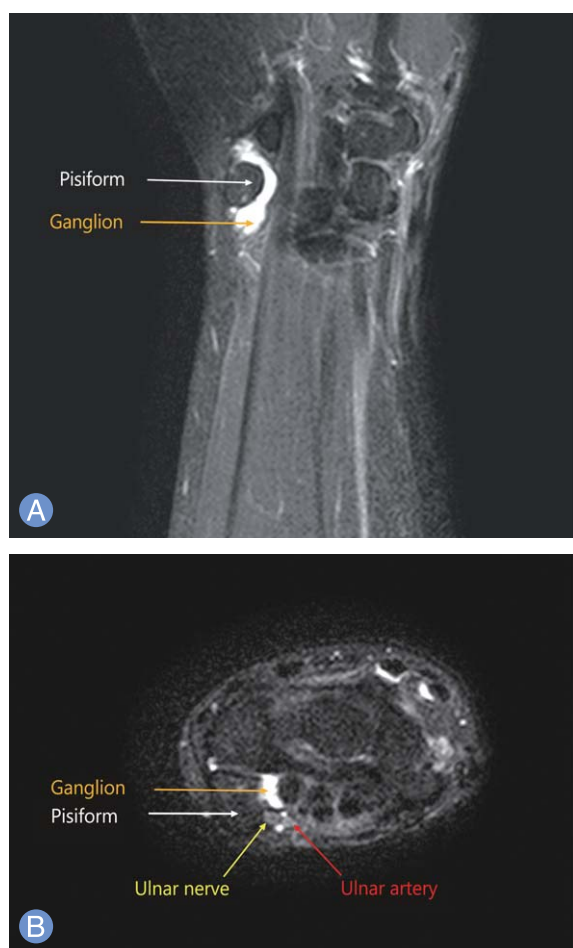

Fig. 2. Magnetic resonance imaging of Guyon's canal. A dumbbell-shaped ganglion at the pisotriquetral joint volarly abutting the ulnar nerve at Guyon's canal was observed. (A) T2 fat suppression coronal image. (B) T2 fat suppression axial image.

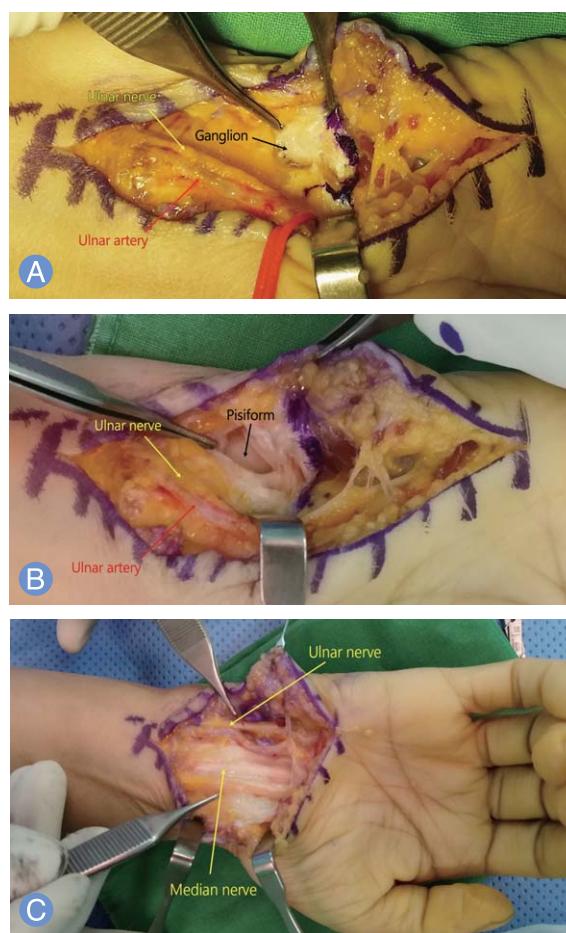


Fig. 3. Guyon's canal decompression with excision of the ganglion and carpal tunnel release. (A) Ganglion was observed on the pisotriquetral ligament. (B) After excision of the ganglion, the capsule was opened. (C) Carpal tunnel release was also performed with Guyon's canal release.

formed. An ulnar nerve lesion at Guyon's canal might be difficult to diagnose by NCV and a proximal compression lesion at the cubital tunnel might hinder diagnosis of the distal compression lesion at Guyon's canal. The clinical features and neurophysiologic findings of double compression syndrome exceed the addition of two single compression lesions, hence and one should suspect the double compression lesion in the cases where there is a worsening of symptoms or NCV findings in a relative short duration of symptoms, as in our case⁸. Meticulous physical examination might be needed to detect Guyon's canal syndrome as a comorbidity in the treatment of cubital tunnel syndrome and re-evaluation for dual compression might be recommended if the resolution of symptoms was not achieved after surgical decompression of single nerve lesion.

REFERENCES

1. Folberg CR, Weiss AP, Akelman E. Cubital tunnel syndrome. Part I: presentation and diagnosis. *Orthop Rev.* 1994;23:136-44.
2. Upton AR, McComas AJ. The double crush in nerve entrapment syndromes. *Lancet.* 1973;2:359-62.
3. Monacelli G, Spagnoli AM, Pardi M, Valesini L, Rizzo MI, Irace S. Double compression of the ulnar nerve at the elbow and at the wrist (double-crush syndrome): case report and review of the literature. *G Chir.* 2006;27:101-4.
4. Guidicelli T, Londner J, Gonnelli D, Magalon G. Two anomalous muscles of a forearm revealed by ulnar nerve compressions, a Double Crush syndrome. *Ann Chir Plast Esthet.* 2014;59:208-11.
5. Ochiai N, Honmo J, Tsujino A, Nisiura Y. Electrodiagnosis in entrapment neuropathy by the arcade of Struthers. *Clin Orthop Relat Res.* 2000;(378):129-35.
6. Moghtaderi A, Izadi S. Double crush syndrome: an analysis of age, gender and body mass index. *Clin Neurol Neurosurg.* 2008;110:25-9.
7. Pearce C, Feinberg J, Wolfe SW. Ulnar neuropathy at the wrist. *HSS J.* 2009;5:180-3.
8. Osterman AL. The double crush syndrome. *Orthop Clin North Am.* 1988;19:147-55.

주관유리술 후 척골신경의 이중압박증후군 확인

김준엽 · 곽호일 · 유정현 · 김주학 · 손동욱 · 조재호

명지병원 정형외과

척골신경의 이중압박증후군은 드문 질환이다. 본 문헌에서는 저자들은 척골관의 외과적 감압술 후 재평가를 통하여 척골관과 기용관의 이중압박증후군이 있음을 확인하였다. 저자들의 예에서처럼 비교적 짧은 임상증상의 기간에도 신경전도 검사 및 증상의 악화가 있는 경우, 이중압박증후군을 의심할 수도 있다. 척골 신경관 증후군의 치료에서 동반병변으로 기용관증후군을 발견할 수 있는 철저한 이학적 검사가 필요할 수도 있으며, 단일 신경병변의 외과적 감압술 후 증상의 개선을 달성할 수 없다면, 이중압박에 대한 재평가가 필요할 수도 있다.

색인단어: 주관증후군, 기용관증후군, 이중압박증후군, 외과적 감압술

접수일 2015년 5월 10일 **수정일** 1차: 2015년 8월 13일, 2차: 2015년 8월 28일

게재확정일 2015년 8월 31일

교신저자 곽호일

경기도 고양시 덕양구 화수로 14번길 55

명지병원 정형외과

TEL 031-810-5114 FAX 031-969-0500

E-mail khinael@naver.com