

Pure Cancellous Iliac Bone grafting for the Treatment of Scaphoid Waist Nonunions with Humpback Deformity

Jin-Ho Lee, Myung-Sun Kim

*Department of Orthopedic Surgery,
Chonnam National University Hospital,
Chonnam National University Medical School,
Gwangju, Korea*

Received: January 29, 2014

Revised: March 12, 2014

Accepted: March 24, 2014

Correspondence to: Myung Sun Kim
Department of Orthopedics Surgery,
Chonnam National University Hospital,
Chonnam National University Medical School,
42 Jebong-ro, Dong-gu, Gwangju 501-757,
Korea
TEL: +82-62-227-1640
FAX: +82-62-225-7794
E-mail: mskim@jnu.ac.kr

This is an Open Access article distributed under the terms of the Creative Commons Attribution Non-Commercial License (<http://creativecommons.org/licenses/by-nc/3.0/>) which permits unrestricted noncommercial use, distribution, and reproduction in any medium, provided the original work is properly cited.

Purpose: We evaluated clinical and radiographic results of the pure cancellous bone grafting and internal fixation for the treatment of scaphoid waist nonunions with humpback deformity.

Methods: The subject of this study were 46 patients who had a scaphoid waist nonunion with humpback deformity treated with bone grafting between January 2005 and December 2011. The average follow-up period was 18.6 months (range, 12–26 months). We performed open reduction through an anterior approach with correction of the deformity and insertion of a screw from distal to proximal. We filled the resultant defect with pure cancellous autograft. The clinical results were evaluated with range of motion of the wrist joint, Disabilities of the Arm, Shoulder, and Hand (DASH) score, modified Mayo wrist score and visual analogue scale. For radiographic evaluation, we assessed lateral scapholunate angle and intrascaphoid angle.

Results: Bony union was achieved in 39 out of 46 patients (84.8%). DASH score significantly improved from 24.0 to 7.3 postoperatively. The modified Mayo wrist score also increased from 64.8 to 88.6 postoperatively. There were 17 excellent results 18 good results. The average scapholunate angle and intrascaphoid angle improved from 70.6°, 51.5° to 52.4°, 33.9° postoperatively.

Conclusion: Pure cancellous bone grafting and internal fixation provide good clinical result in patients with a scaphoid waist nonunion with successful restoration of the humpback deformity.

Keywords: Scaphoid, Nonunion, Humpback deformity, Cancellous bone graft

INTRODUCTION

The scaphoid is the most commonly fractured carpal bone, accounting for approximately 60% of all carpal fractures, and continue to present diagnostic and therapeutic challenges¹. Early diagnosis and adequate primary treatment are important to provide healing and prevent late complications². The

symptoms can often be misinterpreted as a sprain both by the patient and the doctor, and acute fractures may be difficult to see on ordinary X-rays³. Despite scaphoid fractures are primarily recognized and treated appropriately, nonunion may occur in 5% to 15%⁴. According to the recent report, most case series report an approximate 10% nonunion rate⁵. More recent data reported that fracture displacement (usual-

ly defined as a gap or translation between the fracture fragments) has been associated with a risk of nonunion up to 55%⁶⁻⁸.

Conventional treatment of scaphoid waist nonunion with collapse deformity and bone loss typically involves the use of bone graft and internal fixation. The goal of surgery in this setting is first to adequately reduce the scaphoid, thereby restoring carpal height and alignment. Treatment of scaphoid nonunion includes autologous bone transplantation (including vascularized grafts), internal fixation (pins, screws or plates), and casting for varying durations. Various surgical methods have been presented, however, the ideal treatment for scaphoid nonunion remains uncertain⁸⁻¹⁰. Despite these controversies, there is a general consensus that corticocancellous bone graft is necessary for large defects, cancellous bone chip graft for small defects, wedge bone graft for correction of humpback deformity and vascularised bone graft for avascular necrosis (AVN) of the proximal fragment^{8,11-13}. Few studies have been carried out on the use of pure cancellous bone graft and headless compression screw fixation for unstable scaphoid nonunion. This technique has a markedly simplified surgical procedure with no need to shape the graft, the ability to use local cancellous bone, and more rapid incorporation of cancellous as opposed to cortical bone.

The purpose of this study was to evaluate the surgical outcome of internal fixation with pure cancellous bone graft for unstable scaphoid waist nonunion with humpback deformity

and to evaluate the factors that may affect the nonunion of the scaphoid waist fracture.

MATERIALS AND METHODS

A retrospective review of 46 patients who underwent surgical treatment because of scaphoid waist nonunion between January 2005 and December 2011 was performed. Patient medical records including clinical variables and baseline patient characteristics as well as operative and radiological data were reviewed. There were 41 male and 5 female, with a mean age of 29.2 years (range, 15 to 54 years) and a mean time between injury and operation of 10.2 months (range, 7 to 15 months). Mean follow-up duration was 18.6 months (12 to 26 months) and 22 people were smokers. The inclusion criteria were a nonunion of a fracture of the waist of the scaphoid of at least six months' duration, with bone resorption of ≥ 2 mm (mean, 4.3 mm; range, 2 to 7 mm) and the presence of humpback deformity (intrascaphoid angle $>35^\circ$ ¹⁴), excessive sclerosis or arthritis. And all the patients had plain radiographs and preoperative and postoperative computed tomography (CT) scans (Fig. 1), and none had undergone previous wrist surgery.

1. Functional assessment

Functional outcome was assessed by an orthopaedic specialist physiotherapist as the palmar-located scars could easily be seen, and included preoperative and postoperative measure-

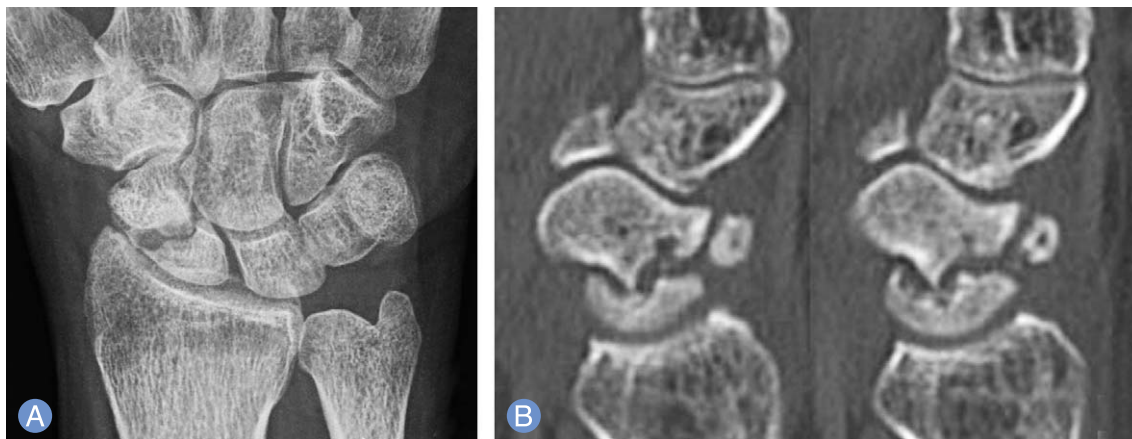

Fig. 1. (A) Preoperative radiographs shows nonunion of scaphoid waist. (B) Computed tomography shows scaphoid nonunion and humpback deformity.

ment of active range of wrist movement using a goniometer. Final clinical results were compared to the preoperative measurements. Wrist pain was evaluated using a visual analogue scale (VAS 0=no pain, VAS 10=severe pain). Functional subjective outcome was measured with the Disability of the Arm, Shoulder, and Hand (DASH) questionnaire¹⁵. This has a 0 to 100 point scale where 0 represents the best result. Further evaluation used the modified Mayo wrist score¹⁴, which is based on four categories: pain, functional status, movement and grip strength. The score is given in a range from 0 to 100; where 0 to 60 is poor, 60 to 80 fair, 80 to 90 good, and 90 to 100 is excellent.

2. Radiological assessment

Standard posteroanterior, lateral and oblique radiographs of the wrist were taken. Assessment was performed by a reviewer who was not a member of the surgical team and who was blinded to the functional outcome but not to the method of treatment. The preoperative and postoperative radiographs and CT scans were further assessed for the scapholunate¹⁶ angle and intrascaphoid angle. Changes in the scapholunate angle were evaluated to assess palmar rotation of the scaphoid. The presence of humpback deformity was assessed by changes in the intrascaphoid angle on lateral radiographs¹⁷. Fracture union was defined according to the criteria described by Dias¹⁸ and was assessed at final follow-up from radiographs or with CT scans if the radiological appearances were inconclusive.

3. Surgical technique and post-operative management

The procedure is carried out under general anesthesia. Surgical preparation requires sterilization and draping on the hand table with preparation of the iliac crest for harvesting of the bone graft. Preoperative antibiotics are administered. The scaphoid is approached through the volar aspect by a longitudinal incision along the radial border of the flexor carpi radialis. The palmar crease is crossed in a zigzag manner to avoid contracture. Longitudinal capsulotomy is done to expose the scaphoid. The fibrous nonunion of the scaphoid is debrided, and the necrotic tissue is removed. The distal part of the scaphoid is curetted to obtain a vascularized bed. The dorsal aspect of the scaphoid is left intact as a lip to prevent

dorsal dislocation of the graft. The humpback deformity is corrected with temporary K-wire fixation and guide wire of screw, and the size of the graft required is assessed. The cancellous bone was harvested from the iliac crest in all patients via a 3 cm skin incision with the periosteum raised using a Cobb elevator. We made a rectangular cortical window and only harvested the cancellous bone. Next, the cortical window bone was repositioned and the periosteum was sutured. The cancellous bone was prepared as chips and packed into the prepared cavity. Retrograde headless compression screw (Herbert screw) fixation was performed under C-arm control. A self-tapping 3 mm standard cannulated screw was inserted freehand over a guide wire. The screw was inserted through the scaphotrapezial joint by pulling on the thumb dorsally and to the ulnar side, thereby exposing the most volar and radial part of the joint. The leading part of the screw was anchored in the center of the proximal pole with its threads completely across the bone graft. The final axis of the screw was parallel to the volar surface of the scaphoid when viewed in a C-arm. The head was buried under the distal articular surface. Good purchase was assured during the last turns of the screw threads (Fig. 2). If indeed, we did additional K-wire fixation for stability. The wrist was immobilized for two weeks in a below-elbow thumb spica splint with the thumb in abduction, leaving the interphalangeal joint free. The skin sutures were removed two weeks post-operatively after

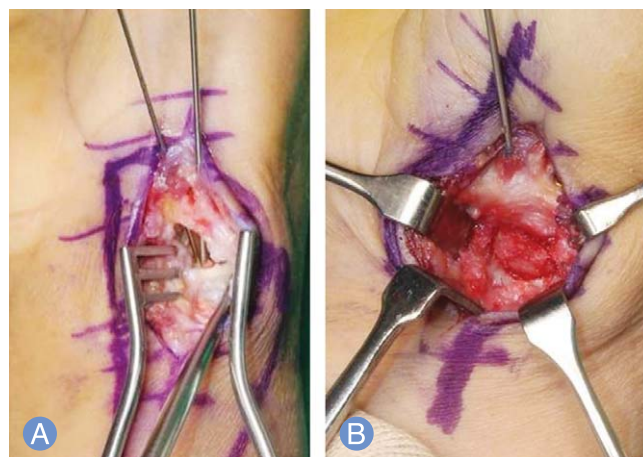


Fig. 2. Intraoperatively. (A) The leading part of the pin was anchored in the center of the proximal pole with it completely across the bone graft. (B) The final axis of the pin was parallel to the volar surface of the scaphoid.

Table 1. Clinical results

Clinical results	Preoperative	Postoperative (last follow-up)	p-value
Wrist flexion	69.8 ± 10.2	72.4 ± 13.2	>0.05
Wrist extension	59.5 ± 9.4	60.5 ± 14.2	>0.05
VAS score	5.7 ± 1.3	0.9 ± 1.0	<0.05
Modified Mayo wrist score	64.8 ± 9.2	88.6 ± 7.6	<0.05
DASH score	24.0 ± 9.9	7.3 ± 5.4	<0.05

VAS, visual analogue scale; DASH, Disabilities of the Arm, Shoulder, and Hand.

which a short-arm thumb spica cast was worn for an additional mean of five weeks (four to six). After the cast was removed, gentle exercises and light activities were permitted with the assistance of a wrist brace for an additional four weeks. Patients were permitted to resume normal activities of daily living 12 weeks postoperatively.

4. Statistical analysis

Descriptive statistics were reported as the mean and standard deviation (SD) for continuous variables and as the number (and percentage where possible) for discrete assessments. Preoperative and postoperative clinical and radiological measures in each group (preoperatively vs. postoperatively each patient) were analysed using paired t-test. For the factors affecting the union and non-union groups were compared using the Mann-Whitney U test. The failure rates of two groups were analysed with Fisher's exact test. Statistical significance was defined as a p-value <0.05. All statistical analyses were performed using PASW ver. 18.0 (SPSS Inc., Chicago, IL, USA).

RESULTS

No patients were lost to follow-up, which was for a mean of 18.6 months (range, 12 to 26 months). The mean time to union was 14.1 weeks (range, 8 to 27 weeks) and bony union was achieved in 39 out of 46 patients (84.8%). VAS improved from a mean of 5.7 (SD, 1.3) to a mean of 0.9 (SD, 1.0), which significantly improved ($p < 0.05$). The mean preoperative range of movement was 59.5° (SD, 9.4°), 69.8° (SD, 10.2°) for extension, flexion, respectively. The postoperative range of movement improved to means of 60.5° (SD, 14.2°), 72.4° (SD, 13.2°) ($p > 0.05$) for extension, flexion, respectively. The modified Mayo wrist score was significantly improved from 64.8 (SD, 9.2) to 88.6 (SD, 7.6), postoperatively ($p < 0.05$). Excellent results were obtained 17 patients (37%), good in 18 (39%), fair in 8 (17%) and poor in 3 (7%) patients. DASH score also significantly improved from 24.0 (SD, 9.9) to 7.3 (SD, 5.4), postoperatively ($p < 0.05$) (Table 1).

Radiographs and advanced imaging revealed no hardware migration or deterioration of the scaphoid alignment at final

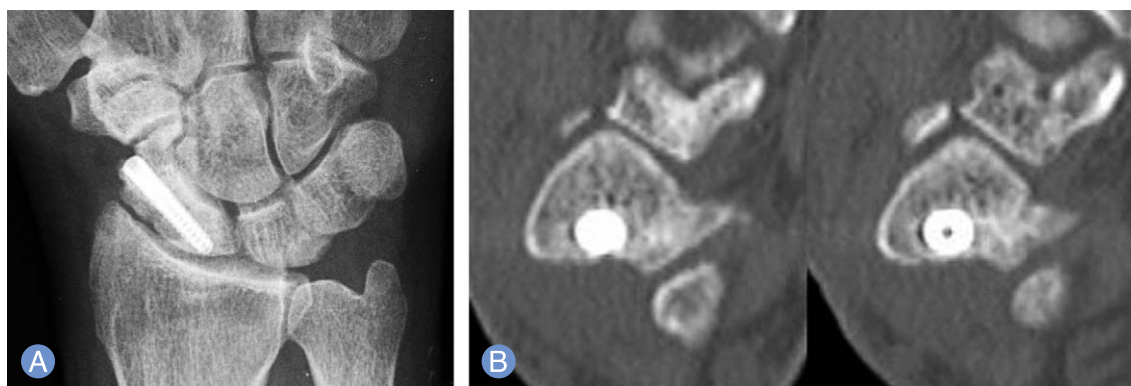


Fig. 3. (A) One year after surgery radiographs showed union of scaphoid waist fracture. (B) on computed tomography scan, humpback deformity was corrected.

Table 2. Radiological results

Radiological measurements	Preoperative	Postoperative (last follow-up)	p-value
Scapholunate angle	70.6 ± 10.6	52.4 ± 4.0	<0.05
Intrascaphoid angle	51.5 ± 6.9	33.9 ± 3.0	<0.05

Table 3. Factors affecting scaphoid nonunion

Characteristic	Union	Nonunion	p-value
Sex (male/female)	36/3	5/2	>0.05
Age (yr)	28.3 ± 11.4	34.0 ± 9.4	>0.05
Smoking (%)	42.8	71.4	<0.05
Scapholunate angle (preoperative)	68.5 ± 10.1	62.4 ± 7.3	>0.05
Intrascaphoid angle (preoperative)	51.6 ± 7.0	49.7 ± 5.0	>0.05

follow-up (Fig. 3). We noted no identifiable arthrosis at the radioscaphoid or midcarpal joints. The average lateral intrascaphoid angle, as measured on follow-up computed tomography, was significantly improved from 51.5° (SD, 6.9°) to 33.9° (SD, 3.0°) at follow-up (normal, <35°) ($p < 0.005$)¹⁶. Also, scapholunate angle was significantly improved 70.6° (SD, 10.6°) to 52.4° (SD, 4.0°) at follow-up (normal, <35°) ($p < 0.005$) (Table 2). No patients required removal of hardware or had problems related to the incision made for the iliac cancellous bone graft.

Between postoperatively united and non-united group, for the risk factor of the scaphoid waist fracture nonunion, only the smoking showed significant differences between two groups (42.8% vs. 71.4%) ($p < 0.005$) (Table 3). Age, sex, and preoperative scapholunate and intrascaphoid angle which demonstrated the severity of the fracture did not show any significant difference between the two groups.

DISCUSSION

A scaphoid waist nonunion typically leads to flexion and shortening of the scaphoid with carpal collapse. Therefore, the goal in the surgical management of scaphoid nonunion is improving wrist function. This includes not only bony union but also restoring scaphoid alignment for functional improvement, because re-establishment of the scaphoid length relieves pain, improves grip strength and prevents degenerative changes¹⁶. Amadio et al.¹⁴ found that individuals who regained normal scaphoid alignment, defined by a lateral intrascaphoid angle of less than 35°, were more likely to

have satisfactory function and less likely to have arthritis than patients with greater intrascaphoid angles. This documents the importance of restoring normal carpal anatomy. In our study, only using the iliac pure cancellous bone graft and internal fixation, showed significantly restored scaphoid alignment with mean intrascaphoid angle of 33.9°.

The common sites of bone graft harvesting for scaphoid grafting are the iliac crest and the distal radius¹⁹. But according to the reported data, the most frequently used technique, was placing a compression-resistant corticocancellous bone graft, typically from the iliac crest, supported with internal fixation²⁰⁻²⁴. Corticocancellous bone from the distal radius has also been proposed. Although there has been controversy on which is the best graft material, iliac crest grafts permit greater retrieval of marrow and more osteogenic mesenchymal stem cells. Therefore this source can provide superior osteogenic properties compared with graft from the distal radius²⁵. One retrospective comparative study of nonvascularized grafts from different sources has been performed for treatment of scaphoid nonunions²⁶. This study showed no significant differences in union rate between grafts harvested at the iliac crest and grafts harvested at the dorsal side of the distal radius. Therefore, when the size of the distal and proximal poles is adequate to allow for screw purchase, iliac cancellous bone graft alone may be a viable graft alternative. Advantages include a simplified surgical procedure with no need to shape the graft, the ability to use local cancellous bone, and more rapid incorporation of cancellous bone as opposed to cortical bone¹⁰. Although the variable pitched

screw used in the study theoretically provides compression during placement, we saw no detectable loss of reduction during screw placement. And we also achieved good results in unstable scaphoid nonunion by using pure cancellous bone grafts from the iliac crest and headless compression screw fixation.

One randomized, controlled trial compared vascularized to nonvascularized bone grafting for scaphoid nonunion¹⁶. In this study, 35 patients were allocated to treatment with a vascularized 1, 2-intercompartmental supraretricular artery pedicle graft and 45 patients were allocated to treatment with a nonvascularized iliac crest graft. All patients in the nonvascularized group healed, whereas 3 patients in the vascularized group failed to heal, all of which were related to technical difficulties. There were no significant differences between the groups in union rates, time to union, and functional results, with the exception of a small and likely clinically insignificant greater radial deviation in the vascularized group. Therefore, although previous report showed high bony union rate (Stark et al.²³ 81%) using Mattie-Russe technique or vascularized bone grafting pure cancellous bone graft and internal fixation technique could show comparable bony union rate as much as previous described techniques.

We found an overall high rate of patient satisfaction concerning pain and function and a minimal reduction of range of motion and strength, which we believe to be attributed to the anatomic restoration and healing of the nonunions. Pain relief was achieved, as measured by visual analog scales and standardized outcome instruments. Pain-free wrist mobility greater than 110 degrees, was experienced by all our patients, and function was also significantly achieved, as measured by modified Mayo wrist score and DASH questionnaire.

Advanced imaging documented that 84.8% of patients in our series achieved bony union. In addition, the preoperative humpback deformity was significantly improved. This documents maintenance of scaphoid reduction despite the using pure cancellous bone graft. Scaphoid reduction was consistent with other series in which corticocancellous bone graft was used, and intrascaphoid angles were measured using similar imaging techniques²⁷.

The limitations of this study are relatively small number of patients, and short term follow-up. Also, we did not perform

MRI to identify cases with avascular necrosis, which might have had an effect on the pathogenesis of nonunion and how to treat it. However, proximal pole fractures, which have a higher incidence of AVN, were excluded. In addition, our study was retrospective study and lacked of preoperative functional data.

CONCLUSION

The use of cancellous bone graft harvested from the iliac crest with combination of thorough curettage of unhealthy bone and internal rigid fixation with Herbert's screw provides a good treatment option for scaphoid waist nonunion with humpback deformity. Of course, based on the patient's cooperation should be absolutely. This procedure provides sustained rebuilding of scaphoid length, correction of humpback deformity, avoidance of further collapse, and leads to promising bony union.

REFERENCES

1. Hove LM. Epidemiology of scaphoid fractures in Bergen, Norway. *Scand J Plast Reconstr Surg Hand Surg*. 1999;33:423-6.
2. Duppe H, Johnell O, Lundborg G, Karlsson M, Redlund-Johnell I. Long-term results of fracture of the scaphoid. A follow-up study of more than thirty years. *J Bone Joint Surg Am*. 1994;76:249-52.
3. Dias JJ, Thompson J, Barton NJ, Gregg PJ. Suspected scaphoid fractures. The value of radiographs. *J Bone Joint Surg Br*. 1990;72:98-101.
4. Cooney WP, Linscheid RL, Dobyns JH. Scaphoid fractures. Problems associated with nonunion and avascular necrosis. *Orthop Clin North Am*. 1984;15:381-91.
5. Dias JJ, Brenkel IJ, Finlay DB. Patterns of union in fractures of the waist of the scaphoid. *J Bone Joint Surg Br*. 1989;71:307-10.
6. Cooney WP 3rd, Dobyns JH, Linscheid RL. Nonunion of the scaphoid: analysis of the results from bone grafting. *J Hand Surg Am*. 1980;5:343-54.
7. Szabo RM, Manske D. Displaced fractures of the scaphoid. *Clin Orthop Relat Res*. 1988;(230):30-8.
8. Buijze GA, Ochtman L, Ring D. Management of scaphoid nonunion. *J Hand Surg Am*. 2012;37:1095-

- 100.
9. Gabl M, Reinhart C, Lutz M, et al. Vascularized bone graft from the iliac crest for the treatment of nonunion of the proximal part of the scaphoid with an avascular fragment. *J Bone Joint Surg Am.* 1999;81:1414-28.
10. Munk B, Larsen CF. Bone grafting the scaphoid nonunion: a systematic review of 147 publications including 5,246 cases of scaphoid nonunion. *Acta Orthop Scand.* 2004;75:618-29.
11. Pao VS, Chang J. Scaphoid nonunion: diagnosis and treatment. *Plast Reconstr Surg.* 2003;112:1666-76.
12. Ramamurthy C, Cutler L, Nuttall D, Simison AJ, Trail IA, Stanley JK. The factors affecting outcome after non-vascular bone grafting and internal fixation for nonunion of the scaphoid. *J Bone Joint Surg Br.* 2007;89:627-32.
13. Osterman AL, Mikulics M. Scaphoid nonunion. *Hand Clin.* 1988;4:437-55.
14. Amadio PC, Berquist TH, Smith DK, Ilstrup DM, Cooney WP 3rd, Linscheid RL. Scaphoid malunion. *J Hand Surg Am.* 1989;14:679-87.
15. MacDermid JC, Richards RS, Donner A, Bellamy N, Roth JH. Responsiveness of the short form-36, disability of the arm, shoulder, and hand questionnaire, patient-rated wrist evaluation, and physical impairment measurements in evaluating recovery after a distal radius fracture. *J Hand Surg Am.* 2000;25:330-40.
16. Braga-Silva J, Peruchi FM, Moschen GM, Gehlen D, Padoin AV. A comparison of the use of distal radius vascularised bone graft and non-vascularised iliac crest bone graft in the treatment of non-union of scaphoid fractures. *J Hand Surg Eur Vol.* 2008;33:636-40.
17. Linscheid RL, Dobyns JH, Beabout JW, Bryan RS. Traumatic instability of the wrist: diagnosis, classification, and pathomechanics. *J Bone Joint Surg Am.* 2002;84:142.
18. Dias JJ. Definition of union after acute fracture and surgery for fracture nonunion of the scaphoid. *J Hand Surg Br.* 2001;26:321-5.
19. Jarrett P, Kinzel V, Stoffel K. A biomechanical comparison of scaphoid fixation with bone grafting using iliac bone or distal radius bone. *J Hand Surg Am.* 2007;32:1367-73.
20. Fernandez DL. A technique for anterior wedge-shaped grafts for scaphoid nonunions with carpal instability. *J Hand Surg Am.* 1984;9:733-7.
21. Kawamura K, Chung KC. Treatment of scaphoid fractures and nonunions. *J Hand Surg Am.* 2008;33:988-97.
22. Merrell GA, Wolfe SW, Slade JF 3rd. Treatment of scaphoid nonunions: quantitative meta-analysis of the literature. *J Hand Surg Am.* 2002;27:685-91.
23. Stark HH, Rickard TA, Zemel NP, Ashworth CR. Treatment of ununited fractures of the scaphoid by iliac bone grafts and Kirschner-wire fixation. *J Bone Joint Surg Am.* 1988;70:982-91.
24. Wong TC. Palmar corticocancellous grafting and Acutrak screw fixation for nonunion of the scaphoid. *J Hand Surg Eur Vol.* 2010;35:421.
25. Taleisnik J, Kelly PJ. The extraosseous and intraosseous blood supply of the scaphoid bone. *J Bone Joint Surg Am.* 1966;48:1125-37.
26. Tambe AD, Cutler L, Stilwell J, Murali SR, Trail IA, Stanley JK. Scaphoid non-union: the role of vascularized grafting in recalcitrant non-unions of the scaphoid. *J Hand Surg Br.* 2006;31:185-90.
27. Trumble TE, Clarke T, Kreder HJ. Non-union of the scaphoid. Treatment with cannulated screws compared with treatment with Herbert screws. *J Bone Joint Surg Am.* 1996;78:1829-37.

구배 변형을 동반한 주상골 요부 불유합에 대한 순수 해면골 이식술 및 내고정술

이진호 · 김명선

전남대학교 의과대학 정형외과학교실

목적: 구배 변형을 동반한 주상골 요부 골절 불유합에 대한 순수 해면골 이식술과 내고정술을 이용한 임상적, 영상의학적 결과를 평가해 보고자 하였다.

방법: 2005년 1월부터 2011년 12월까지 구배 변형을 동반한 주상골 요부 골절 불유합으로 진단된 총 46명의 환자를 대상으로 하였다. 평균 추시 기간은 수술 후 18.6개월(범위, 12-26개월)이었다. 전방 도달법을 통해 변형 교정후 주상골의 원위부에서 근위부로 나사못을 삽입하였으며, 남아있는 주상골의 골결손 부분에 대해 순수 해면골 이식술을 시행하였다. 임상적 결과로 손목의 관절운동, Disabilities of the Arm, Shoulder, and Hand (DASH) score, modified Mayo wrist score 및 visual analogue scale을 평가하였으며, 영상의학적으로 측면 주상 월상 각 및 주상골내 각을 평가하였다.

결과: 총 46예 중 39예(84.8%)에서 골유합이 확인되었다. DASH 점수는 수술 전 평균 24.0점에서 수술 후 평균 7.3점, modified Mayo wrist score는 수술 전 64.8점에서 수술 후 88.6점으로 유의하게 향상되었으며 우수 17예, 양호 18예를 확인하였다. 수술 전, 수술 후 방사선촬영상 확인한 주상 월상각 및 주상골내 각은 각각 수술 전 70.6°, 51.5°에서 수술 후 52.4°, 33.9°로 유의한 차이를 보였다.

결론: 주상골 요부 골절 불유합의 치료에 있어서 순수 해면골 이식 및 내고정술은 좋은 임상적 결과뿐 아니라 구배 변형의 교정 및 유지에도 양호한 결과를 얻을 수 있는 신뢰할 수 있는 치료 방법의 하나로 생각된다.

색인단어: 주상골, 불유합, 구배변형, 해면골 이식

접수일 2014년 1월 29일 수정일 2014년 3월 12일

게재확정일 2014년 3월 24일

교신저자 김명선

광주광역시 동구 제봉로 42

전남대학교 의과대학 정형외과학교실

TEL 062-227-1640, FAX 062-225-7794

E-mail mskim@jnu.ac.kr