

· · · · ·

---

[ ]

:

가

8

: 1999 1 2002 4

12 가 가

8

41.5 (23~74 )

, 가 5 , 가 3

: 가

1.1 cm ,

18.6

, 1 5 , 35

:

: , ,

---

---

:

134-701, 445

: +82-2-2224-2234, Fax: +82-2-489-4391  
e-mail: ipark@hallym.or.kr



**Fig. 1.** IC nail (Osteo, Switzerland), the most distal hole for interlocking screw separated from distal end of nail about 2 mm.

가 , 가 , 가 .

가

1,3,13)

4,7)

15,16)

가

가

Interlocking

compression nail (IC nail, Osteo, Switzerland) (Fig. 1)

가

가

10

10~20 kg

가

1999 1 2002 4

12

가 가 8 . 5

, 3 23

74 41.5 .

4 , 가 2 , 가 2 ,

가

가

1 mm

가

1.1 cm (0~3.0 cm) ,

18.6 (14~26 ) . ,

, , 1 5

, 35 .

1. 1

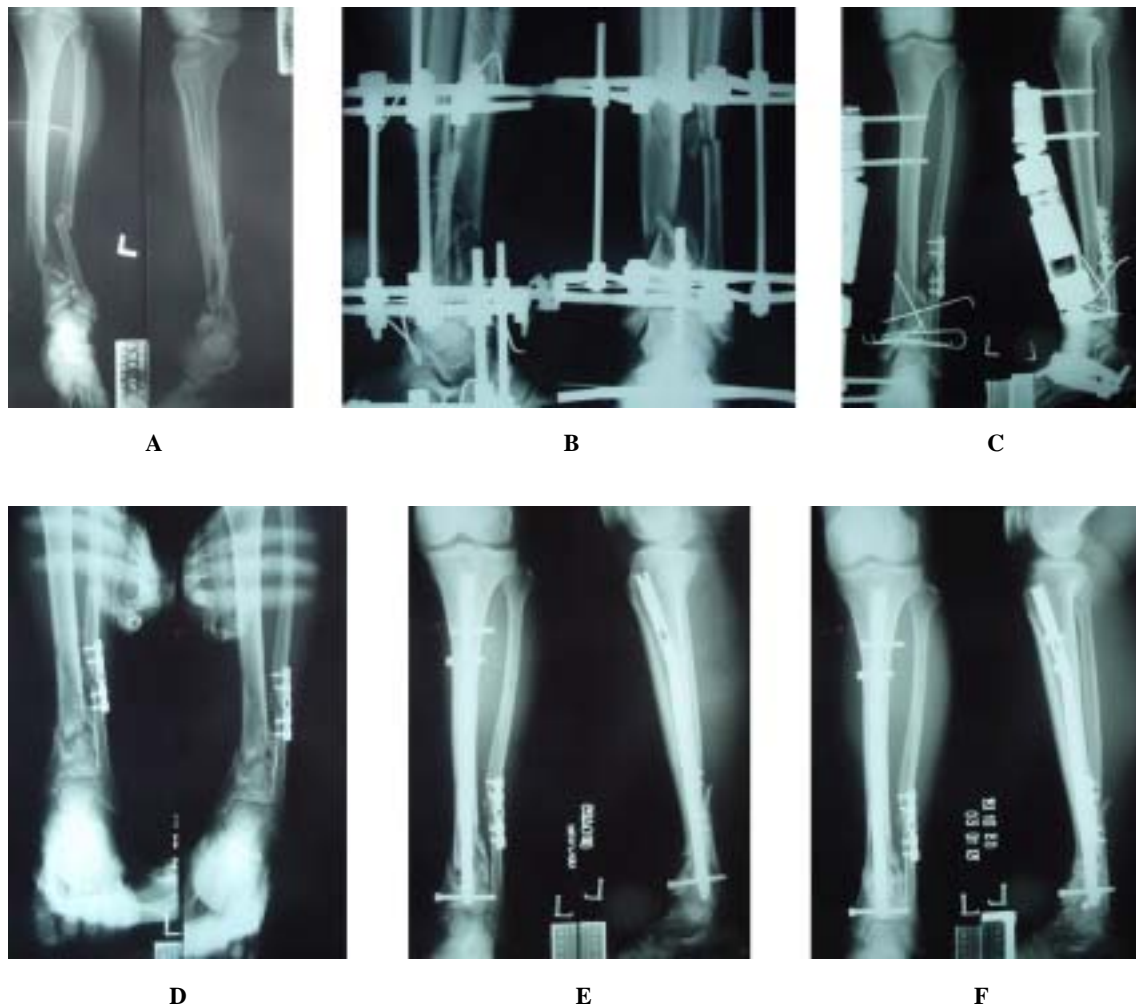
61

(Fig. 2A),

Ilizarov

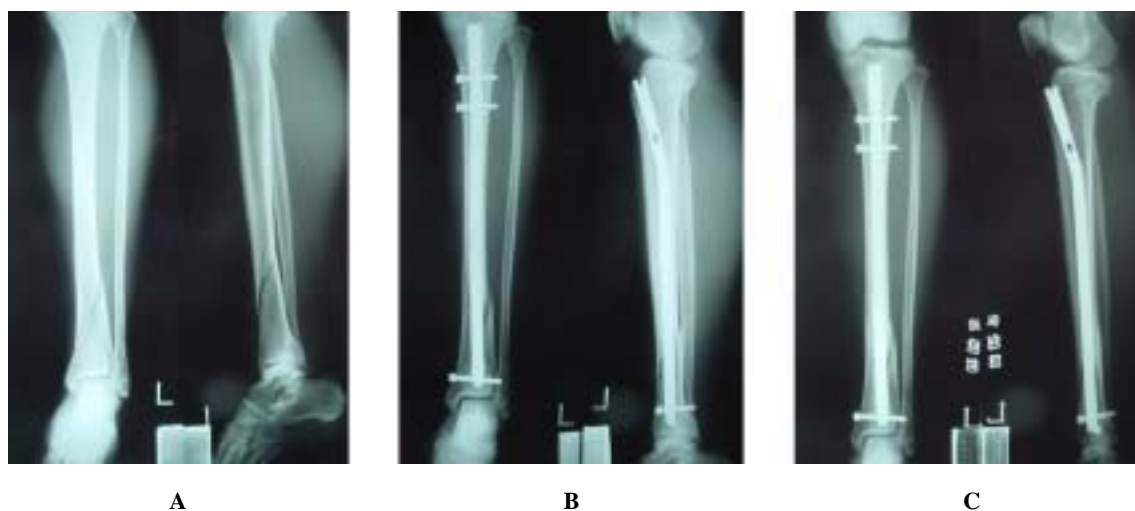(Fig. 2B),

1

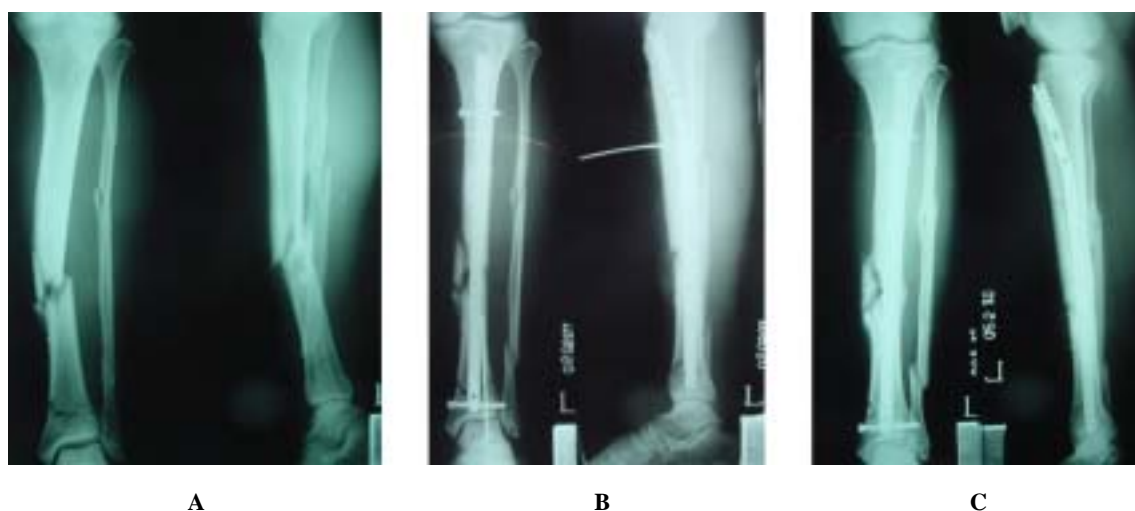

**Fig. 2A.** A 61-year-old man was injured by traffic accident, and he had left distal tibial intraarticular comminuted open fracture and fibular segmented fracture.  
**2B.** At first, he was managed by Ilizarov fixation.  
**2C.** At 1 month later from first operation, he was transferred to our hospital, and the second operation was done with open reduction and bone graft.  
**2D.** At 5 months later from second operation, delayed union was found on the stress radiograph.  
**2E.** The third operation was done with IC nail.  
**2F.** At 9 months later from third operation, bone union was done.

, Switzerland) (Fig. 2E).  
 9  
 (Fig. 2F).  
 (Fig. 2C). 5 2. 2  
 stress  
 (Fig. 2D) IC nail (Osteo, 36



**Fig. 3A.** 36-year-old woman was injured by slip down, and she had distal tibial and proximal fibular fractures.  
**3B.** She was managed by IC nail.  
**3C.** At 16 months later, bone union was found.



**Fig. 4A.** A 55-year-old man was injured by traffic accident, and he ha distal tibial and fibular fractures.  
**4B.** He was managed by IC nail with only one distal interlocking screw.  
**4C.** At 3 months later, callus formation was found.

가 (Fig. 3C).  
 2 cm (Fig. 3A), 3. 3  
 IC nail (Osteo, Swi- 55  
 tzerland) (Fig. 3B).  
 16 가

2 cm (Fig. 4A),  
IC nail (Osteo, Switzerland)  
(Fig. 4B).

가  
(Fig. 4C).

가 ,  
4,5,8,10)

가 ,  
1,2,13,14)

가 . Bone Johnson<sup>3)</sup>  
5 cm

, d'Aubigne<sup>8)</sup> Henley<sup>10)</sup> 6 cm  
5 cm ,

Melis<sup>12)</sup> 10 cm  
5 cm . Bucholz<sup>6)</sup>  
5 cm

hole  
fatigue failure가 .

가 IC nail  
(Osteo, Switzerland) ,

Rezsaca<sup>15)</sup>  
chholtz<sup>17)</sup>

1

1

가 1

8

## REFERENCES

- 1) **Alms M:** Medullary nailing for fracture of the shaft of the tibia. J Bone joint Surg, 44-B: 328-339, 1962.
- 2) **Asche G:** Result of the treatment of femoral and tibial fractures following interlocking nailing and plate osteosynthesis. A comparative retrospective study. Zentralblatt fur Chirurgie, 114(17): 1146-1154, 1989.
- 3) **Bone LB and Johnson KD:** Treatment of the tibia fractures by reaming and intramedullary nailing. J Bone Joint Surg, 68-A: 877-897, 1986.
- 4) **Bostman O and Hanninen A:** The fibular reciprocal fracture in tibial shaft fractures caused by indirect violence. Arch Orthop Trauma Surg, 100: 115-121, 1982.
- 5) **Brooker AF Jr, EPPS H and Constable D:** New tibial interlocking nail system. J Orthop Trauma, 1-3: 257-259, 1987.
- 6) **Bucholz RW, Ross SE and Lawrence KL:** Fatigue fracture of the interlocking nail in the treatment of fractures of the distal part of the femoral shaft. J Bone

- 
- Joint Surg, 69-A: 1391-1399, 1987.
- 7) **Burwell HN:** Plate fixation of tibial shaft fracture: A survey of 181 injuries. *J Bone Joint Surg (Br)*, 53-B: 258-271, 1971.
  - 8) **d'Aubigne RM, Mauer P, Zucman J and Masse Y:** Blind intramedullary nailing for tibial fracture. *Clin Orthop*, 105: 267-275, 1974.
  - 9) **Hahn D, Bradbury N, Hartley R and Radford PJ:** Intramedullary nail breakage in distal fractures of the tibia. *Injury*, 27: 323-327, 1996.
  - 10) **Henley MB:** Intramedullary devices for tibial fracture stabilization. *Clin Orthop*, 240: 87-96, 1989.
  - 11) **Holbrook JL, Swiontkowski MF and Sanders R:** Treatment of open fractures of the tibial shaft: Ender nailing versus external fixation. A randomized, prospective comparison. *J Bone Joint Surg*, 71-A: 1231-1238, 1989.
  - 12) **Melis GC, Sotgiu F, Lepori M and Guido P:** Intramedullary nailing in segmental tibial fractures. *J Bone Joint Surg*, 63-A: 1310-1318, 1981.
  - 13) **Park IH, Kim DH, Park MR and Shim JM:** Fractures of the tibia treated with interlocking nail. *J Korean Orthop Assoc*, 24: 1-7, 1989.
  - 14) **Puno RM, Teynor JY, Nagano J and Gusilo RB:** Critical analysis of result of 201 tibial shaft fracture. *Clin Orthop*, 212: 113-121, 1986.
  - 15) **Rezsacz EH, Konneker W, Reilmann H and Cuelmann U:** Combination of intramedullary nailing and covered screw osteosynthesis for managing distal tibial fractures with ankle joint involvement. *Unfallchirurg*, 102(12): 907-913, 1998.
  - 16) **Robinson CM, McLauchlan GJ, McLean IP and Court-Brown CM:** Distal metaphyseal fracture of the tibia with minimal involvement of the ankle: Classification and treatment by locked intramedullary nailing. *J Bone Joint Surg (Br)*, 77-B: 781-787, 1995.
  - 17) **Ruchholtz S, Nast-Kolb D and Schweiberer L:** Intramedullary nailing of lower leg fracture with minimal soft tissue injury. *Orthopade*, 25(3): 197-206, 1996.
  - 18) **Shepherd LE, Costigan WM, Gardocki RJ, Ghiassi AD, Patzakis MJ and Stevanovic MV:** Local or free muscle flaps and unreamed interlocked nails for open tibial fractures. *Clin Orthop*, 350: 90-96, 1998.

**Abstract****Interlocking Intramedullary Nailing for Treating Most Distal Tibial Fracture**

**In Heon Park, M.D., Kyung Won Song, M.D., Sung Il Shin, M.D., Jin Young Lee, M.D.,  
Seung Yong Lee, M.D., Tae Hyoung Kim, M.D., Jeong Hun Cha, M.D.**

*Department of Orthopaedic Surgery, Kangdong Sacred Heart Hospital,  
College of Medicine, Hallym University, Seoul, Korea*

**Purpose:** We analyzed the result of treatment for most distal extraarticular tibial fracture using interlocking intramedullary nail.

**Materials and Methods:** From January 1999 to April 2002, 8 patients who had most distal tibial fracture were treated by interlocking intramedullary nailing. The duration of follow-up was more than 12 months. The mean age was 41.5 years old. There were 5 males and 3 females. During follow-up period, we evaluated the bone union, range of motion of knee and ankle joint and gait pattern.

**Results:** The average distance from fracture line to ankle joint line was 1.1 cm. The bone union was achieved at average 18.6 weeks. At the last follow-up, there was no limited motion on knee. But at one case, ankle range of motion was limited from 5 degree extension to 35 degree flexion. There was no gait disturbance.

**Conclusion:** Interlocking intramedullary nailing can be recommendable and useful in the most distal tibial fractures.

**Key Words:** Tibia, Most distal fracture, Interlocking intramedullary nail

**Address reprint requests to** \_\_\_\_\_

In Heon Park

445, Gil-Dong, Kangdong-Gu, Seoul, Korea, 134-701

Department of Orthopaedic Surgery, Kangdong Sacred Heart Hospital

Tel : +82-2-2224-2234, Fax : +82-2-489-4391

E-mail : ipark@hallym.or.kr