

Nancy

· · · ·

[]

: Nancy

, , , ,

.

: Nancy 1 가

12 4 12 7.2 , 2~3

Nancy .

: 9.9 5° 2

mm 12 mm 2.8 cm 10 mm 1

. , , 1

1 . 17.3 .

: Nancy

.

: , , Nancy

: 130-711, 2 29-1

: +82-02-2210-3581, Fax: +82-02-2217-1897
e-mail: oskgy@hotmail.com

2001 5 2003 5
 Nancy 1
 가 12 12 ,
 4 12 7.2 .
 8 , 4 .
 9 , 3 2 ,
 , 10
 . 1
 (Fig. 1A~C). 8 (Fig. 1~3),
 2 , 2 ,
 4 (Fig. 3A~C), 5 (Fig. 1, 2), 3
 .
 Nancy
 1 가 , 3 3.5 mm , blunt-ended
 , , , 2 cm 45° ,
 . 4 mm drill

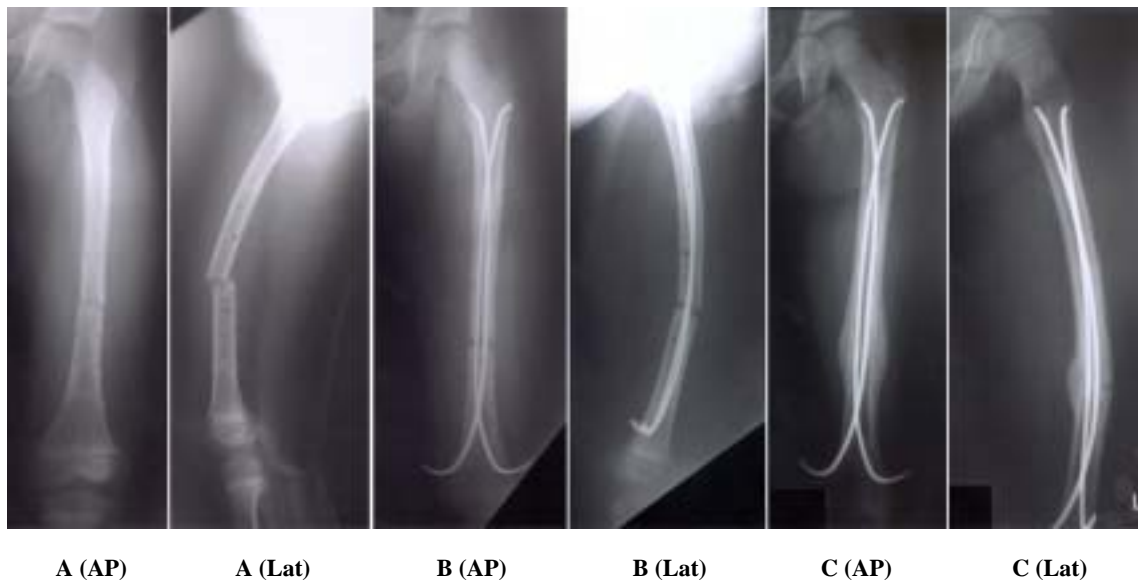

Fig. 1. Serial radiograph of 7 year old boy treated by Nancy nail.
1A. Preoperative AP and Lateral radiogram shows refracture of the femur at the previous fractured site, on the 3rd days after the removal of External Fixator.
1B. Immediate postoperative radiogram presents two inserted Nancy nails.
1C. Postoperative 3 months follow up radiogram shows well unioned fractured site.

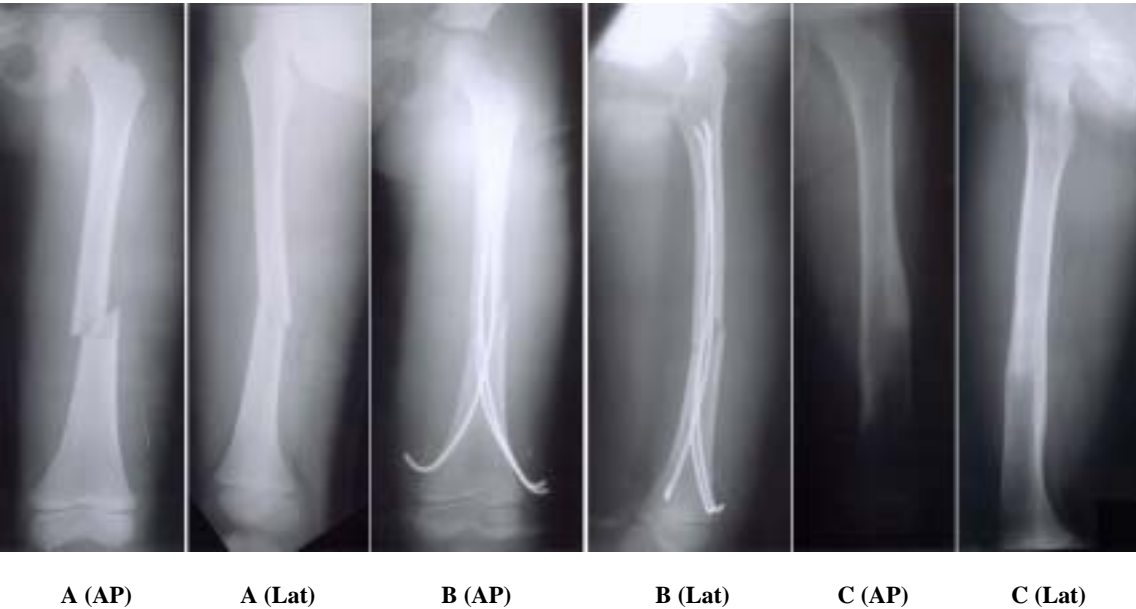

Fig. 2. Serial radiograph of 9 year old boy treated by Nancy nail.
2A. Preoperative AP and Lateral radiogram shows transverse fracture at the middle 1/3 of femur.
2B. Immediate postoperative radiogram presents three inserted nails.
2C. Postoperative 12 months follow up radiogram shows complete union feature.

T-handle		4 cm		6 cm	
				1	
				1	
				가	
2				2	
가		3		17.3	
		가		3	
				9.9	
3				5°	
				2 mm	
				2 , 10 mm	
		1		2.8 mm	
				, 10 mm	
(Table 1).					

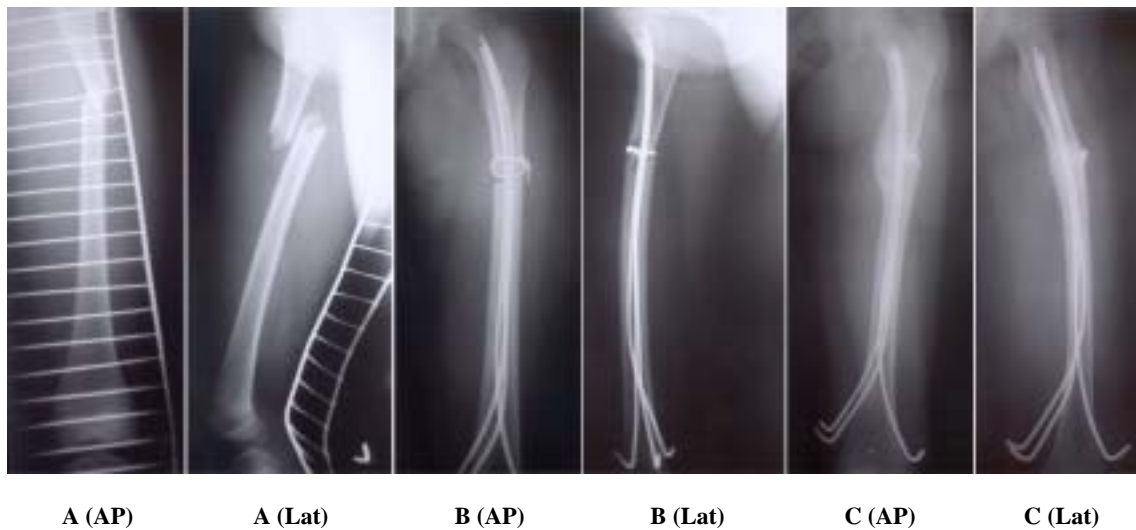


Fig. 3. Serial radiograph of 7 year old girl treated by Nancy nail.
3A. Preoperative AP and Lateral radiogram shows transverse fracture at the proximal 1/3 of femur.
3B. Immediate postoperative radiogram presents three inserted nails and 1 circumferential wire.
3C. Post operative 9 months follow up radiogram shows well union feature.

Table 1. The Outcomes of Nancy Nailing

No.	Age/Sex (Year)	Union Time (weeks)	Angulation (°)		LLD (mm)	Complication	Hospital Days
			Coronal	Sagittal			
1	4/M	9	3	4	2	None	21
2	6/M	10	0	0	3	None	14
3	5/F	8	2	0	4	None	13
4	9/M	12	4	4	3	Nail back out	26
5	11/M	11	0	2	-1	None	16
6	5/F	8	3	4	0	None	18
7	7/M	10	2	3	9	None	13
8	8/F	11	4	3	12	Skin irritation	29
9	9/M	13	0	0	2		14
10	6/F	9	2	3	0		16
11	12/M	10	0	0	-2	None	15
12	5/M	8	4	4	2		13
Mean	7.2	9.9			2.83		17.3

가 , , ,

, , Ender 9,11,14) .
가 Ender
4,10,14,15) .
, , 3
, , 6
17) 19) 21) 9,11) . Ligier 14)
가 ,
Skaggs 21) 가
가 , 가 가
33% , 가 가
가 2% .
Ender
가
(Ender) (Nancy) Ender Nancy 가
, Ender Nancy
3,4,6,9,14)
Gregory 5)
1) .
10 16 Mital
Cashman¹⁸⁾ 24~38
2) . , Ligier¹⁴⁾ Nancy
1970 Ender and Simon- 123 7.5 , Carey Galpin³⁾ 9
Weinder Ender
17.3
가
11) .
1979
Nancy Metaizeau Ligier 가
Nancy , ,
Heinrich 6)

가

- 1) **Beaty JH, Austin SM, Warner WC, Canale ST and Nichols L:** Interlocking intramedullary nailing of femoral shaft fractures in adolescents: Preliminary results and complications. *J Pediatr Orthop*, 14: 178-183, 1994.
- 2) **Buckley SL:** Current trends in the treatment of femoral shaft fractures in children and adolescents. *Clin Orthop*, 338: 60-73, 1997.
- 3) **Carey TP and Galpin RD:** Flexible intramedullary nail fixation of pediatric femoral fractures. *Clin Orthop*, 332: 110-118, 1996.
- 4) **Fein LH, Pankovich AM, Spero CM and Brauch HM:** Closed flexible intramedullary nailing of adolescent femoral shaft fractures. *J Orthop Trauma*, 3: 133-141, 1989.
- 5) **Gregory P, Sullivan JA and Herndon WA:** Adolescent femoral shaft fractures: rigid versus flexible nails. *Orthopaedics*, 18: 645-649, 1995.
- 6) **Heinrich SD, Drvaric DM, Darr K and MacEwen GD:** The operative stabilization of pediatric diaphyseal femur fractures with flexible intramedullary nails: A prospective analysis. *J Pediatr Orthop*, 14: 501-507, 1994.
- 7) **Irani RN, Nicholson JT and Chung SM:** Longterm results in the treatment of femoral shaft fractures in young children by immediate spica immobilization. *J Bone Joint Surg*, 58A: 945-951, 1976.
- 8) **Jeon KP, Kang KH, Kim JI, Kim DS, Yoon HK and Kang CW:** Flexible intramedullary nailing for femoral shaft fracture in children. *J. Korean Society of*

- Fractures, 12: 1051-1057, 1999.
- 9) **Keyvan M, Abdeslam K, Georges FP and Henri B:** Closed flexible intramedullary nailing of the femoral shaft fracture in children. *J Pediatric Orthop B*, 6: 198-202, 1997.
 - 10) **Kirby RM, Winkquist RA and Hansen ST:** Femoral shaft fractures in adolescents. A comparison between traction plus cast treatment and closed intramedullary nailing. *J Pediatr Orthop*, 1: 193-197, 1981.
 - 11) **Klaus DP:** Modern trends in internal fixation of femoral shaft fracture in children. A critical review. *J Pediatric Orthop B*, 6: 117-125, 1997.
 - 12) **Kwon JW, Shin SH, Cho WH, Lee WS and Park JH:** Leg length discrepancy after Ender nail fixation in children femoral shaft fracture. *J Korean Society of Fractures*, 13: 172-177, 2000.
 - 13) **Lee SS, Mahar MS and Newton PO:** Ender nail fixation of pediatric femur fractures: a biomechanical analysis. *J Pediatr Orthop*, 4: 442-445, 2001.
 - 14) **Ligier JN, Metaizeau JP, Prevot J and Lascombes P:** Elastic stable intramedullary nailing of femoral shaft fractures in children. *J Bone Joint Surg*, 70-B: 74-77, 1988.
 - 15) **Mann DC, Weddington J and Davenport K:** Closed Ender nailing of femoral shaft fractures in adolescents. *J Pediatr Orthop*, 6: 651-655, 1986.
 - 16) **McCartney D, Hinton A and Heinrich SD:** Operative stabilization of pediatric femoral fractures. *Orthop Clin North Am*, 25: 635-650, 1994.
 - 17) **Miner T and Carroll KL:** Outcomes of external fixation of pediatric femoral shaft fractures. *J Pediatr Orthop*, 20: 405-410, 2000.
 - 18) **Mital MA and Cashman WF:** A fresh ambulatory approach to treatment of femoral shaft fractures in children. A comparison with traditional methods. *J Bone Joint Surg*, 56-A: 285-291, 1974.
 - 19) **Schranz PJ, Gultekin C and Colton CL:** External fixation of fractures in children. *Injury*, 23: 80-82, 1992.
 - 20) **Shapiro F:** Fractures of the femoral shaft in children: the overgrowth phenomenon. *Acta Orthop Scand*, 55: 649-655, 1981.
 - 21) **Skaggs DL, Leet AI, Money MD, Shaw BA, Hale JM and Tolo VT:** Secondary fractures associated with external fixation in pediatric femur fracture. *J Pediatr Orthop*, 19: 582-586, 1999.
 - 22) **Sponseller PD:** Surgical management of pediatric femoral fractures. *AAOS Inst Course Lect*, 51: 361-365, 2002.
 - 23) **Stsheli LT:** Femoral and tibial growth following femoral shaft fracture in childhood. *Clin Orthop*, 55: 159-163, 1967.
 - 24) **Wallace ME and Hoffman EB:** Remodelling of angular deformity after femoral shaft fractures in children. *J Bone Joint Surg*, 74-B: 765-769, 1992.
 - 25) **Ziv I, Blackburn N and Rang M:** Femoral intramedullary nailing in growing child. *J Trauma*, 24: 432-434, 1984.

Abstract**Nancy Nail Fixation for Femur Shaft Fracture in Children**

**Ki-Do Hong, M.D., Sung-Sik Ha, M.D., Nam-Sik Chung, M.D.,
Jae-Cheon Sim, M.D., Jae-Young Kim, M.D.**

Department of Orthopedic Surgery, Seoul Adventist Hospital, Seoul, Korea

Purpose: To investigate, the radiologically, the duration of bone union, angular formation, leg length discrepancy, other complications and mean hospital stay after Nancy nail fixation has been performed in children with femoral shaft fracture, and also to inquire into the clinical validity of such procedure.

Material and Method: Included in this study were 12 patients who had been treated with the Nancy nail fixation for the femoral shaft fracture and then followed up for a year or more. The age distribution ranged from 4 to 12 years with mean age 7.2 years. After the fracture was reduced under an imaging intensifier, 2 or 3 Nancy nails were pinned onto the medial and lateral femur distally.

Results: The average duration for complete union was 9.9 weeks. Any angular formation over 5° was notfound. Leg length discrepancy ranged from 2 mm shortening to 12 mm overgrowth with a mean value of 2.8 cm. In one case, with overgrowth over 10 mm or more, there was no gait disturbance.

In all cases, There was neither infection, delayed union, nor any motion disturbance. A nail was moved distally in one case and skin irritation was evident in another case. The mean hospital stay was 17.3 days.

Conclusion: Nancy nail fixation in pediatric femoral shaft fracture relatively has less complications and is a safe surgical procedure. In addition, it helps in reducing hospital stay.

Key Words: Children, Femur fracture, Nancy nail

Address reprint requests to _____

Nam-Sik Chung

29-1 Hwikyong 2-Dong, Dongdaemoon-Ku, Seoul, Korea

Department of Orthopedic Surgery, Seoul Adventist Hospital

Tel : +82-02-2210-3581, Fax : +82-02-2217-1897

E-mail : oskgy@hotmail.com