

< >

:

가

: 1992 1 2000 1 66  
(24 ) (42 )

:

42 21.9 , 3.74  
9.74mm 37 5  
24 15.1 , 1.75  
가 7.67mm 17 7

:

가

. Galleazzi

\* 2001

11). 2.

가 6.7).

1 1-2  
4 1 가 2  
4  
2  
4 2  
2

1.  
1992 1 2000 1  
3  
1  
66 3.  
66 1  
40 , 26 42.9  
38 , 17 ,  
10 , 1 .  
0.05 가 T-  
(Table 2).

가  
Frykman  
I 13 ( 6 / 7 ),  
II 15 ( 5 / 10 ), III 9 ( 3 / 6 ), IV  
3 ( 1 / 2 ), V 2 ( 1 / 1 ), VI 6 ( 1 /  
5 ), VII 12 ( 5 / 7 ), VIII 6 ( 2 / 4 ) .  
(Fig. 1A),  
16 26 (Fig. 2A)  
18 , 6  
가 17 4 가 22 ,  
(Table 1).  
20  
24  
15.1 , 7.67mm,

**Table 1.** Case analysis

Treatment Modality	Frykman Classification								Total
	I	II	II	IIV	V	VI	VII	VIII	
Conservative	6	5	3	1	1	1	5	2	24
Operative	7	10	6	2	1	5	7	4	42
CR/P *	5	3	2		1	1	3	1	16
CR/E †		2				1	1	1	5
CR/P/E ‡	1	5	3	1		2	3	2	17
ORIF/P §	1		1	1		1			4

\* close reduction with percutaneous K-wire fixation

† close reduction with external fixator fixation

‡ close reduction with percutaneous K-wire fixation and external fixator fixation

§ open reduction internal fixation with plate

**Table 2.** Result of the treatment

	RI(°) †	RL(mm) ‡	VT(°) §	DRUJ(case/%)
Conservative Treatment	15.1	7.67	1.75	17(79)
Operative Treatment	21.9	9.74	3.74	37(88)
P value ¶	0.00	0.00	0.16	0.08

\* RI, RL and VT are the Mean Value

† radial inclination

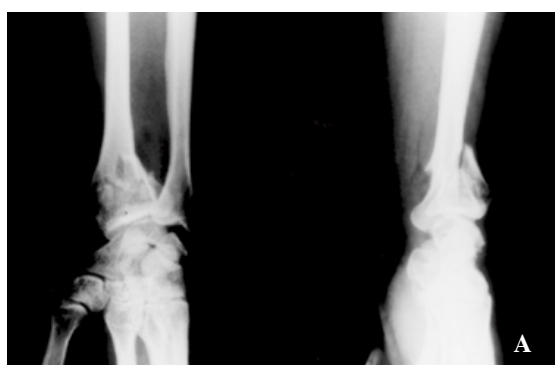
‡ radial length

§ volar tilt

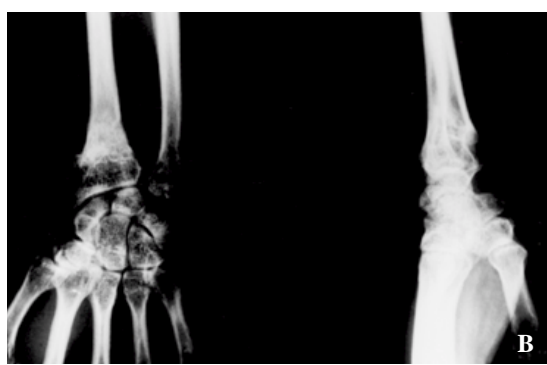
¶ anatomical reduction of distal radio-ulnar joint

¶ P value &lt; 0.05

24 17 1.75 7 P value 0.08  
 7† 0.05  
 (Fig. 1B), , , 0.16 T- P value  
 (Table 2).  
 21.9 , 42  
 9.74mm, 3.74 37  
 (Fig. 2C), 5  
 (Table 2).  
 , T-



**Fig. 1A.** Anteroposterior and lateral radiograph the right wrist of a 66-year-old man  
The fracture was combined with the DRUJ subluxation



**Fig. 1B.** Last follow up radiograph ( post-trauma 12 months)  
The fracture showed bony union, but DRUJ subluxation was remained

6,12)

가

565

가

8). Cooney<sup>3,4)</sup>  
31%

가

100

86%

25

10mm

Knirk Jupiter<sup>8)</sup>, Bradway <sup>2)</sup>

20

10mm

가

10

, 5mm

Strehle

Gerber<sup>14)</sup>Reckling<sup>10)</sup>

가

5mm

20 -30

Adams<sup>1)</sup>

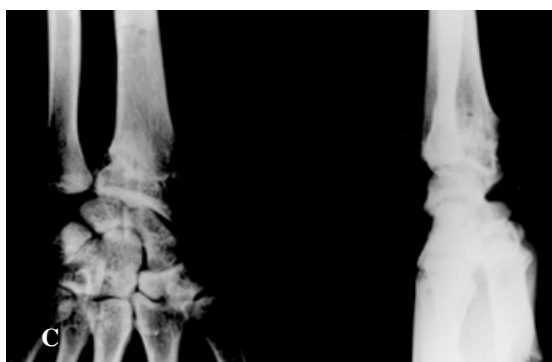
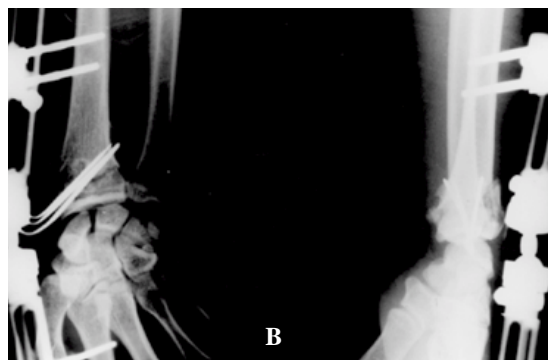
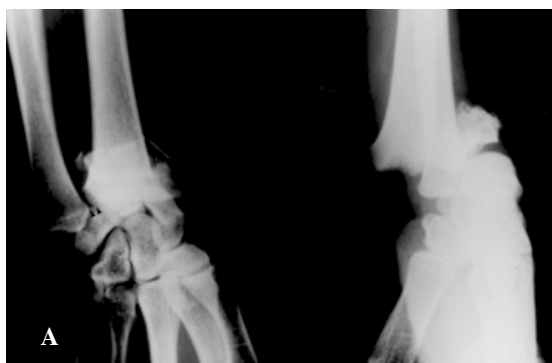
Fernandez

, Melone

Frykman  
, AO

, Jupiter

가



**Fig. 2A.** Anteroposterior and lateral radiograph  
: the right wrist of a 52-year-old man  
The fracture was extended to the DRUJ and  
combined with DRUJ subluxation

**Fig. 2B.** Immediate postoperative radiograph  
K-wire and external fixator fixation after close  
reduction

**Fig. 2C.** Postoperative 14 months radiograph  
The fracture showed bony union and DRUJ  
subluxation was not found

(MRI)

Thomas Susan<sup>16)</sup>

Jupiet

Masen<sup>7)</sup>, Lindstrom<sup>9)</sup>

. Fernandez<sup>5)</sup>, Short<sup>13)</sup>, Taleisnik

Watson<sup>15)</sup>

가

가

## REFERENCES

- 1) **Adams B** : Effects of radial deformity on distal radioulnar joint mechanics. J Hand Surg, 18A:492-498,1993.
- 2) **Bradway J, Amadio P and Cooney W** : Open reduction and internal fixation of Displaced, Comminuted Intra-articular fractures of the distal end of the radius. J Bone Joint Surg, 6A:209-219,1989.
- 3) **Cooney W** : External fixation of Distal Radius Fractures. Clin orthop, 214:136-147,1987.
- 4) **Cooney W, Dobyns J and Linscheid R** : Complication of Colles 'fractures. J Bone Joint Surg, 62A:613-619,1980.
- 5) **Fernandez D** : Reconstructive procedures for malunion and traumatic arthritis. Orthop Clin North Am, 24:341-363,1993.
- 6) **Jupiter J and Lipton H** : The operative treatment of intra-articular fractures of the distal radius. Clin Orthop, 292:48-61,1993.
- 7) **Jupiter J and Masen M** : Reconstruction of post-traumatic deformity of the distal radius and ulna. Hand Clinics, 4:377-390,1988.
- 8) **Knirk J and Jupiter J** : Intra-articular fractures of the distal end of the radius in young adults. J Bone Joint Surg, 68A:647-659,1986.
- 9) **Lindstrom** : Fractures of the distal radius. Acta Orthop Scand, 41(supple):1-118,1959.
- 10) **Reckling F** : Unstable fracture-dislocation of the forearm (Monteggia and Galeazzi lesions). J Bone Joint Surg, 64A:857-863,1982.
- 11) **Saffer P** : Current trends in treatment and classification of distal radius fractures, in Saffer P, Cooney WP : Fracture of the Distal Radius . London , England, Martin Dunitz, 12-18, 1995.
- 12) **Schwind F, Donkerwolcke M, Rasquin C and Burny F** : External fixation of fractures of the distal radius: A Study of 225 Cases. J Hand Surg, 14A:404- 407,1989.
- 13) **Short S, Palmer A, Werner F and Murphy D** : A biomechanical study of distal radial fractures. J Hand Surg, 12A:529-534,1987.
- 14) **Strehle J and Gerber C** : Distal radioulnar joint function after Galeazzi fracture-dislocations treated by open reduction and internal plate fixation. Clin Orthop, 293:240-245,1993.
- 15) **Taleisnik J and Watson H** : Midcarpal instability caused by malunited fractures of the distal radius. J Hand Surg, 9A:325-340,1994.
- 16) **Thomas ET, Susan RS** : Factors affecting functional outcome of displaced intra-articular distal radius fractures. J Hand Surg, 19A:325-340,1994.

Abstract

## The significance of distal radioulnar joint injury in distal radius fracture

Jin-Woo Kwon, M.D., Sung-Ho Shin, M.D.,  
Won-Ho Jo, M.D., Dong-Hyun Kim, M.D

*Department of Orthopedic Surgery, Sunrin Hospital, Handong University, Korea*

**Purpose :** To evaluate the effectiveness of operative treatment in distal radius fracture

with distal radioulnar joint injury.

**Material and Method :** From January 1992 to January 2000, 66 cases of distal radius fracture with distal radioulnar joint injury who had been treated with conservative or operative methods were analyzed the final state of radius articular surface and distal radioulnar joint.

**Result :** In operatively treated cases(42 cases), the average of volar tilt was 3.74°, ulnar inclination 21.9°, radial length 9.74mm. In conservatively treated cases(24 cases),

The average of volar tilt was 1.75°, ulnar inclination 15.1°, radial length 7.67mm.

The state of distal radioulnar joints were as follows; In operatively treated cases, anatomical reduction 37(88%), joint widening 5, In conservatively treated cases, anatomical reduction 17(70%), joint widening or ulnar impingement syndrome 7.

**Conclusion :** In treatment of distal radius fracture with distal radioulnar injury, operative treatment is probably more effective in restoration of radius articular surface and distal radioulnar joint healing.

**Key Word :** Distal radius fracture, Distal radioulnar joint injury, Treatment

Address reprint requests to \_\_\_\_\_

Kwon Jin Woo

69-7 Taesindong Pookgoo Pohang

Department of Orthopedic Surgery, Sunrin Hospital, Handong University, Korea

Tel : 053-245-5161 Fax : 053-245-5311

E-mail : orthkwon@sunlin.com