

가

<	>
:	:
가	:
: 1995 6	1999 10
5	:
가	:
: 13 24	5 4 7mm
slippage	16
:	1
:	가
:	:
:	:

가 , 가

가 momentum arm
가 ㄱ. ,

: 62

가
TEL : 02-3779-1192
FAX : 02-783-0252
E-mail : cmcos@cmc.cuk.ac.kr

* 2001

10-16%

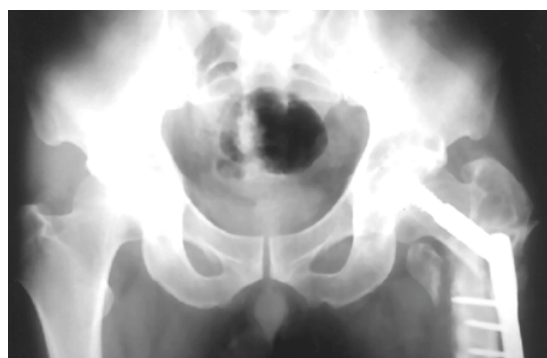

Fig 1. Anteroposterior radiograph of the both hip. At the time of initial nonunion state, there are screw failure and nonunion

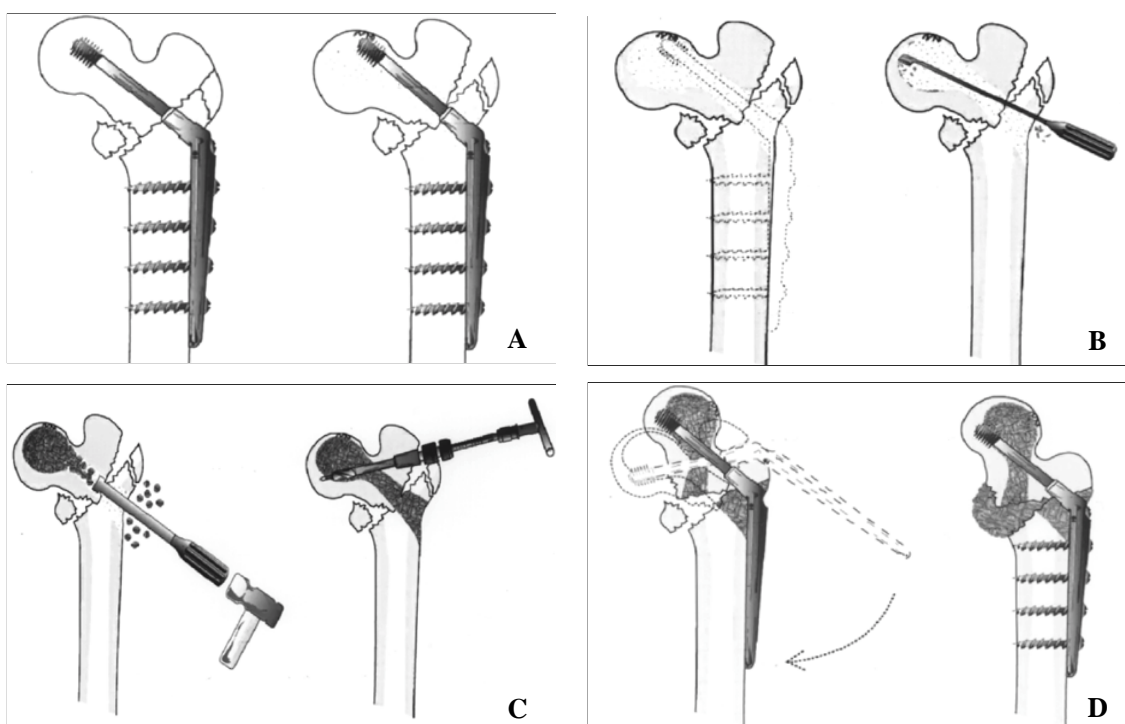


Fig 2. A. Schematic operation, (left) At the time of initial operation after femoral intertrochanteric fracture, fixation is done with compression hip screw. (right) At the time of follow-up, there are nearly penetration of screw, bony resorption and nonunion.

B. Schematic operation, (left) Initially fixated screw is removed. (right) With curet, fibrous tissue and necrotic bone fragment around the nonunion site are completely removed.

C. Schematic operation, (left) Cancellous allograft are impacted in the bony defect site with bone impactor. (right) Guide pin is inserted into the femur in valgus position.

D. Schematic operation, (left) Compression hip screw is inserted. (right) compression hip screw is fixated in nonunion site with autograft.

5, 72cc, guide pin 가 (Fig. 2C).

가 (Fig. 2D).

1995 6 1999 10 가 (Fig. 3A), 13 24

5 가 4 18

38 5 75 60.4 slippage 4 7mm

AO (Fig 3B,C), 1

, A2.2 3, A3.3 1 A1.2 1 Singh Index

2, 2 1 가 barrel

2, pulling off 가 2, 가

가 4

(4.2 cm) 16 0.8cm

(Fig. 1, 2A), 가 (Fig. 2B), 가

cancellous allograft (Pacific Ocean Bone Bank, USA)

bone impactor 1, 13,22), 1 % 2 % 3,19,21,24).

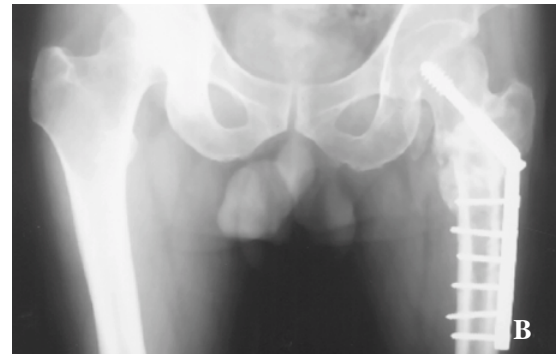
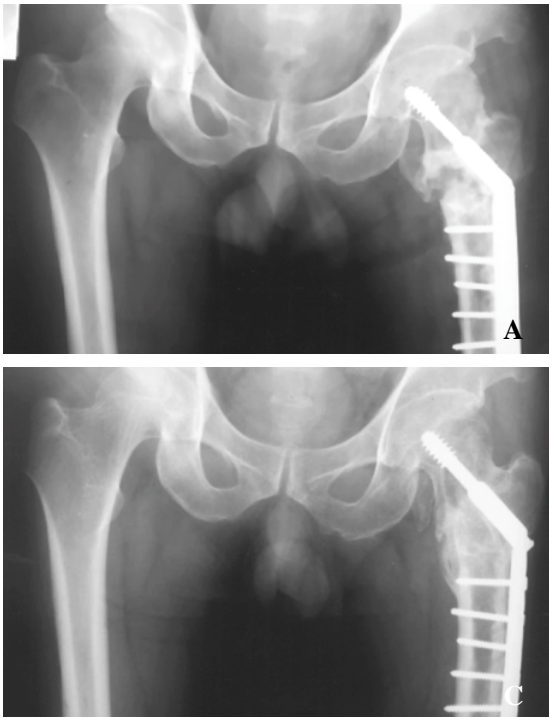


Fig 3. A. Anteroposterior radiograph of the both hip. At the time of reoperation, impacted cancellous allograft, valgus fixation and autograft are done.

B. Anteroposterior radiograph of the both hip. At the time of 12 weeks follow-up, there is callus formation in nonunion site.

C. Anteroposterior radiograph of the both hip. At the time of 14 months follow-up, there is complete bony union in nonunion site.

가 가 ,
가 (slippage)
가 가
6,9,23), 11),
15) 가 6,15,17,23)
2 , pulling off
가 2 , 1 가 21
, 가 가 ,
(calcar femorale)
3,5,12), Mariani Rand
20 19
19). Laskin
3
(bony
apposition)
16),
18),
(bony apposition),
. 1957 Boyd Lipinsky 28
3). 1960 Baker 15
9
1). Kyle
90%
Knight Delee
Mariani Rand
13),
12),

18). 가
1987 Mariani Rand
5
, 13 24 가
4 18)
1935 Pauwels
20),
가 (shearing force)
(compression force)
2,14,20)
4,10),
38 75 5 가
, 4
,
8). , bone 가
impactor

REFERENCE

- 1) **Baker HR** : Ununited intertrochanteric fractures of the femur. Clin. Orthop, 18:209-219, 1960.
- 2) **Bombelli R** : Structure and function in normal and abnormal hips. Berlins, Spring-Verlag: 1-180, 1993.
- 3) **Boyd HB and Lipinsky SW** : Nonunion of trochanteric and subtrochanteric fractures. Surg. Gynecol Obstet, 104:463, 1957.
- 4) **Callaghan JJ, Salvati EA, Pellicci PM, Wilson PD and Ranawar CS** : Results of revision for mechanical failure after cemented total hip replacement, 1979 to 1982. J Bone Joint Surg, 67-A: 1074-1085, 1985.
- 5) **Coran AG, Banks HH, Aliapoulios MA and Wilson RE** : The management of pathologic fractures

- in patients with metastatic carcinoma of the breast. Surg. Gynecol Obstet, 127:1225-1230, 1968.
- 6) **Davis TRC, Sher JL, Horsman A, Simpson M, Parter BB and Checketts RG** : Intertrochanteric femoral fractures. Mechanical failure after internal fixation. J Bone Joint Surg, 72-B: 26-31, 1990.
 - 7) **Flores LA, Harington LJ and Martin H** : The stability of intertrochanteric fractures treated with a sliding screw plate. J Bone Joint Surg, 72-B: 37-40, 1990.
 - 8) **Gross AE, Garbuz D and Morsi ES** : Acetabular allografts for restoration of bone stock in revision arthroplasty of the hip. Instructional Course Lectures, No. 45. AAOS 135-142, 1996.
 - 9) **Hardy DCR, Descamps PY, Krallis P, Fabeck L, Smets P, Bertens SL and Delince PE** : Use of an intramedullary hip-screw compared with a plate for intertrochanteric femoral fractures. A prospective randomized study of one hundred patients. J Bone Joint Surg, 80-A: 618-630, 1998.
 - 10) **Hungerford DS and Jones LC** : The rationale of cementless revision of cemented arthroplasty failure. Clin Orthop, 235: 12-24, 1988.
 - 11) **Jensen JS** : Classification of trochanteric fractures. Acta Orthop Scand, 51: 803-810, 1980.
 - 12) **Knight WM and DeLee JC** : Nonunion of intertrochanteric fractures of the hip: A case study and review. Orthop. Trans, 16:438, 1982.
 - 13) **Kyle RF** : Intertrochanteric fractures. In: Chapman MW ed. Operative orthopaedics, Philadelphia, JB. Lippincott: 353-359, 1988.
 - 14) **Langlais F, Roure JL and Maquet P** : Valgus osteotomy in severe osteoarthritis of the hip. J Bone Joint Surg, 61-B: 424-431, 1979.
 - 15) **Laros GS and Moore JF** : Complications of fixation in intertrochanteric fractures. Clin. Orthop, 101:110-119, 1974.
 - 16) **Laskin RS, Gruber MA and Zimmerman AJ** : Intertrochanteric fractures of the hip in the elderly: A retrospective analysis of 236 cases. Clin. Orthop, 141:188-195, 1979.
 - 17) **Madsen JE, Naess L, Aune AK, Alho A, Ekeland A and Stromsoe K** : Dynamic hip screw with trochanteric stabilizing plate in the treatment of unstable proximal femoral fractures. A comparative study with the Gamma nail and compression hip screw. J Orthop Trauma, 12-4: 241-248, 1998.
 - 18) **Mariani EM and Rand JA** : Nonunion of intertrochanteric fractures of the femur following open reduction and internal fixation. Clin. Orthop, 218:81-89, 1987.
 - 19) **Mariani EM and Rand JA** : Subcapital fractures after open reduction and internal fixation of intertrochanteric fractures of the hip. Clin. Orthop, 245:165-168, 1989.
 - 20) **Marti RK, Schuller HM and Raaymakers ELFB** : Intertrochanteric osteotomy for nonunion of the femoral neck. J Bone Joint Surg, 71-B: 782-787, 1989.
 - 21) **Mulholland RC and Gunn DR** : Sliding screw plate fixation of intertrochanteric femoral fractures. J. Trauma, 12:581-591, 1972.
 - 22) **Sarmiento A** : Intertrochanteric fractures of the femur: 150-degree-angle nail-plate fixation and early rehabilitation: A preliminary report of 100 cases. J Bone Joint Surg, 45-A: 706-722, 1963.
 - 23) **Simpson AHRW, Varty K and Dodd CAF** : Sliding hip screw. Modes of failure. Injury, 20-4: 227-231, 1989.
 - 24) **Wilson HJ, Rubin BD, Helbig FEJ, Fielding JW and Unis GL** : Treatment of intertrochanteric fractures with Jewett nail: Experience with 1,015 cases. Clin. Orthop, 148:186-191, 1980.

Abstract

Impacted Cancellous Allograft and Valgus Fixation of Intertrochanteric Fracture Nonunion

Soon-Yong Kwon, M.D., Young-Kyun Woo, M.D., Jong-Min Sohn, M.D.,
Jin-Hwa Chung, M.D., Jung-Ho Lee, M.D., and Yong-Sik Kim, M.D.

*Department of Orthopedic Surgery, ST. Mary 's Hospital,
The Catholic University of Korea, Seoul, Korea*

Purpose : The aim of this study was attempted to evaluate the effects of impacted cancellous allograft and valgus fixation in the management of nonunion of intertrochanteric fracture of the femur.

Materials and Methods : Between June 1995 and October 1999, 5 patients, ranging from 38 to 75 years of age, with nonunion of femoral intertrochanteric fracture, whose primary treatment had been done with compression hip screws, were treated with impacted cancellous allograft and valgus fixation

Results : After follow-up from 13 months to 24 months, among the 5 cases, 4 cases resulted in the union in a mean time of 16 weeks, improvement of LLD in a mean length of 0.8cm and good function of abduction, but 1 case resulted in nonunion, followed by total hip arthroplasty.

Conclusion : For patients with nonunion of femoral intertrochanteric fracture, impacted cancellous allograft and valgus fixation provide a good result of union.

Key Words : Femoral intertrochanteric fracture, Nonunion, Impacted cancellous allograft Valgus fixation,