

14, 3, 2001 7

The Journal of the Korean Society of Fractures
Vol.14, No.3, July, 2001

Angulated Blade Plate

.

< >

:

:

30

10

1 가 가
가

20

56 (17-76)

21.4 (12-31)

:

5

가 2

,

:

: , ,

가

,

(compression hip

:

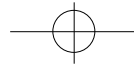
1,

Tel : (02) 958-8364

Fax : (02) 964-3865

E-mail : mcyoo@doctor.com





352 • / 14 3

screw), , , 26 2 4
가 2 1 7
가, 1 7
가 가
가 가 (fracture table)
가 (supine position)
가 (primary tensile trabeculae)
가 (primary compression trabeculae)가
blade (frontal plane)
가 (sagittal plane)
가 (guide pin)
(chisel) (blade)
(plate)

(Fig. 1).

1990 1998 12
95 가 , ,
가 1 가
가 30 가 23 ,
가 7 , 56 (17-76) 가 가 (bridging callus)가
69 (52-87),
49.5 (17-57) 21.4 9
(12-31) 10 , 12
(slip down) 8 , (fall down) 2
, Tronzo III 4 , IV 3 , V (external support)
3 . 9 가 , 1cm , 10 , 15
1 1)
(lag screw)

20 9 ,
5 , 6 Shinsheimer IIA 2 10
4 , IIB 1 , IIIA 6 , IIIB 3 , IV 2 , V 4 0 , 115 ,
1 20 , 37 , 25 , 31 .

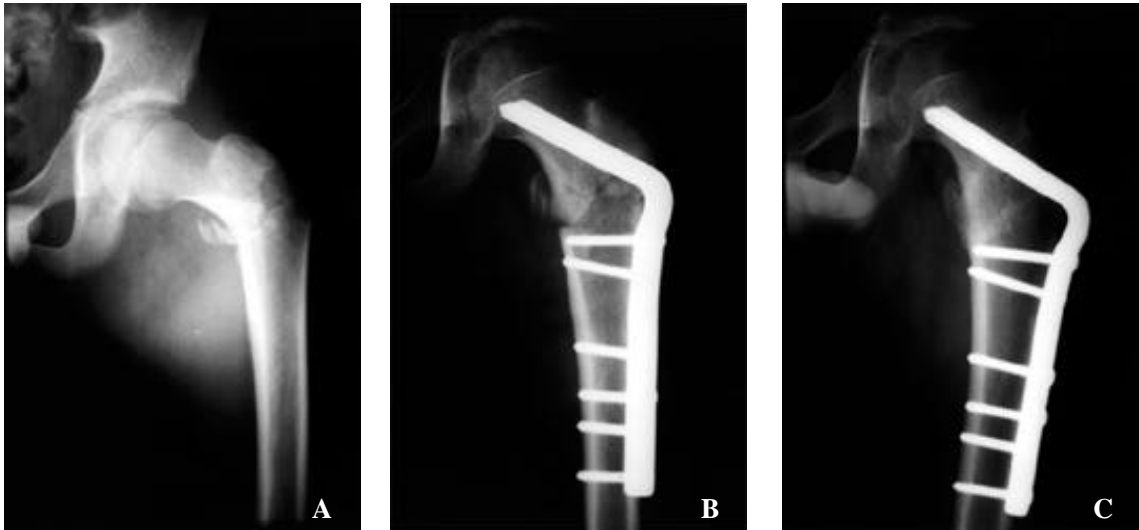
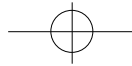
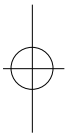


Fig 1. A : Preoperative anteroposterior radiograph shows subtrochanteric fracture of the femur.
 B : Postoperative radiograph shows angulated blade plate fixation with no reconstruction of medial buttress.
 C : Postoperative one year eight month radiograph, the fracture had healed.



5 (3-7)

5

가

가
2

1

Firooznia ⁵⁾

6)

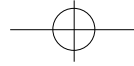
가

가

9,14,17). Hornby ⁸⁾

가





354 • / 14 3

16).

가

- (fixed nail-plate device),

가

가

가가

- (fixed nail-plate device)

2,3),

(tension band)

가

가

15).

가

가

가

가

. Kinast 10)

95

(reverse

obliquity)

(extensive visualization)

(piriformis fossa)

11).

(indirect reduction)

5cm

(isthmus)

가

(tabeculae

가

orientation)

가

(primary tensile trabeculae)

(primary compression trabeculae)가

가

(resistance)

(purchase)

(frontal

plane)

(sagittal

plane)

. Brien 1)

95

10mm

, 130

6-8mm

가

95

12).

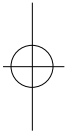
(fixed angle device)

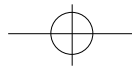
(torsion)

(bending)

가

(blade entry),





(long axis of femoral shaft)

¹²⁾

가

가

2

¹²⁾(Fig. 2).

REFERENCES

- 1) **Brien WW, Wiss DA, Becker V Jr. and Lehman T** : Subtrochanteric femur fractures: a comparison of the Zickel nail, 95 degree blade plate, and interlocking nail. *J Orthop Trauma*, 5:458-464, 1991.
- 2) **Chapman MW, Bowan WE, Csongradi JJ, Day LJ, Trafton PG and Bovill EC** : The use of Ender 's pins in extracapsular fractures of the hip. *J Bone and Joint Surg*, 63A:14-28, 1981.
- 3) **Cram RH** : The unstable intertrochanteric fracture. *Surg Gyneco Obstet*, 101:15-19, 1955.
- 4) **Fielding JW, Cochran GVH, Zickel RE** : Biomechanical characteristics and surgical management of subtrochanteric fractures. *Orthop Clin North Am*, 5:629-250, 1974.
- 5) **Firooznia H, Raffi M, Golimbu C, Schwartz MS and Ort P** : Trabecualr mineral content of the spine in women with hip fracture: *CT measurement*. *Radiology*, 159:737-740, 1986.
- 6) **Hall G and Ainscow DAP** : Comparison of nail-plate fixation and Ender 's nailing for intertrochanteric

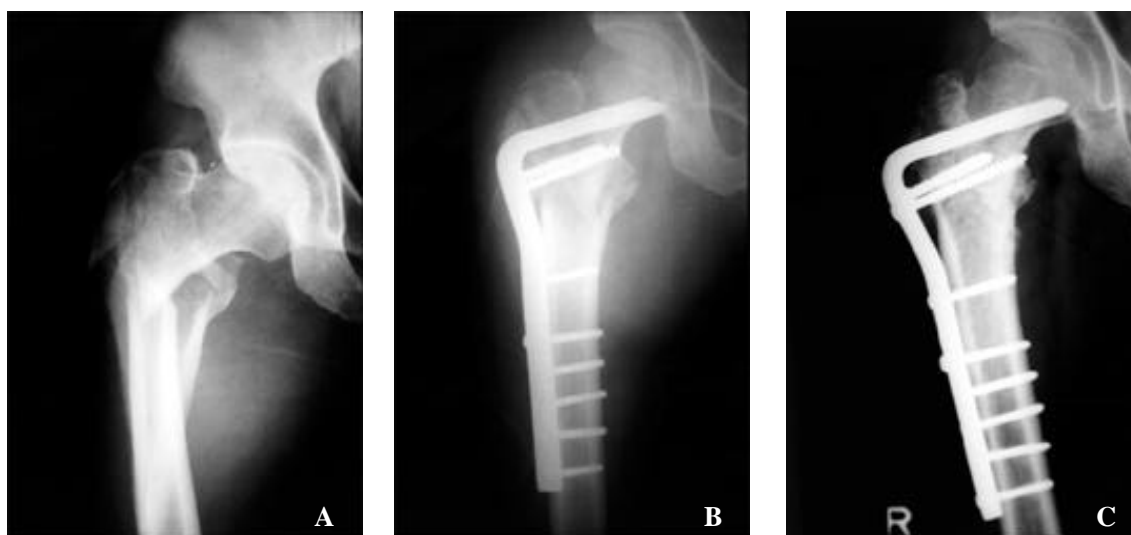
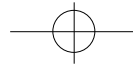


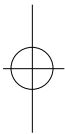
Fig 2. A: Preoperative anteroposterior radiograph shows intertrochanteric fracture of the femur.

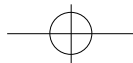
B : At postoperative radiograph, fracture reduction and fixation was obtained with the angulated blade plate with no reconstruction of medial buttress.

C : At postoperative one year four month radiograph, the fracture had healed completely.



- fractures. *J Bone and Joint Surg*, 63B:24-28, 1981.
- 7) **Heiple KG, Brooks DB, Samson BL and Burstein AH** : A fluted intramedullary rod for subtrochanteric fractures: Biomechanical considerations and preliminary clinical results. *J Bone Joint Surg*, 61A:731-737, 1979.
 - 8) **Hornby R, Grimleyevans J and Vardon V** : Operative or conservative treatment for trochanteric fractures of the femur. A randomised epidemiological trial in elderly patient. *J Bone and Joint Surg*, 71B:619-23, 1989.
 - 9) **Hughston JC** : Intertrochanteric fracture of the femur(Hip). *Clin North Am*, 5:585-594, 1974.
 - 10) **Kinast C, Bolhofner BR, Mast JW and Ganz R** : Subtrochanteric fractures of the femur. Results of treatment with the 95 degree condylar blade-plate. *Clin Orthop*, 238:122-130, 1989.
 - 11) **Lee SH, HA SH and Rowe YS** : The use of gamma nail in peritrochanteric fractures of femur. *J Korean Orthop Assoc*, 27:989-994, 1992.
 - 12) **Muller ME, Allgower M, Schneider R and Willenegger H** : Mannual of internal fixation. 3rd ed, Springer-Verlag:252-266, 1990.
 - 13) **Rybicki EF, Simonen FA and Weis EB Jr** : On the mathematical analysis of stress in the human femur. *J Biomech*, 5:203-215, 1972.
 - 14) **Sarmiento A and Williams EM** : The unstable intertrochanteric fracture. Treatment of valgus osteotomy and I-Beam nail plate. *J Bone and Joint Surg*, 52A:1309-1318, 1970.
 - 15) **Seinsheimer F III** : Subtrochanteric fractures of the femur. *J Bone Joint Surg*, 60A:300-306, 1978.
 - 16) **Tencer AF, Johnson KD, Johnston DWC and Gill K** : A biomechanical comparison of various method of stabilization of subtrochanteric fractures of the femur. *J Orthop Res*, 2:297-305, 1984.
 - 17) **Tronzo RG** : Special consideration in management. *Orthop Clin North Am*, 5:571-583, 1974.





Abstract

Treatment of Peritrochanteric Fracture of Femur with Angulated Blade Plate

Myung Chul Yoo, M.D., Yoon Je Cho, M.D., Kang Il Kim, M.D.,
Young Soo Chun, M.D., Chang Hyeok Kwon, M.D., Dong Jun Shin, M.D.

*Department of Orthopedic Surgery, School of Medicine,
Kyung Hee University, Seoul, Korea*

Purpose : To clarify the efficacy of angulated blade plate fixation in the treatment of complex peritrochanteric fracture of femur.

Materials and Methods : Thirty peritrochanteric fractures treated with angulated blade plate, with a follow-up period of more than twelve months, were included. There were twenty subtrochanteric fractures and ten intertrochanteric fractures in which compression hip screw could not be applied due to comminution of trochanteric area. Average age was fifty six years(range, 17 to 76). Average follow-up period was 22.4 months(range, 12 to 31).

Results : Average time to bony union for those fractures that healed primarily was 5 months. Solid union occurred in all cases with two malunion. Infection, implant failure, femoral head protrusion was not occurred.

Conclusion : Angulated blade plate can be a useful alternative for the fixation of comminuted peritrochanteric fracture if appropriate fixatives are not available.

Key word : Peritrochanteric Fracture, Angulated Blade Plate

Address reprint requests to _____

Myung Chul Yoo
1 Hoegi-dong, Dongdaemun-ku, Seoul, Korea.
Department of Orthopaedic Surgery, School of Medicine,
Kyung Hee University
Tel : 02-958-8364
Fax : 02-964-3865
E-mail : mcyoo@doctor.com