

13, 4, 2000 10

The Journal of the Korean Society of Fractures  
Vol.13, No.4, October, 2000

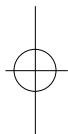
-1 -

.

&lt; &gt;

1

: , ,



0.5% 34 가 1

1,6,9)

2%

1)

6)

가 130 , 150 , 40

1

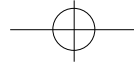
(Fig.1) 10mm × 5mm

:

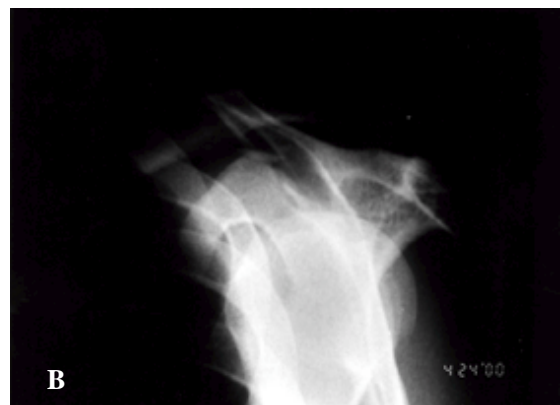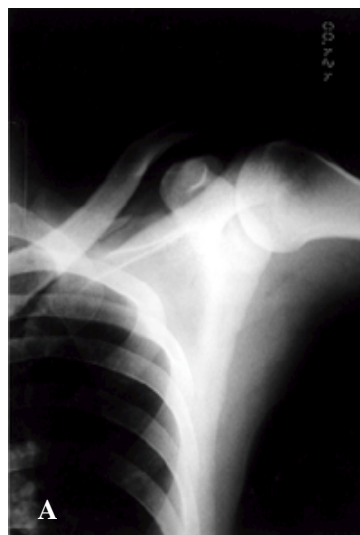164

Tel : (02) 2002-8390  
Fax : (02) 2002-8399  
E-mail : baramksd@lycos.co.kr



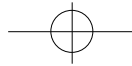


37가  
3).  
가 Brindle McAtee가 1998 1999  
3  
2,6).  
가 . Ogawa  
1974 1994  
0.5% 24  
3  
1,6,9).  
2%  
1).  
4). 3  
Binazzi 8  
Moore 7  
1) Heyse-  
가 8).  
가



**Fig 1A.** Anteroposterior radiograph of left shoulder shows minimally displaced small fracture fragment of the superior border of the scapula.

**1B.** Translateral radiograph of left shoulder shows displaced fracture fragment of the superior border of the scapula.



. Houghton

2

4). Ishizuki 1

가

가

5). Williamson 1

가

1988

3

4

가

8).

가

8).

1

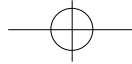
가

2).

1-9)

## REFERENCES

- 1) **Binazzi R, Assiso J, Vaccari V, Felli L** : Avulsion fractures of the scapula; Report of eight cases. *J Trauma*, 33(5); 785-790, 1992.
- 2) **Brindle TJ, Coen M** : Scapular avulsion fracture of a high school wrestler. *J Orthop Sports Phys Ther*, 27(6): 444-447, 1998.
- 3) **Heyse-Moore GH, Stoker DJ** : Avulsion fracture of the scapula. *Skeletal Radiol*, 9(1): 27-32, 1982.
- 4) **Houghton GR** : Avulsion of the cranial margin of the scapula; A report of two cases. *Injury*, 11;45-46, 1980.
- 5) **Ishizuki M, Yamaura I, Isobe Y et al.** : Avulsion fracture of the superior border of the scapula; Report of five cases. *J Bone Joint Surg*, 63-A: 820-822, 1981.
- 6) **McAtee SJ** : Low-energy scapular body fracture: a case report. *Am J Orthop*, 28(8): 468-472, 1999.
- 7) **Ogawa K, Yoshida A** : Fracture of the superior border of the scapula. *Int Orthop*, 21 (6): 371-373, 1997.
- 8) **Williamson DM, Wilson J** : Bilateral avulsion fractures of the cranial margin of the scapula. *J Trauma*, 28(5); 713-714, 1983.
- 9) **You JW, Yoon HJ** : Conservative treatment of scapular fracture. *The Journal of the Korean Society of Fractures*, 7(2): 364-370, 1994.



## Abstract

**Isolated Avulsion Fracture of the Superior  
Border of the Scapula :  
- A Case Report -**

**Suk Woong Yoon M.D., Sang Deog Kim M.D.**

*Department of Orthopaedic Surgery, Seoul Red Cross Hospital, Seoul, Korea*

Avulsion fracture of the scapula by the indirect trauma, especially avulsion fracture of isolated superior border is very rare. We experienced a case of isolated avulsion fracture of the superior border of the scapula and report the clinical and radiographic findings in detail.

**Key Words** : Scapula, Avulsion fracture, Superior border