



13, 4, 2000 10

The Journal of the Korean Society of Fractures  
Vol.13, No.4, October, 2000

## Reconstruction plate

. . .

&lt; &gt;

:

reconstruction plate

가

: 1993 1

1997 12

5

가 11mm

reconstruction plate

가

1

28

:

7.2

,

26

1.8

:

reconstruction plate

.

:

,

, Reconstruction plate,

,

10).

가

가

,

가

가

가

,

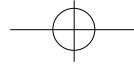
:

37(606-063)

Tel : (051) 410-6846

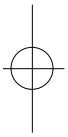
Fax. : (051) 413-7764



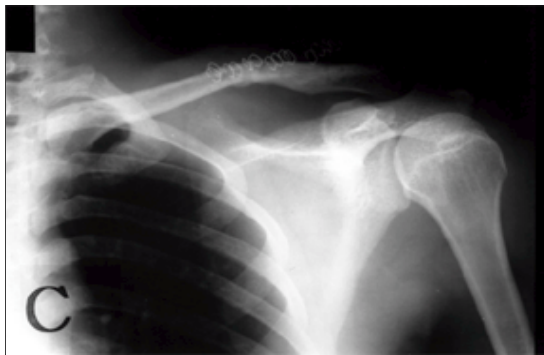
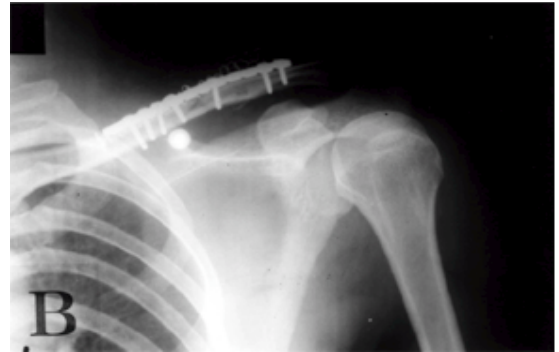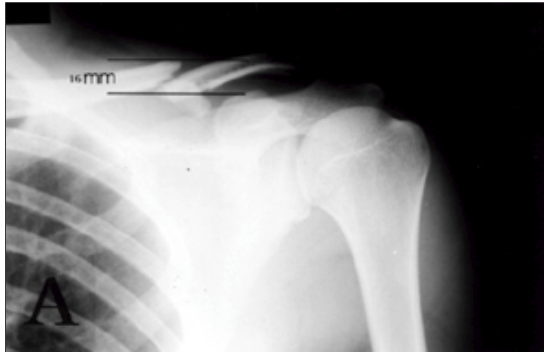


942 • / 13 4

19 ,  
5 , 4 .  
, Steinmann 가 ,  
pin K- 1). 17 , 11 14  
reconstruction plate 가 9 , 3 ,  
가 가 1 , 1 .  
가 가 2 , 11 2.8  
3  
1993 1 1997 12 5 .  
가 11mm reconstruction plate  
reconstruction plate , 가  
가 가  
, 1 가 28 (Fig.1-B,2-B).



2-3 Velpeau ,  
1 가  
1993 1 1997 12 5 .  
reconstruction plate  
42 1 Weitzman<sup>15)</sup> 4가  
가 가 11mm , , , 가  
28 .  
12 ,  
1 , 1 ,  
1 , 4 ,  
1/3 2 1.  
, 4 , 가 28 26  
3 1 가 18 , 3 가 8 1.61 가 .  
가 16 (57.1%), 12  
(42.9%) , 18 62 2.  
20-30 가 15 53.9% 26 (92.8%) 8 , 2 8.4  
18 20 가 3 , 21 30 가 5 , (Fig.1-C, Fig.2-C).  
31 40 가 10 , 41 50 가 6 , 51 2.5 ,  
60 가 2 , 61 2 . 7.2  
16-20mm 가 18 가 3.  
(Fig.1-A,2-A). Weitzman<sup>15)</sup> 가 24



**Fig 1A.** A 22-year old male patient slip down on his hand. Comminuted displaced midshaft fracture occurred. 16mm fracture gap was seen on the clavicle A-Pview.

**1B.** 2 days after trauma, open anatomical reduction and internal fixations with the reconstruction plate ,screws and supplementary iliac bone graft was performed.

**1C.** 6 Months after operation, good union was seen in fracture site.

(85.0%), 3 (10.8%), 1 (0.03%) .

1/3 가

4.

가2

4-6

3  
7,13)

가 1 , 1  
가 가 .

가 ,  
가

가  
가 19 가 .

1/3

가

1/3 , S  
1/3 가

가 ,  
16) 가 , Willkins Johnston<sup>16)</sup>

가

가

가

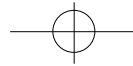
Moseley<sup>6)</sup> 1/3  
, Rockwood<sup>11)</sup>

가

Norris<sup>13)</sup>

140

Stanley  
20



**Table 1.** Average bone union time after operation

Age	No.of cases	Clinical union(weeks)	Radiologic bone union(weeks)
11-20	3	1.2	6.0
21-30	5	1.7	7.2
31-40	10	1.4	7.0
41-50	6	3.5	7.8
51-60	2	4.0	8.4
61-	2	3.2	7.2
	28	2.5	7.2

**Table 1.** Functional results of shoulder motion by Weitzman<sup>15)</sup>

Result	No.of cases(%)
Excellent 24 Painless full rage of motion No weakness or stiffness	(85.0)
Good 3 occasional pain on exertion full range of motion Minimum weakness or stiffness	(10.8)
Fair 1 occasional pain with motion some restriction of motion moderate weakness or stiffness	(3.0)
Poor 0 frequent pain moderate restriction of motion disabling weakness or stiffness	(0.0)

33%  
Post<sup>10)</sup>

reconstruction(malleable) plate  
S, Eskola<sup>1)</sup>

가

Steinmann pin

9-10.7 5). reconstruction plate

7-8

Jupiter    Leffert<sup>2)</sup>  
가

가

(minimum),  
10mm

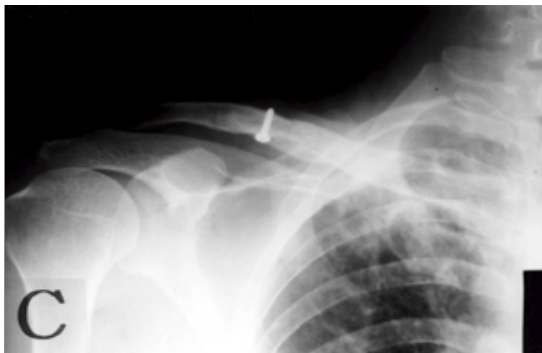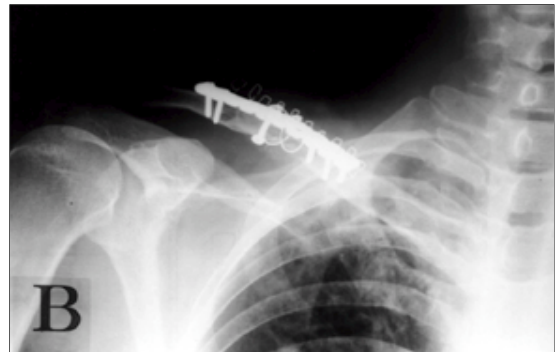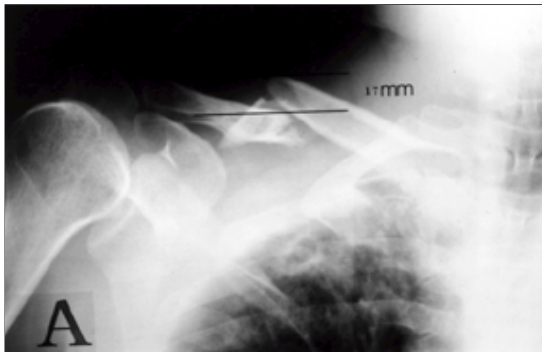
(moderate),      (severe)  
가

가

3)

4)

28



**Fig 2A.** A 53-year old male patient was injured on his right shoulder by direct trauma. Comminuted displaced midshaft fracture occurred. 17mm fracture gap was seen on the clavicle A-P view.

**2B.** 11 days after trauma, open anatomical reduction and internal fixations with the reconstruction plate, screws and supplementary iliac bone graft was performed.

**2C.** 7 Months after operation, good union was seen in fracture site.

8.6 ,  
4 (14.2%)  
14)  
10.8 , 1  
(1.85%) , 28  
7.2 .  
Weitzman<sup>15)</sup>  
3) reconstruction plate , 32  
2  
7 (27 (84.3%)), 4 (12.5%), 1 (3.13%)

reconstruction plate			
	24 (85%),	3 (10.8%),	
1 (3%)	.		

45 2 (4.6%)가  
46  
, Rowe<sup>12)</sup> 0.8%,  
3.7%  
4  
, Paffen Jansen<sup>9)</sup> K-  
3% , 5)

reconstruction plate

reconstruction plate

28

2235 Neer<sup>7)</sup>  
3 (0.1%),

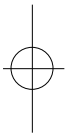
가 11mm



reconstruction plate  
가  
1 가 28  
26 가  
가  
reconstruction plate

## REFERENCES

- 1) **Eskola A** : Surgery for ununited clavicular fracture. *Acta Orthop Scand*, 57:366-367, 1986.
- 2) **Jupiter JB and Leffert RD** : Nonunion of the clavicle. *J Bone Joint Surg*, 69-A : 753-760, 1987.
- 3) **Kang JD, Kim KY, Kim HC and Kang GH** : Operative treatment of the clavicular fracture with reconstruction plate. *J of Korean Orthop Assoc*, 32-1 : 111-115, 1997.
- 4) **Kang CS, Pyun YS, Sohn SW, et al** : Open reduction and internal fixation of clavicular midshaft fracture. *J of Korean Orthop Assoc*, 28-1 : 186-192, 1993.
- 5) **Lee CJ, Cho WH, Chang HG and Min BI** : Operative treatment of the diaphyseal fractures of clavicle (Fresh fracture and symptomatic delayed union or nonunion). *J of Korean Orthop Assoc*, 25-1:117-122, 1990.
- 6) **Moseley HF** : The clavicle : Its anatomy and function. *Clin Orthop*, 58:17-27, 1968.
- 7) **Neer CS** : Fracture of the distal third of the clavicle. *Clin Orthop*, 58:43-50, 1968.
- 8) **Oh HH, Cho YC and Kim YM** : Management of clavicular shaft fracture with open reduction and internal fixation. *J of Korean Society of the Fracture*, 9-4 : 1047-1053, 1996.
- 9) **Paffen PJ and Jansen EWL** : Surgical treatment of clavicular fracture with Kirschner wires : A comparative study. *Arch Chir Nederlandicum*, 30:43-53, 1978.
- 10) **Post M** : Current concepts in the treatment of fracture of the clavicle. *Clin Orthop*, 45:89-101, 1989.
- 11) **Rockwood CA** : Fracture of the clavicle. Vol 1, 4th ed. Philadelphia, *J B Lippincott Co* : 1109-1155, 1996.
- 12) **Rowe CR** : An atlas of anatomy and treatment of mid-clavicular fracture. *Clin Orthop*, 58:29-42, 1968.
- 13) **Stanley D and Norris SH** : Recovery following fracture of the clavicle treated conservatively. *Injury*, 19:162-164, 1988.
- 14) **Wang JM, Roh KJ, Yun YH, Kim DJ and Ji IH** : Intramedullary nailing with Knowles pin for the clavicle shaft fracture. *J of Korean Orthop Assoc*, 31-2 : 211-217, 1996.
- 15) **Weitzman G** : Treatment of acute acromioclavicular joint dislocation by a modified Bosworth method. *J Bone Joint Surg*, 49-A:1167-1178, 1967.
- 16) **Wilkins RM and Johnston RM** : Ununited fracture of the clavicle. *J Bone Joint Surg*, 65-A:773-778, 1983.





## Abstract

## Operative Treatment with the Reconstruction Plate for the Displaced Clavicle Shaft Fracture of Adults

Ig-Gon Kim,M.D.,Jac-Hyek Kim,M.D.,Ryong Hwang,M.D.,Young-Ill Hong,M.D.

*Department of Orthopaedic Surgery,Hae Dong Hospital,Pusan,Korea*

**Purpose :** The purpose of this study was to know the usefulness of bony union and faster recovery of shoulder motions by the open reduction and internal fixation with the reconstruction plate for the displaced clavicle shaft fracture of adults.

**Material and method :** From January 1993 to December 1997, for 5 years, we analyzed 28 cases which underwent for a year of displaced clavicular shaft fracture over 11mm after open reduction and internal fixation with the reconstruction plate and supplementary iliac bone graft.

**Result :** At all 28 cases, there were united without delayed union for average 7.2 weeks after operation. Motion of the shoulder joint were returned to normal within 1.8 weeks except two cases who had combined humerus fracture and partial gastrectomy for peptic ulcer.

**Conclusion :** It seems that operative treatment with the reconstruction plate and supplementary bone graft for the displaced clavicle shaft fracture of adults showed effective union and faster recovery of shoulder motions.

**Key Words :** Clavicle shaft, Displaced fracture, Operative treatment with reconstruction plate, Bone graft