

13, 4, 2000 10

The Journal of the Korean Society of Fractures  
Vol.13, No.4, October, 2000

## AO C2-C3

. .

가

<		>	
: AO C2-C3			
MIPO			
: 1996 1 1997 12 AO C2-C3 22			
, 1) A -MIPO			
(10 ) 2) B - AO (8 ) 3) C - (4 ) 12			
: A 15 B 20 , C 16 ,			
0% B 50%, C 50% A 0-9 가			
100% B 75%, C 50% , Neer 가 A 90% , B 75%			
C 50%			
: AO C2-C3			
MIPO			
:		, AO C2-C3 ,	

가

AO C2-C3

AO ,  
(vastus

, 70-90%

lateralis)

가

:

1198

가

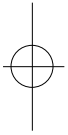
Tel : (032) 460-3384

Fax : (032) 468-5437



862 • / 13 4

가 , , Neer 가 12) .  
 , 가 가 1 2  
 2 ,  
 가 , 가 1 .  
 , A dynamic condylar screw 10 , B  
 2,6,7) May anatomical plate 4 , blade plate 4 , C  
 4 ,  
 minimally invasive plate osteosynthesis(MIPO) , B 6 .  
 , ligamentotaxis, bridge plating  
 AO C2-C3 3.A  
 AO 15-20cm  
 C2-C3 22 .  
 K- ,  
 ,  
 가  
 1. condylar screw .  
 1996 1 1997 12 가  
 AO C2, C3 12 가 가  
 가 22 , 가 9 condylar screw  
 가 13 51.5 . C2 12  
 (54.5%) C3 10 (45.5%) , 가 11 가 4  
 가 3 ,  
 7 가 .  
 2.  
 22 가 cable . (distracter)  
 . A  
 dynamic condylar screw (10 )  
 , B AO , 1  
 (blade dynamic condylar screw  
 plate, May anatomical plate, dynamic condylar screw) (bone cement) 가  
 (8 ) , C Ender nail .  
 (4 ) .  
 ( ( ) ) 4.  
 ( , ) 1 ,  
 , ,





(12.5%), 1 (12.5%), 1  
(12.5%), C  
2 (50%)가 (Table 2).  
2. A  
5. 15 (11-21 ) , B 20 (17-22)  
, C 16 (15-18 ) (Table  
3), A B  
, C  
12 3 (ANOVA test  
Neer A B p 0.004, A C  
가 12 p 0.57). A 10  
12 (100%) 가 , B 6  
(75%) , 2  
(25%) 10  
, C 2 (50 %)  
, 1 (25%) 15  
, 1 (25%) 7  
(Table 4). A  
가가 (Fig. 1).  
3. Neer 가 A 9  
(90%), 1 (10%), . B  
1. A 110  
6 (60%), 90 3 (30%), 90  
가 1 (10%) 111 , B  
가 110 3 (37%),  
90 3 (37.5%), 90 가 2 (25%)  
101 , C 가 110  
1 (25%), 90 1 (25%), 90  
가 2 (50%) 88 , A B C  
ANOVA test A B p  
0.27, A C p 0.19 ,  
(Table 1).  
, A  
, B  
1 (12.5%), 1

**Table 2.** Complications

Complication	A	B	C
Wound infection		1	
Nonunion(infection)		1	
Nonunion(hypertropic)		1	
Malunion *		1	2
Total(%)	0(0%)	4(50%)	2(50%)

\* malunion : angulation > valgus 15 ° or varus 5 ° intraarticular malunion

**Table 1.** Knee ROM

ROM *	A *	B *	C *
< 90 °	1	2	2
90-110 °	3	3	1
> 110 °	6	3	1

\* ROM: range of motion

\* A : DCS fixation using MIPO technique & arthrotomy

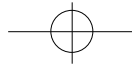
\* B : conventional AO technique

\* C : retrograde supracondylar intramedullary nailing

**Table 3.** Union period

Week	A	B	C
	12	2	
12-18	7	3	4
18-22	1	3	
nonunion		2	
Average	15 wks	20 wks *	16 wks

\* average of 6 cases

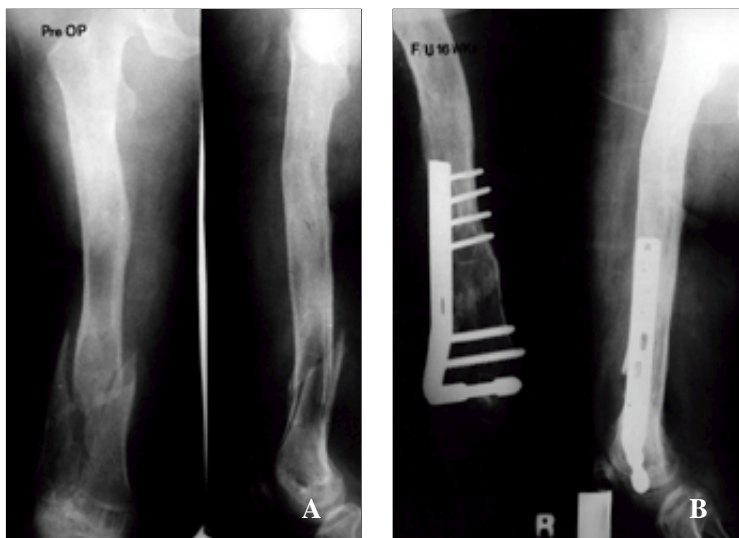
**Table 4.** Radiologic alignment (T-F angle)

T-F angle *	A	B	C
varus >	-1	0	1
valgus 0-9	10	6	2
valgus > 10	2	1	

\* T-F angle : tibio-femoral angle

**Table 5.** Results by Neer rating system

Results	A	B	C
Excellent	3	1	1
Satisfactory	6	5	1
Unsatisfactory	1		2
Failure			2
> Satisfactory	9(90%)	6(75%)	2(50%)

**Fig 1.** Case of the A group

- 1A.** A 57 year-old male patient sustained AO type C2 fracture by traffic accident.
- 1B.** 16 weeks after the operation, bony union was achieved and clinical result was good.

6 (75%), 가 2 (25%) 2) 3)

, C 2 (50%) (Table 5). , A (blade plate, dynamic condylar screw, May anatomical plate ) 가

70-90% 2,6,12,15). AO

AO

, 8,15) , , MIPO 가

4). 1,3,10,11,14,17)

1970 가 가

가 2,6). AO group 1) MIPO , , ,



AO C2-C3

• 865

가 .

Krettek<sup>9)</sup> MIPO

9cm , 가 ,

5,10,11) . AO

가 C2, C3

3) .

MIPO 1990 AO ( )

가 ,

Krettek<sup>8)</sup> Hannover

3,7,9,16,17) . MIPO

AO C2, C3

(vitality) (lateral parapatella arthrotomy)

(transarticular joint

ligamentotaxis, bridge plating , reconstruction) MIPO

ligamentotaxis 가 8

12 가

Neer 가 100%

bridge plating Hannover group

7,9,14) AO C2, C3

dynamic condylar screw, blade plate,

May anatomical plate 가 , AO ,

. Ostrum Geel<sup>13)</sup> 1995 30 / AO C2, C3

supracondylar compression screw, lateral condylar buttress (midline incision) (medial

plate, dynamic condylar screw parapatella incision)

15.3 Neer 가

86.6%

. Krettek<sup>11)</sup> 1997 14 screw MIPO

dynamic condylar

MIPO 12.7 , dynamic condylar screw

가 70% , 가 .

가

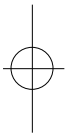
MIPO 가 , 3

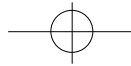


dynamic condylar screw  
blade plate  
가 ,  
MIPO  
가  
가  
.  
AO C2-C3  
MIPO  
dynamic condylar screw A

## REFERENCES

- 1) **Baumgaertel F, Buhl M and Rahn BA** : Fracture healing in biological plate osteosynthesis. *Injury*, 29-3:S-C3-S-C6, 1998.
- 2) **Chiron HS, Tremoulet J, Casey P and Muller M**: Fractures of the distal third of the femur treated by internal fixation. *Clin Orthop*, 100:160-170, 1974.
- 3) **Gerher A and Ganz R** : Combined internal and external osteosynthesis. A biologic approach to the treatment of complex fractures of the proximal tibia. *Injury*, 29-3:S-C22-S-C28, 1998.
- 4) **Guy P, Krettek C, Mannss J, Mech E and Whittall KP** : Geometry of the distal femur. *Injury*, 29-3:S-C16-S-C21, 1998.
- 5) **Helfet DL and Lorich DG** : Retrograde intramedullary nailing of supracondylar femoral fractures. *Clin Orthop*, 350:80-84, 1998.
- 6) **Jeong CH, Kim SS, Joe OW, Lee PC and Hwa DH** : Operative treatment of the supracondylar-intercondylar fracture of the femur. *J of Korean Orthop Surgery*, 28-5:1691-1701, 1993.
- 7) **Krettek C** : Foreword : Concepts of minimally invasive plate osteosynthesis. *Injury*, 28-1:S-A1-S-A2, 1997.
- 8) **Krettek C, Schandelmaier P, Miclau T, Bertram R, Holmes H and Tschern H** : Transarticular joint reconstruction and indirect plate osteosynthesis for complex distal supracondylar femoral fractures. *Injury*, 28-1:S-A31-S-A41, 1997.
- 9) **Krettek C, Schandelmaier P, Miclau T and Tschern H** : Minimally invasive percutaneous plate osteosynthesis(MIPPO) using the DCS in proximal and distal femoral fractures. *Injury*, 28-1:S-A20-S-A30, 1997.
- 10) **Leung KS, Shen WY, So WS, Mui LT, Grosse A and Shatin NT** : Interlocking intramedullary nailing for supracondylar and intercondylar fractures of the distal part of the femur. *J Bone Joint Surg*, 73-A:332-340, 1991.
- 11) **Lucas SE, Seligson D and Henry SL** : Intramedullary supracondylar nailing of femoral fractures. A preliminary report of the GSH supracondylar nail. *Clin Orthop*, 296:200-206, 1993.
- 12) **Neer CS, Grantham SA and Shelton ML** : Supracondylar fracture of the adult femur. A study of one hundred and ten cases. *J Bone Joint Surg*, 49-A: 591-613, 1967.
- 13) **Ostrum RF and Geel C** : Indirect reduction and internal fixation of supracondylar femur fractures without bone graft. *J Orthop Trauma*, 9-4:278-284, 1995.
- 14) **Shahcheragh HG and Reza H** : Supracondylar fracture of the femur: closed or open reduction ? . *J Trauma*, 34-4:499-502, 1993.
- 15) **Shewring DJ and Meggitt BF** : Fractures of the distal femur treated with the AO dynamic condylar screw. *J Bone Joint Surg[Br]*, 74-B:122-125, 1992.
- 16) **Siebenrock KA, Muller U and Ganz R** : Indirect





reduction with a condylar blade plate for osteosynthesis of subtrochanteric femoral fractures. *Injury*, 9-3:S-C7-S-C15, 1998.

17) Wenda K, Runkel M, Degrief J and Rudig L : Minimally invasive plate fixation in femoral shaft fractures. *Injury*, 28-1:S-A13-S-A19, 1997.

#### Abstract

## Comparison of Operative Treatment Methods of AO type C2-C3 Fractures of the Distal Femur

Beom Koo Lee, M.D., In Ho Seong, M.D., Min Ho Song, M.D.

*Department of Orthopaedic Surgery, Gil Medical Center  
Gacheon Medical Collage, Incheon, Korea*

**Purpose** : To evaluate the advantages of transarticular reconstruction and fixation of metaphysis by MIPO technique for AO type C2-C3 fractures of the distal femur.

**Material and Methods** : In a retrospective study conducted from January 1996 to December 1997, AO type C2-C3 fractures of the distal femur were treated using three techniques; 1) A group-MIPO technique and medial parapatellar arthrotomy for the direct reduction of the condylar block(10 cases), 2) B group-conventional AO technique(8 cases) 3) C group-closed supracondylar nailing(4 cases). Minimal follow-up time was 12 months.

**Results** : Time to bone healing was 15 weeks in A group, 20 weeks in B group, and 16 weeks in C group. complication rate was 0% in A group, 50% in B group, and 50% in C group. normal alignment between 0 & valgus 9 degrees was 100% in A group, 75% in B group, and 50% in C group. Neer score was 90% excellent or satisfactory in A group, 75% in B group, and 50% in C group respectively. The results of A group was better than those of B and C group.

**Conclusion** : Transarticular joint reconstruction and MIPO technique for AO type C2-C3 fractures of the distal femur is an excellent technique to obtain more rapid bony union with less complications.

**Key Words** : Distal femur, AO C2-C3 fractures, transarticular reconstruction, MIPO.

#### Address reprint requests to

Beom Koo Lee, M.D.

Department of Orthopaedic Surgery, Gil Medical Center, Gacheon Medical Collage  
1198, Kuwol-dong, Namdong-gu, Incheon, Korea

TEL: (032) 460-3384

FAX: (032) 468-5437