



13, 3, 2000 7

The Journal of the Korean Society of Fractures
Vol.13, No.3, July, 2000

· · · · ·

< >

:

, , ,

: 1997 4 1999 7

14

. 14

가 11

,

36

77

53

,

,

,

:

1 ,

9 ,

2

가 2

.

11 ,

가 3

,

가 9

9 ,

3 ,

1 ,

1

11 ,

3

5

17

,

79% 3

11

가

5 ,

3 ,

3

가

:

가

,

.

:

,

,

-

,

:

640

(301-721)

Tel : 82-42-220-7351, 7342, 7343

Fax : 042-252-7098

E-mail : jyyang@cnuh.co.kr

*

1999





가 11, 가 3 14 53 .

가 11 가 2, 1 .

7,12), 4,19).

30

2,16).

1, 9, 2,

가 2 8 가 3, 8 16 가 10 11

1997 4 1999 7

11

(Table 1).

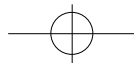
가 9 4

Leung¹¹⁾ modified HSS knee rating system

1997 4 1999 7 (Table 2).

Table 1. Clinical Data & Method

Group	Ischemic Time			Arterial Repair Technique			Fixation Method		
	< 8 hours	8-16 hours	> 16 hours	Vein Graft	End-to-End Anastomosis	thrombo-ectomy	prosthetic material	Internal Fixation	External Fixation
distal femur fracture	1					1		1	
proximal tibia fracture	2	6	1	6	2		1	2	7
Dislocation		2		1	1				2
floating knee	1	1		2					2
TOTAL	3	10	1	9	3	1	1	3	11

**Table 2.** Modified Knee-Rating System*

Variables	Score
Pain	30
Function	22
ROM	15
Muscle Strength	15
Flexion Deformity	10
Instability	5

* Based on the knee-rating scale of The Hospital for Special Surgery Excellent = 85 points or more, Good = 70 to 84 points, Fair = 60 to 69 points, and Poor = less than 60 points.

가

가

. Debakey⁵⁾

2

2471

72.5 %

가

, Hughes⁷⁾

Jahnke

Howard⁸⁾

11.1 %

10.3 %

Lim¹²⁾

14

11 ,

가 3

가

¹⁶⁾. (1)

, (2)

, (3)

5 , 6 , 3

가가

가 9

9

,

3 ,

, Miller

Welch¹⁴⁾

1 ,

1

6-8

90 %, 24

20 %

가가

3cm

Jahnke Seeley⁹⁾

-

3

, 11

9

, Gorman⁶⁾

11

Alberty¹⁾snyder²¹⁾

5

17

,

12)

79% 3

3

9

, 14 ,

가

17

13.3

1

가

, 1

,

1

,

5

17

11

,

3

9

, 14

11

,

17

13.3

가

5 ,

3 ,

3

가

(Table 3).

**Table 3.** Result

	Skeletal Injury	Associated Injury	Ischemic Time Technique	Vascular Repair	Location of Rupture	Prognosis
CASE 1	Distal Femur		10	Thromboectomy	Proximal	Good
CASE 2	Proximal Tibia	Vein	8	Vein Graft	Middle	Good
CASE 3	Proximal Tibia	Soft Tissue	12	Vein Graft	Distal	Amputation
CASE 4	Floating Knee	Vein	12	Vein Graft	Proximal	Fair
CASE 5	Proximal Tibia		7	Vein Graft	Middle	Good
CASE 6	Dislocation	Vein Soft Tissue	14	Vein Graft	Middle	Poor
CASE 7	Floating Knee	Vein	5	Vein Graft	Proximal	Good
CASE 8	Proximal Tibia	Vein	9	Vein Graft	Middle	Good
CASE 9	Dislocation	Vein Soft Tissue	9	End-to-End Anastomosis	Proximal	Amputation
CASE 10	Proximal Tibia	Vein	10	Vein Graft	Distal	Fair
CASE 11	Proximal Tibia		12	End-to-End Anastomosis	Proximal	Fair
CASE 12	Proximal Tibia	Vein	17	Vein Graft	Distal	Amputation
CASE 13	Proximal Tibia	Soft Tissue	16	End-to-End Anastomosis	Middle	Poor
CASE 14	Proximal Tibia	Vein	14	Vein Graft	Middle	Poor

가가

가

, Chapman³⁾ Rich¹⁸⁾

, 가

25 %

22)

1

가

, 2

. Green Allen¹⁵⁾

가

. Smith²⁰⁾

17)

가

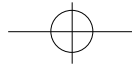


가 , 1.5cm

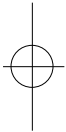
가 .

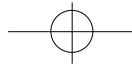
REFERENCES

- 1) **Alberty, R.E., et al.** : Popliteal artery injury with fracture dislocation of the knee. *Am. J. Surg.*, Jul : 142(1):36-40, 1981
- 2) **Bassett FH, Silver D** : Arterial injury associated with fractures. *Arch. Surg.*, 92:13-19, 1966
- 3) **Chapman, J.A.** : Popliteal artery damage in closed injuries of the knee. *J. Bone and Joint Surg.*, 67B : No3, May, 1985
- 4) **Charles J. McCabe, Charles M. Ferguson, Leslie W. Ottinger** : Improved limb salvage in popliteal artery injuries. *J. Trauma.*, 23:982-985 1983
- 5) **Debakay, M.E. and Simeone, F.A.** : Battle injuries of the arteries in the World War II. An analysis of 2471 cases. *Ann. Surg.*, 123:534-579, 1946
- 6) **Gorman, J.F.** : Combat wounds of the popliteal artery. *Ann. Surg.*, 168:974, 1968
- 7) **Hughes, C.W.** : Acute vascular trauma in Korean War Casualties. An analysis of 180 cases. *Surg., Gynec. and obstet.*, 99:91-100, 1954
- 8) **Jahnke, E.J., Jr., Howard, J.M.** : Primary repair of major arterial injuries. Report of fifty-eight battle casualties. *Arch. Surg.*, 66:646-649, 1953
- 9) **Jahnke, E.J., and Seeley, S.F.** : Acute vascular injuries cases. *Ann. Surg.*, 138:158, 1953
- 10) **Kim S.S., Sim D.M., Kim H.S., Lee B.C., Choi I.Y.** : , 28:7, 2380-2387, 1993
- 11) **Leung K.S. et al.** : Interlocking Intramedullary Nailing for supracondylar and intercondylar fractures of the distal part of the femur. *J. of Bone and Joint Surg. Am. Mar*;73(3):332-40, 1991
- 12) **Lim, L.T., Michuda, M.S., Flanigan, D.P. and Pankovich, A.** : Popliteal artery trauma : 31 consecutive cases without amputation. *Arch. Surg.*,



- 115:1307, 1980
- 13) **Makin, G.S. and howard, J.M., and Green, R.L.** : Arterial injuries complicating fractures or dislocations. The necessity for a more aggressive approach. *Surg.*, 59:203-209, 1966
- 14) **Miller, H.H., and Welch, C.S.** : Quantitative studies on the time factor in arterial injuries. *Ann. Surg.*, 130:428-438, 1949
- 15) **Neil E. Green, M.D., and Ben L. Allen, M.D.** : Vascular injuries associated with dislocation of the knee. *J. Bone and Joint Surg.*, Mar:59(2):236-239, 1977
- 16) **O'Donnel TF Jr, Brewster DC, Darling RC, Veen H, Weltman AA.** : Arterial injuries associated with fractures and/or dislocations of the knee. *J. Trauma.*, 17:775-84, 1977
- 17) **Perry, M.O., Thal, E.R. and Shires, G.T.** : Management of arterial injuries. *Ann. Surg.*, 173:403, 1971
- 18) **Rich, N.M., Mert, C.W. Jr., hutton, J.E., Baugh, J.M. and Hugh, C.W.** : Internal versus External fixation of fractures with concomitant vascular injuries in Vietnam. *J. Trauma*, 11:463-473, 1971
- 19) **Rich NM, Spencer FC** : Vascular trauma. Philadelphia, *WB Saunders Co*, 1978
- 20) **Smith, R. et al.** : Fracture of the long bones with arterial injuries due to trauma. *Arch. Surg.*, 99:315-325, 1969
- 21) **Snyder, W.H., III, Wattkin, W.L., Whiddon, L.L. and Bone, G.E.** : Civilian popliteal artery injury association with skeletal trauma. An eleven year experience with 83 injuries. *Surg.*, 85:101, 1979
- 22) **Yoo M.C., Kim B.G., Cho I.H., Chang S.G., Ann J.H.** : . , 19:3, 501-507, 1984





Abstract

Popliteal Artery Injury Associated with Fracture and/or Dislocation of the Knee

Jun-Young Yang, M.D., Kwang-Jin Rhee, M.D., June-Kyu Lee, M.D.,
Deuk-Soo Hwang, M.D., Ki-Yong Byun, M.D., Taek-Soo Jeon, M.D.

*Department of Orthopaedic Surgery, School of Medicine,
Chungnam National University, Daejeon, Korea*

Purpose : To compare the outcome in patients who have popliteal artery injury associated with fracture and/or dislocation around the knee according to treatment option.

Materials & Methods : We have reviewed fourteen cases of popliteal artery injury patients associated with fracture and/or dislocation injury around the knee who had visited at Chungnam National University Hospital from April 1997 to July 1999.

Results : Combined skeletal injuries included fracture of distal femur, fracture of proximal tibia, and dislocation of the knee. Internal or external fixation was applied for skeletal injuries. We repaired the injured popliteal artery using end-to-end anastomosis (3 cases), interposed saphenous vein graft (9 cases), prosthetic vein graft (1 case), or thrombectomy alone (1 case). The amputation rate was 21 % (3 out of 14 patients). In limb salvage cases, we evaluated the function of knee joint, and the results were as follows : good 5 cases, fair 3 cases, and poor 3 cases.

Conclusion : Early diagnosis and prompt management for injuries of the popliteal artery is the most important factor to save the limb. Also, complete resection of all injured portion of vessel and reconstruction of patency through interposed saphenous vein graft are most useful method.

Key Words : Knee joint, Popliteal artery injury, Fracture, Dislocation, Saphenous vein graft

Address reprint requests to _____

Jun-Young Yang, M.D.

301-721 #640 Daesa-Dong, Jung-Ku, Daejeon, Korea

Department of Orthopaedic Surgery, School of Medicine,

Chungnam National University

Tel : 82-42-220-7351, 7342, 7343

Fax : 042-252-7098

E-mail : jyyang@cnuh.co.kr