



12, 2, 1999 4

The Journal of the Korean Society of Fractures
Vol.12, No.2, April, 1999

= Abstract =

Relationship between Simple X-ray and CT Findings on the Degree of Canal Encroachment in Burst Fracture of Thoracolumbar Junction

Young-Do Koh, MD, and Jong-Oh Kim, MD

Department of Orthopedic Surgery, College of Medicine, Ewha Woman ' University

In burst fracture of thoracolumbar junction, compressive injury of middle column is characteristic and neurologic symptom develops by retropulsion of bony fragment into spinal canal.

Authors had treated 44 cases with burst fracture of thoracolumbar junction at Ewha Woman ' University Mokdong Hospital from September, 1993 to December, 1997 and analyzed the relationships between simple radiologic findings and canal encroachment and between neurology and canal encroachment.

The results were as follows; Canal encroachment by bony fragment was larger in lower vertebra than in upper one. Canal encroachment was larger in Denis type A than in type B. Both anterior vertebral height(AVH) and presence of neurology were not related with the amount of canal encroachment. The lesser loss of posterior vertebral height(PVH) and kyphotic angle were, the more canal encroachment was. In summary, factors that influenced the amount of canal

:

911-1 (158-050)

Tel : 650 - 5564 Fax : 644 - 0128



encroachment were fracture level and type. There was no significant relationship between neurology and the amount of canal encroachment. AVH, PVH and kyphotic angle were not related with the amount of canal encroachment.

Key Words : Thoracolumbar junction, Burst fracture, Canal encroachment

가 2.6), 1. 14 66 41.0, 30 40 가 12 가, 가 31 (70.5%), 가 13 (25.9%), 8.9), 가 3.10), 2. 11 2, 11 가 7 (15.9%), 12 가 11 (25.0%), 1 가 15 (34.1%), 2 가 11 (25.0%), 3. Denis A Denis B Denis A 18 (40.9%), Denis B 26 (59.1%), 4. (a+b/2) (c) (Fig. 1). 가 30%, 가 0.7, 가 0.7, 20 (45.5%), 1993 9 1997 12 44



390 •

/ 12 2

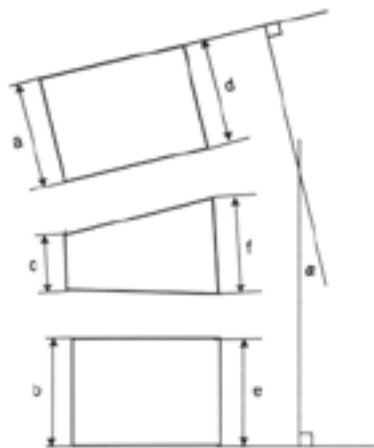


Fig 1. Diagram of measurement methods for anterior and posterior vertebral height (AVH & PVH) and kyphotic angle().

$$AVH = \frac{c}{(a + b)/2} \quad PVH = \frac{f}{(d + e)/2}$$

가 0.7 24(54.5%) .

5.

(d+e/2)

(f)

(Fig. 1).

가 5%

가 0.95

1.

가 5%

가 0.95

가 0.95

가 0.95

25 (56.8%),

19(43.2%) .

33.0% , 20% 20%

5% 90% 가 18 (40.9%) 가

2.

6.

11

15.0%, 12

23.0%, 1

() Cobb

(Fig.

28.6%, 2

58.3% ,

1).

15

15

22

2

가

(Table 1).

7.

3.

%

Denis A

가 41.9%,

가

20.0%

Denis B

, Denis A

Denis B

가

(Table 2).

**Table 1.** Fracture levels vs canal encroachment

Level	No.	canal encroachment
T11	7	15.0%
T12	11	23.0%
L1	15	28.6%
L2	11	58.3%

4.

0.7

30%

가 0.7

35.5%,

가

0.7

30.8%

(Table 3).

5.

0.95

5%

가 0.95

41.9%,

가 0.95

20% ,

가

(Table 4).

Table 2. Fracture types vs canal encroachment

Type	No.	canal encroachment
Denis A	18	41.9%
Denis B	26	20.0%

Table 3. Anterior vertebral height(AVH) vs canal encroachment

AVH	No.	canal encroachment
0.7	20	35.5%
< 0.7	24	30.8%

6.

15.8

15

40.5%,

15

25.5% ,

(Table 5).

Table 4. Posterior vertebral height(PVH) vs canal encroachment

PVH	No.	canal encroachment
0.95	25	41.9%
< 0.95	19	20.0%

7.

44 14 (31.8%)

,

34.3%,

32.3%

가

(Table 6).

Table 5. Kyphotic angle vs canal encroachment

Kyphosis	No.	canal encroachment
15 °	22	40.5%
> 15 °	22	25.5%

1.

44

2

Denis B

1.0,

7 °

(Fig. 2-A),

0.8,

Table 6. neurology vs canal encroachment

neurology	No.	canal encroachment
present	14	34.3%
absent	30	32.3%

45% (Fig. 2-B).

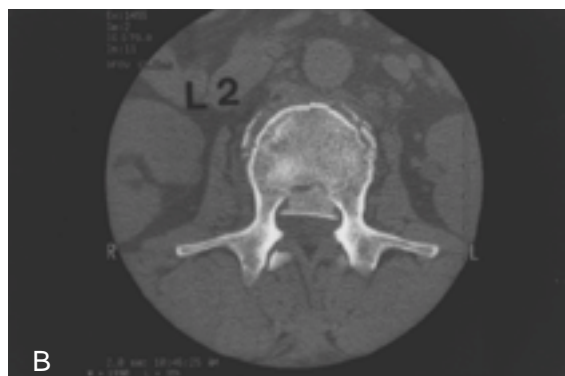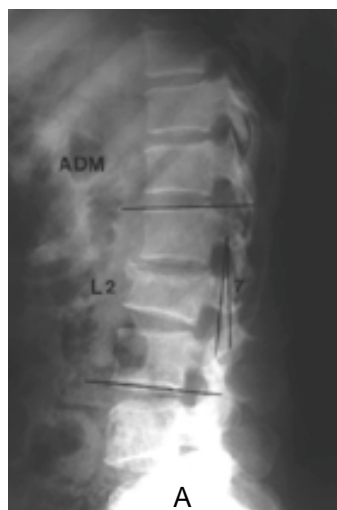


Fig 2. Simple x-ray of 44 year-old woman shows Denis type B burst fracture of L2 with kyphosis 7 °(2-A). CT shows canal encroachment of 45% (2-B).

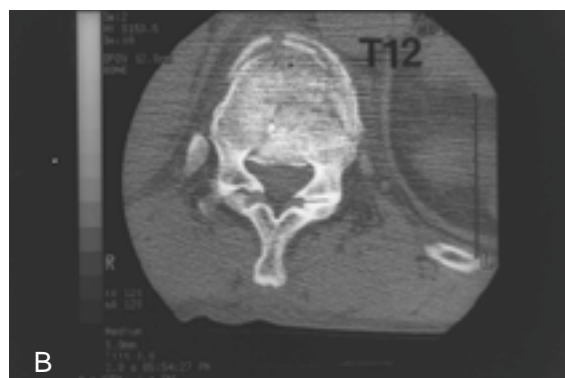
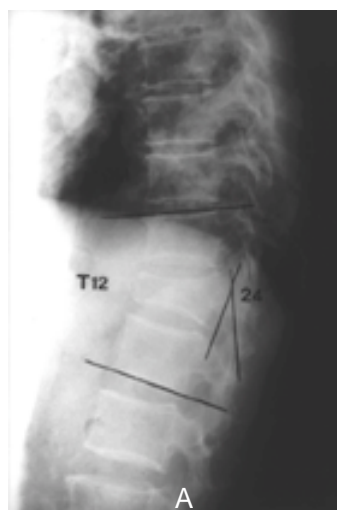


Fig 3. Simple x-ray of 62 year-old man shows Denis type A burst fracture of T12 with kyphosis 24 °(3-A). CT shows canal encroachment of 20%(3-B).

2.

62

12

Denis A
0.9,

24 ° (Fig. 3-A),

0.6,

Holdsworth¹³⁾

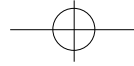
20% (Fig. 3-B).

,

9)

50%

가
15%
14),



. Denis (three column theory)
(two column theory)

3,10,15). Garfin 10)

가

8,9)

McAfee 15)

가

가

3)

가 ,

가

가

Denis A Denis B
가 .

1,4,5,7,12)

Denis A

Denis

가

B

,

,

,

가

,

가

,

.

.

가 ,

(T11 T12) (L1 L2)

가 .

가

.

1993 9

1997 12

가

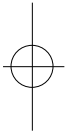
. Guerra

44

11) B

.

.





REFERENCES

- 1) **Denis F** : Spinal instability as defined by the three column spine concept in acute spinal trauma. *Clin Orthop*, 189:65-70, 1984.
- 2) **Denis F** : Three column spine and its significance in the classification of acute thoracolumbar spinal injuries. *Spine*, 8:817-831, 1983.
- 3) **Garfin SR, Mowery CA, Guerra J and Marshall LF** : Confirmation of the posterolateral technique to decompress and fuse thoracolumbar spine burst fractures. *Spine*, 10:218-223, 1985.
- 4) **Guerra J, Garfin SR and Resnick D** : Vertebral burst fractures: CT analysis of the retropulsed fragment. *Radiology*, 153:769-772, 1984.
- 5) **Hashimoto T, Kaneda K and Abumi K** : Relationship between traumatic spinal canal stenosis and neurologic deficits in thoracolumbar burst fractures. *Spine*, 13:1268-1272, 1988.
- 6) **Holdsworth F** : Fractures, dislocations, and fracture-dislocations of the spine. *J Bone Joint Surg*, 52A:1534-1551, 1970.
- 7) **Kaneda K, Abumi K and Fujiya M** : Burst fractures with neurologic deficits of the thoracolumbar spine. Results of anterior decompression and stabilization with anterior instrumentation. *Spine*, 9:788-795, 1984.
- 8) **McAfee PG, Bohlman HH and Yuan HA** : Anterior decompression of traumatic thoracolumbar fractures with incomplete neurological deficit using a retroperitoneal approach. *J Bone Joint Surg*, 67-A:89-104, 1985.
- 9) **Bedbrook GM** : Spinal injuries with tetraplegia and paraplegia. *J Bone Joint Surg*, 61B:267-284, 1979.
- 10) **Bedbrook GM** : Treatment of thoracolumbar dislocation and fractures with paraplegia. *Clin Orthop*, 112:27-43, 1975.
- 11) **Bridwell KH and DeWald RL** : Surgical treatment of thoracic and lumbar burst fractures. *The textbook of spinal surgery*. 2nd ed, Philadelphia, Lippincott-Raven, 1839-1876, 1997.
- 12) **Davies WE, Morris JM and Hill V** : An analysis of conservative management of thoracolumbar fracture and fracture dislocation with neural damage. *J Bone Joint Surg*, 62A:1324-1328, 1980.