

12, 2, 1999 4

The Journal of the Korean Society of Fractures
Vol.12, No.2, April, 1999

- 1 -

.

= Abstract =

Traumatic dislocation of hip in children - A Case Report of 30 Months Followup -

Soo-Jae Yim, M.D., Yeon-Cheol Jeong, M.D., Seung-Ryool Yoon, M.D.,
Joong-Geun Choi, M.D., You-Sung Suh, M.D., Yon-Il Kim, M.D.

Department of Orthopedic Surgery, Soochunhyang University Kumi Hospital

Traumatic hip dislocation in childhood is rare. Factors predisposing to abnormal results are delayed reduction and severe trauma. We experienced 8 year-old girl with traumatic posterior hip dislocation and treated with immediate closed reduction. At 30 months follow-up, our patient had good functional and good roentgenographic result with no posttraumatic arthritis or posttraumatic avascular necrosis. So we report this case with review of literature.

Key Words : Hip, Traumatic dislocation, Childhood

:

657 (140-210)

Tel : 02) 709 - 9257

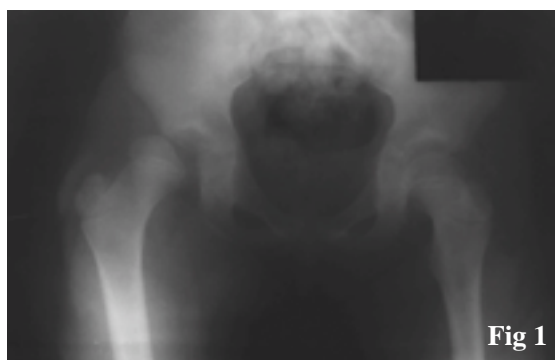
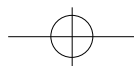


Fig 1

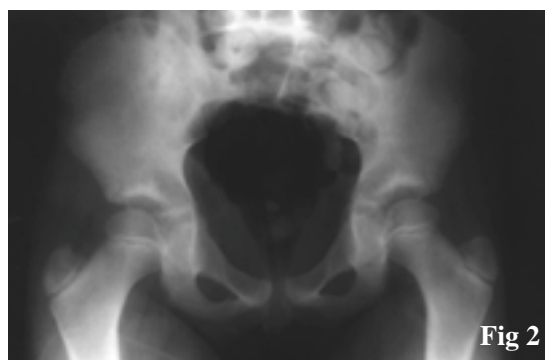

Fig 2

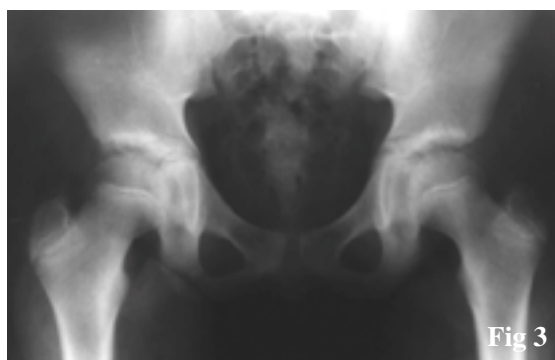


Fig 3

Fig 1. Initial both hip AP view: Right femoral head was dislocated posterolaterally

Fig 2. Right femoral head was well reduced by immediate closed reduction

Fig 3. 30 months after the trauma, Manifest no abnormal radiologic findings



2 , 2 . 4 . 12 . 30 . 1 3 . 3-6 12 2-3 가 가 2 4-6 가 13), 가 . Gartland Benner , 5). Rang 5 가 12), 가 7- 10 1,10,17), 5), 가 5), Gartland Brenner 가 5) Schoenecker 14), 가 8-10 % 5-7,9,17), Coxa magnus 3,11), 8-12 6), 1), Gartland 가 5), Libri 가 8), 2 4 1).



REFERENCES

- 1) **Barquet, A.:** Traumatic Hip Dislocation in Childhood. A Report of 26 Case and a Review of the Literature. *Acta orthop scand.*, 50:549-553, 1979.
- 2) **Brav, E.A.:** Traumatic Dislocation of the Hip. Army Experience and Results Over a 12-Year Period. *J Bone Joint Surg.*, 44A:1115-1134, 1962.
- 3) **Freeman, G.E., Jr.:** Traumatic Dislocation of the Hip in Children. A Report of 7 Cases and a Review of the Literature. *J Bone Joint Surg.*, 43A:401-406, 1961.
- 4) **Funk, F.J.:** Traumatic Dislocation of the Hip in Children. Factors Affecting Prognosis and Treatment. *J Bone Joint Surg.*, 44A:1135-1145, 1962.
- 5) **Gartland, J.J., and Benner J.H.:** Traumatic Dislocation in the Lower Extremity in Children. *Orthop clin North Am.*, 7:687-700, 1976
- 6) **Glass, A., and Powell, H.D.W.:** Traumatic Dislocation of the Hip in Children. *J Bone Joint Surg.*, 43B:29-37, 1961.
- 7) **Haliburton, R.A., Brockenshire, F.A., and Barber, J.R.:** Avascular Necrosis of the Femoral Capital Epiphysis After Traumatic Dislocation of the Hip in Children. *J Bone Joint Surg.*, 43B:43-46, 1961.
- 8) **Libri, R., Calderon, J.E., Capelli, A., and Soncini, G.:** Traumatic Dislocation of the Hip in Children and Adolescents. *Ital. J Orthop Traumatol.*, 12:61-67, 1986.
- 9) **Mason, M.:** Traumatic Dislocation of the Hip in Childhood. *J Bone Joint Surg.*, 36B:630-632, 1954.
- 10) **Pearson, D.E., and Mann, R.J.:** Traumatic Hip Dislocation in Children. *Clin Orthop.*, 92:189-194, 1973.
- 11) **Piggot, J.:** Traumatic Dislocation of the Hip in Childhood. *J Bone Joint Surg.*, 43B:38-42, 1961.
- 12) **Rang, M.:** Children's Fractures, 2nd ed. Philadelphia, *J.B. Lippincott*, 1983.
- 13) **Rang, M.:** The Growth Plate and Its Disorder. Baltimore, *Williams and Wilkins*, 1969.
- 14) **Schoenecker, P., Manske, P., and Sertl, G.:** Traumatic Hip Dislocation with Ipsilateral Femoral Shaft Fractures. *Clin Orthop.*, 130:233-238, 1978.
- 15) **Stewart, M.J., and Milford, L.W.:** Fracture-Dislocation of the Hip. An End-Result Study. *J Bone Joint Surg.*, 35A:315-342, 1954.
- 16) **Trojan, E.:** Traumatic Dislocation and Fracture-Dislocations of the Hip. *Rev Chir Orthop.*, 45:469-486, 1959.
- 17) **Wilson, D.W.:** Traumatic Dislocation of the Hip in Children: A Report of Four Cases. *J Trauma*, 6:739-743, 1966.