



12, 2, 1999 4

The Journal of the Korean Society of Fractures
Vol.12, No.2, April, 1999

= Abstract =

Percutaneous Fixation in Medial Malleolar Fracture

Phil-Hyun Chung, M.D., Chung-Soo Hwang, M.D., Suk-Kang, M.D.,
Ki-Se Nam, M.D. and Ho-Kyun Bae, M.D.

Department of Orthopaedic Surgery, College of Medicine, Dongguk University, Kyungju, Korea

Fracture of the ankle is one of the most common fractures. Usually medial malleolar fractures, when non-displaced or minimally displaced, have been treated by closed reduction and cast immobilization for long period, so stiffness and osteoporosis of ankle were frequently inevitable.

We investigated the result of percutaneous pinning or screw fixation and early mobilization in the treatment of medial malleolar fracture of the ankle.

With clinical and radiological data, authors analysed 17 patients(17 ankles) who were treated with closed reduction and percutaneous pinning or screw fixation between August 1991 and May 1997. and following results were obtained.

One case of pin site infection was noted and no nonunion or loss of fixation was identified and average duration of bone union was 12 weeks. According to Burwell 's protocol, the good result are 16 cases, the fair is 1 case and the poor result is not observed.

From the viewpoint of rehabilitation, authors consider percutaneous pinning is an excellent plan of treatment of medial malleolar fractures, when non-displaced or minimally displaced.

Key Words : Medial malleolar fracture, Percutaneous fixation

:

1090-1 (780-350)

Tel : (0561) 770 - 8224 Fax : (0561) 770 - 8221

*

1998

3mm 1 ,

가 2 1 2 .

1.

21 72 43

가15 가2 .

11,17,18,21,24)

2.

12,14,19)

12 , 4 ,

6,15)

1 .

2 5 .

8)

1 가 2 ,

가 1 .

3.

(minimal surgery)

Lauge-Hansen

C-arm

Lauge-Hansen - -

1 13 , 2 2

1991 8 1997 5 6

25 1 가가 17 C-arm

Table 1. Operative method

Instrument	Number
Cancellous screw 1 or 2	11
Malleolar screw 1 or 2	1
Malleolar screw + K-wire	2
K-wire 2	1
Cannulated screw + K-wire	2

Table 2. Preoperative and Postoperative fracture gap on AP plane

	Mean	Range
Preoperative	1.7 mm	0 - 1 mm (5 cases) 1 - 2 mm (7 cases) 2 - 3 mm (3 cases)
Postoperative	0.3 mm	0 - 1 mm (16 cases) 1 - 2 mm (1 cases)

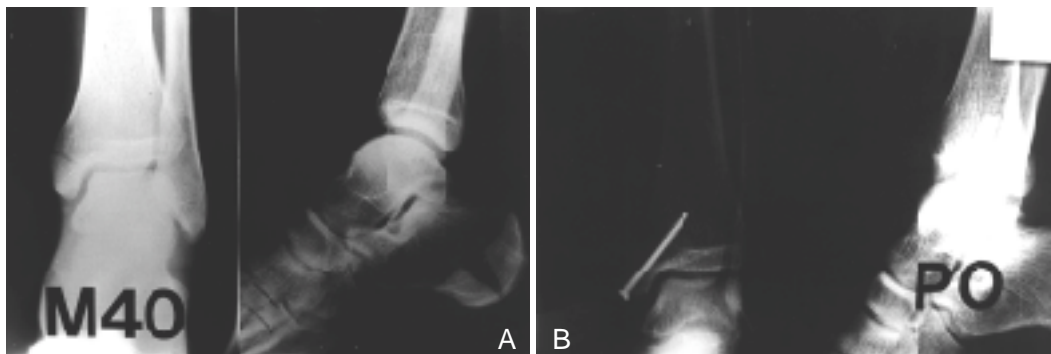


Fig 1-A. 40-year-old man. Initial radiograph showed fracture gap of medial malleolus within 3mm.
B. Immediate post-operative radiograph showed anatomical reduction state.

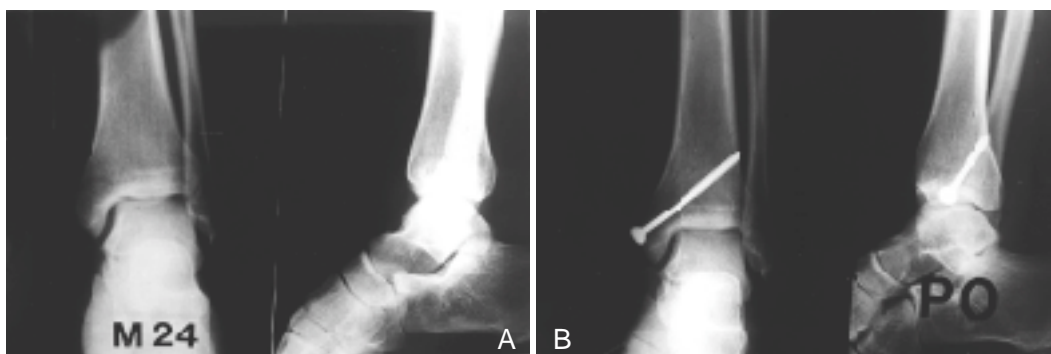


Fig 2-A. 24-year-old man. Initial radiograph showed transverse fracture of medial malleolus with displacement of 2mm.
B. Immediate post-operative radiograph showed anatomical reduction state.

K- (cannulated screw) 12
 0.5cm (Table 1).
 K- 가 5. 가
 가 Burwel¹⁶⁾ 가
 K- . C-arm 3/4
 가 good,
 . 1 1/2
 , fair,
 1 6 1/2



Poor . 가 Hughes ¹⁰⁾

Weber type B C

가

J ²³⁾ - 2 Yde

1. 가 , Bauer M ¹⁾

17 10

, 6 1mm , 1 2mm

1.74mm 0.3mm

. (Fig 1,2) Lauge-Hansen

가 . 3

2 , 2,12,14,19)

1mm ,

가

가 (Table 2). , Harper Michelson ^{9,14)}

2. , ,

1 . Sneppen²⁰⁾

3. .

4 30 .

6,15) Finsen V. ⁸⁾

1 ,

6 가 . 1

12 .

가 2

4. , Namba ¹⁵⁾

16 good, 1 fair ,

poor .

가

가

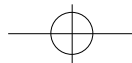
가

8 12

가 가

. Burwell

Chamley⁶⁾



REFERENCES

Tunturi 21)

16,24),

C-arm

17

10

, 6

1mm

6

1

17

1

가

2

17

(16 good, 1 fair)

3mm

1991

8

1997

5

6

71

3mm

25 가 1

가 가

17

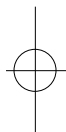
(good 16, fair 1)

12

가

3mm

- 1) **Bauer M, Jonsson K, Nilsson B** : Thirty-year follow-up of ankle fractures, *Acta Orthop Scand* 56:103,1985.
- 2) **Beauchamp CG, Clay NR, Thexton PW** : Displaced ankle fractures in patients over 50 years of age, *J Bone Joint Surg* 65-B:329, 1983
- 3) **Boden SD, Labropoulos PA, McCowin P, Lestini WF, Hurwitz SR** : Mechanical considerations for the syndesmosis screw. A cadaver study, *J.Bone and Joint Surg*, 71-A: 1548-1555, 1989
- 4) **Bostman OM** : Displaced malleolar fractures associated with spiral fractures of the tibial shaft, *Clin Ortho* 228:202, 1988.
- 5) **Breederveld RS, van Straaten J, Patka P, van Mourik JC**: Immediate of delayed operative treatment of fractures of the ankle, *Injury* 19:436, 1988.
- 6) **Burwell HN, Charnley AD** : The treatment of displaced fracture at the ankle by rigid internal fixation and early joint movement, *J Bone Joint Surg* 47-B:634, 1965
- 7) **Dahners LE** : The pathogenesis and treatment of bimalleolar ankle fractures, *AAOS Instr Course Lect* 39:85, 1990.
- 8) **Finsen V, Saetermo R, Kibsgaard L, et al** : Early postoperative weight-bearing and muscle activity in patients who have a fracture of the ankle, *J Bone Joint Surg* 71-A:23, 1989.
- 9) **Harper, M.C.** : An anatomic study of the short oblique fracture of the distal fibula and ankle stability. *Foot and Ankle*, 4:23-29, 1983
- 10) **Hughes JL, Weber H, Willenegger H, Kuner EH** : Evaluation of ankle fractures: non-operative and operative treatment, *Clin Orthop* 138:111, 1979.
- 11) **Johnson EE, Davlin LB** : Open ankle fractures, the indication for immediate open reduction and internal fixation, *Clin Orthop* 292:118, 1993.
- 12) **Kristensen KD, Hansen T** : Closed treatment of ankle fractures: stage II supination-eversion fractures followed for 20 years, *Acta Orthop Trauma* 56:107, 1985.
- 13) **Lauge_Hansen N** : Fractures of the ankle. II. Combined experimental-surgical and experimental-roentgenologic investigations, *Arch Surg* 60: 957,1950.





- 14) **Michelson JD** : Current concepts review fractures about the ankle, *J Bone Joint Surg* 77-A, 1995.
- 15) **Namba RS, Kabo JM, Dorey FJ, Meals RA**: Continuous passive motion versus immobilization: the effect on posttraumatic joint stiffness, *Clin Orthop* 267:218, 1991.
- 16) **Orava S, Karpakkaa J, Taimela S, et al** : Stress fracture of medial malleolus, *J Bone joint Surg* 77;A:362, 1995.
- 17) **Phillips WA, Schwartz HS, Keller CS, et al** : A prospective, randomized study of the management of severe ankle fractures. *J Bone Joint Surg* 67A: 67-78, 1985.
- 18) **Phillips WA, Spiegel PG** : Evaluation of ankle fractures: non-operative vs operative, *Clin Orthop* 138:17, 1979 (editorial).
- 19) **Sarkisian IS, Cody SW**: Closed treatment of ankle fractures: a new criterion for evaluation: a review of 250 cases, *J Trauma* 16:323, 1976.
- 20) **Sneppen, O.** : Long-term course in 119 cases of pseudoarthrosis of medial malleolus. *Acta Orthop. Scandinavica*, 40:807-816, 1969.
- 21) **Tunturi T, Kempainen K, Patiala H, et al** : Importance of anatomical reduction for subjective recovery after ankle fracture. *Acta Orthop Scand* 54:641-647, 1983.
- 22) **Wilson FC** : The pathogenesis and treatment of ankle fractures: classification, *AAOS Instr Course Lect* 39:79, 1990.
- 23) **Yde J, Kristensen KD** : Ankle fractures: supination-eversion fractures of stage II--primary and late results of operative and nonoperative treatment, *Acta Orthop Scand* 51:695, 1980.
- 24) **Yde J, Kristensen KD** : Ankle fractures: supination-eversion fractures of stage IV--primary and late results of operative and nonoperative treatment, *Acta Orthop Scand* 51:981, 1980.

