

12, 1, 1999 1

The Journal of the Korean Society of Fractures
Vol.12, No.1, January, 1999

= Abstract =

Results and Problems of open Intramedullary Nailing of Femoral Shaft Fracture

Chung-Nam Kang, M.D., Jong-Oh Kim, M.D., Dong-Wook Kim, M.D.
Young-Do Koh, M.D., Jae-Doo You, M.D., Kyoung-Soo Kim, M.D.

*Department of Orthopaedic Surgery, College of Medicine
Ewha Womans University, Seoul, Korea*

The intramedullary nailing is one of the most available methods in treatment of femoral shaft fracture. The closed intramedullary nailing is known to be the best method of treatment of femur shaft fracture, but it is not always available in cases of deficit of equipment, severe associated injury, and some fracture pattern. The open intramedullary nailing has advantage of easily obtaining anatomical reduction but it increases the risk of infection, the incidence of delayed union and additional operations inevitably.

We reviewed 33 cases of open intramedullary nailing in femur shaft fracture from September 1994 to September 1997.

The results were as follows :

1. The average union time was 27.3 weeks.
2. Location of fractures was middle one-thirds in most cases, and Winquist-Hansen classification type II was the most common.

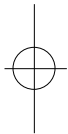
:

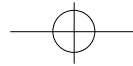
911-1 (158-050)

Tel : 650 - 5276 Fax : 642 - 0349

*

42





3. The complication included 8 delayed unions, 3 nonunions, 2 infections, shortening of more than two centimeters in 3 patients.
4. In 4 cases, we did open intramedullary nailing with bone graft initially, but all of them has complication as delayed union and nonunion.

We can use open intramedullary nailing method in some femur shaft fractures, but there are many problems and complications. So we must consider it carefully before using this method.

Key Words : Femur, Shaft fracture, Open intramedullay nailing

1

가가 33

가

13).

1965 Küntscher¹³⁾가

1994 9 1997 9

가 . 1972 Klem

Schnellman¹²⁾, 1974 Kempf Grosse¹⁰⁾, 1984 Winquist Hansen¹⁷⁾

가가 33 1

가

11).

가

17 78 ,
 38.6 가 23 가 10 가
 2 가 5 , 가 4 , 가 20 ,
 가가 가 4

가

fracture table

33

가 1/3 6 , 1/3 22 , 1/3 5

Winquist-Hansen

16-18). Winquist-

Hansen I 7 , II 12 , III IV

가 16).

7

5 ,

1994 9 1997 9

16 ,

3 ,

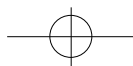
5 ,

4

가

16).





30 • / 12 1

33 19 (56%)
10 2
6 가
3 , 2 ,
2 ,
6 .
1-2
2
2
가 가
1995
Winquist-Hansen I, II 12
가
4
1.
Kempf¹⁰⁾
가 ,
가 ,
가 ,
72 27.3 . 15 Muller¹⁵⁾
8
6
가 16)
가 11 (33.3%)
(Table 1).
2. 가
33
가 4 ,

Table 1. Union Time

Duration(weeks)	Patient Number
15-18	2
19-22	8
23-26	12
27-30	5
31-34	3
>34	3
Total	33
Average (27.32wks)	

Table 2. Additional Operations after Primary Nailing

Additional Operation	Patient Number
Dynamization	4
Dynamization + Autogenous bone graft	5
Nail Exchange + Autogenous bone graft	2
Total	11

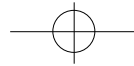
Table 3. Complications

Entities	Patient number
Infection	2
LLD*	3
Delayed Union	8
Nonunion	3
Joint Stiffness	5
Trochanteric bursitis	1
Total	22

* LLD : leg length discrepancy

Table 4. Functional results (Denker H)

Result	Patient number
Excellent	7 (21%)
Satisfactory	10 (30%)
Fair	13 (40%)
Poor	3 (9%)
Total	33



가
4 , 3 가 2
가 , 1 1.
가 37
(Table 2).
Winquist-Hansen type IV
3.
8 , 3 , 가
, 2 , 가
5 , 9
2cm 3 .
4. 가 18
, , 2cm 가
, , (Fig 1).
Denker⁶⁾ 가
, 17 (51.5%) 2.
(Table 4). 43
Hansen II Winquist-

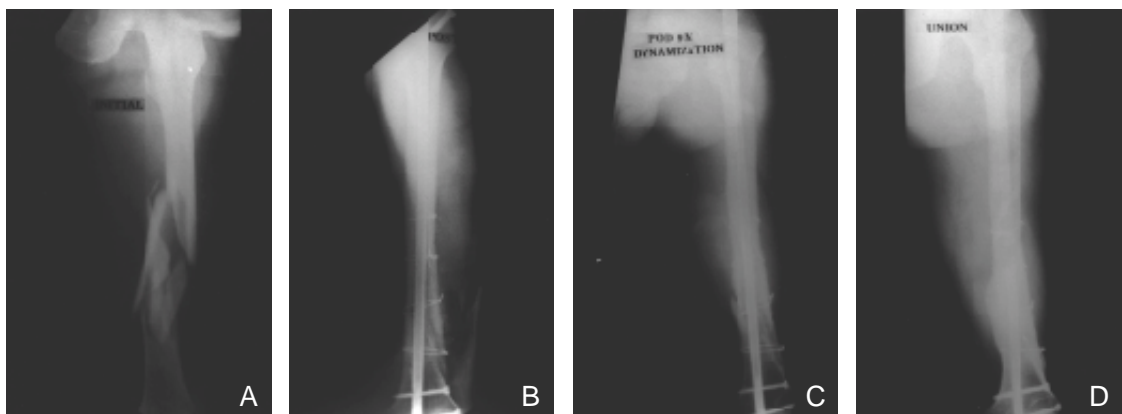


Fig 1. Serial radiographs of 37 year-old male patient treated with open interlocking intramedullary nailing.
A. Preoperative radiograph shows comminuted femoral shaft fracture.
 (Winquist-Hansen type IV)
B. Immediate postoperative radiograph.
C. 9 months after surgery, dynamization was done.
D. Union was obtained at 9 month after dynamization.

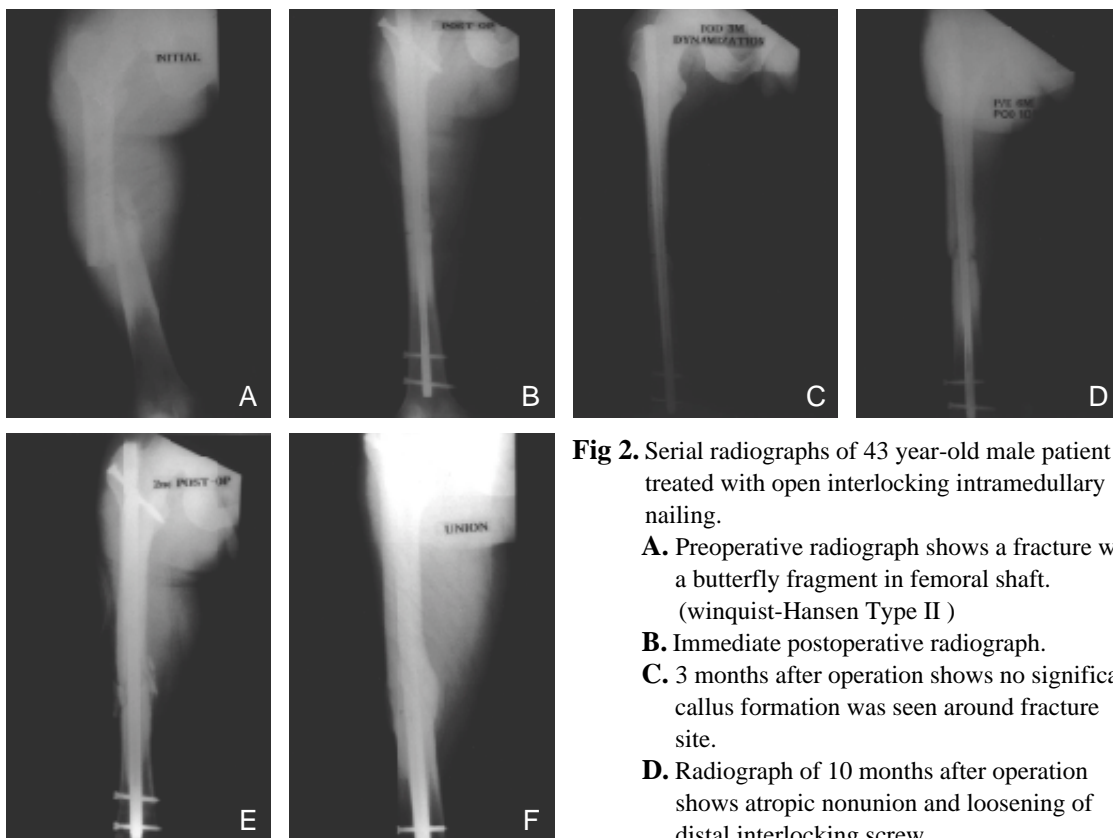
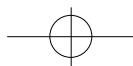


Fig 2. Serial radiographs of 43 year-old male patient treated with open interlocking intramedullary nailing.

- A.** Preoperative radiograph shows a fracture with a butterfly fragment in femoral shaft. (winquist-Hansen Type II)
- B.** Immediate postoperative radiograph.
- C.** 3 months after operation shows no significant callus formation was seen around fracture site.
- D.** Radiograph of 10 months after operation shows atrophic nonunion and loosening of distal interlocking screw.
- E.** An wider nail was inserted with autogenous 10 months after first operation.
- F.** Union was obtained 7 months after second operation.

, 3

, cast brace

18).

Küntscher nail

가

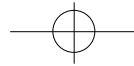
가

6

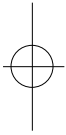
(Fig 2).

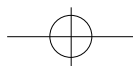
Grosse, Kempf ¹⁰⁾

^{1,2,13)} 1972 Klemm¹²⁾ 1974



. C-Arm 가
 fracture table
 가 1984 Johson ⁹⁾ Grade III, IV
¹⁷⁾ 22%
 가 , 13%
 2 (6.06%) 1
 1
 . 33 Winqvist-
 Hansen Grade III Grade IV 14
 , Winqvist-Hansen Grade I Grade II 가
 2 가 7
 . 12 Winqvist-Hansen Grade I 가
 Grade II 가 , 1984 ³⁾
 . 23 , 1993 ¹⁾
 26.9 1996 ²⁾ 20.5
 가 , 가 , 27.32 .
 Christensen ⁵⁾
 20 가
 Harper⁷⁾ 39 , Muller
 80 Thomas¹⁵⁾ 가
 가 . Harper⁸⁾ fluted rod
 14 가 4
 , , 3 가
 가
^{1,15-18)}
 Winqvist Hansen^{17,18)} Grade III, IV
 3 2
 , IV 12 III 6-8 가 1
 가
 .
 Winqvist-Hansen
 Grade III, IV 14 ,
 6 가
 가 3
 9 가 , 2 1993 ³⁾
 ,





가 III, IV

2 3
가

REFERENCES

- 1) , , , , :
, 28:1684-1689, 1993.
- 2) , , , :
, 31:490-498, 1996.
- 3) , , :
, 19:136, 1984.
- 4) **Bohler J** : K ntscher medullary nailing. *J Bone Joint Surg*, 31-A:295-305, 1949.
- 5) **Christensen NO** : K ntscher intramedullary reaming and nail fixation for nonunion of fracture and tibia. *J Bone Joint Surg*, 55-B:312, 1973.
- 6) **Denker H** : Shaft fractures of the femur. *A cta Chir Scand*, 130:173-181, 1965
- 7) **Harper MC** : Fractures of the femur treated by open and closed intramedullary nailing using the fluted rods. *J Bone Joint Surg*, 67-A:699-708, 1985.
- 8) **Harper MC** : Ununited fractures of the femur stablized with the fluted rod. *Clin Orthop*, 190:273-278, 1983.
- 9) **Jhonson KD, Jhonston BWC and Parker B** : Comminuted femoral shaft fractures : Treatement by roller traction, cerclage wires and an intrmedullary nail, or an interlocking nail. *J Bone Joint Surg*, 66-A:1222, 1984.
- 10) **Kempf I, Grosse A and Beck G** : Closed locked intramedullary nailing. Its application to comminuted fractures of the femur. *J Bone Joint Surg*, 67-A: 709-720, 1985.
- 11) **King KF and Rush J** : Closed intramedullary nailing of femoral shaft fractures. *J Bone Joint Surg*, 63-A:1319-1323, 1981.
- 12) **Klemm K and Schellmann WD** : Dynamische und statische werrgelung des arknagels. *Monastshr Unfallheik*, 75-568-575, 1972.
- 13) **Kiüntscher G** : Intramedullary surgical tenique, and its place in orthopaedic surgery. *J Bone Joint Surg*, 47-A:809-818, 1965.
- 14) **Muller ME, Allgower M and Schneider R** : Manual of internal fixation ; Technique recommended by the AO group. Berlin. Germany, Springer-Verlag, 1979.
- 15) **Muller ME and Thomas RJ** : Nonunion in fractures of long bones. *Clin Orthop*, 138:141, 1979.
- 16) **Whittle AP** : *Capbell 's Operative Orthopaedics 9th edition ed.* 2136-2167, St Louis, CV Mosby, 1998.
- 17) **Winqvist RA and Hansen ST** : Comminuted fracture of the femoral fractures. A report of five hundred and twenty cases. *J Bone Joint Surg*. 65-A:529-539, 1984.
- 18) **Winqvist RA, Hansen ST and Clawson DK** : Closed intramedullary nailing of femoral fractures. a report of five hundred and twenty cases. *J Bone Joint Surg*. 66-A:529-539, 1984.