



12, 2, 1999 4

The Journal of the Korean Society of Fractures
Vol.12, No.2, April, 1999

1/3

.

가

= Abstract =

Nonunion of the Fracture of Distal One-third of Femoral Shaft treated by Interlocking Intramedullary Nailing

Su-Chan Lee,M.D., Min-Ho Song,M.D.

Department of Orthopaedic Surgery, Gachon Medical College,
Dong Incheon Gil Medical Center, Incheon, Korea

The twelve nonunions of distal one-third fracture of femoral shaft after interlocking intramedullary nailing were treated with reaming and exchange nailing with a larger-sized nail, or reaming and exchange nailing with a larger-sized nail added with poller screw fixation. All the femoral nonunion were caused by insecure fixation of the intramedullary nailing, in which a instability of the fracture sites was verified in all cases during operation. The six of them were treated with reaming and exchange nailing. A simultaneous bone graft was performed in one of them to repair the bony defect. The other six of them were treated with reaming and exchange nailing added with poller screw fixation.

The result were as follows:

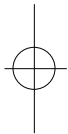
1. In six cases that treated with reaming and exchange nailing, patients walked bearing full weight on the extremity with mild aching at the fracture site within 3 months and not obtained a bony union until a 12 months.

:

117 (400-713)

가

Tel : (032) 764-9011





2. In one case that treated with reaming and exchange nailing added with poller screw fixation, patient walked bearing full weight on the extremity with mild aching at the fracture site within 3 months and not obtained a bony union until a 12 months.

3. In five cases that treated with reaming and exchange nailing added with poller screw fixation, patient walked bearing full weight on the extremity without aching at the fracture site within 3 months and obtained a bony union within a average of 7 months.

From our experience, etiology of nonunions of distal one-third fractures of femoral shaft is thought insecure fixation of the intramedullary nailing due to wide intramedullary canal. We have found reaming and exchange nailing with poller screw fixation is more helpful treatment that reaming exchange nailing as treatment for those fractures.

Key Words: Femoral shaft fracture, Distal one-third, Nonunion

가
1988 Brumbect 10,11) 2%
1995 1 1997 6 30 가
1/3
12 가가 56
12 12 10 , 2
39.2 ,
10 , 2 , 12
12
가 13.7
가
13,14,17,18,21,22)
1/3
6,12,20)
1/3
12
1/3
3.
6
1 가
6
poller 3



15

12 x-
가 5
7 12
(table 1).
가 , 7 13

(Fig. 1).

2. 3 O (/59)

59

1. 1 O (/36)

1/3

6

36

1/3

5

Table 1. Result

No	sex/age	1st F/U(mos)	Nonnion type	Treatment	POD 12 months	
					pain on walking	bone union
1	M/25	9	hypertrophic	exchange nailing	(+)	(-)
2	M/38	17	hypertrophic	exchange nailing	(+)	(-)
3	M/36	15	hypertrophic	exchange nailing	(+)	(-)
4	M/36	12	hypertrophic	exchange nailing	(+)	(-)
5	F/39	15	hypertrophic	exchange nailing	(+)	(-)
6	M/29	13	hypertrophic	exchange nailing	(+)	(-)
7	M/30	13	hypertrophic	exchange nailing	(+)	(-)
8	M/59	16	poller screw fixation	exchange nailing	(-)	(+)
9	F/47	12	hypertrophic	exchange nailing	(-)	(+)
10	M/43	17	poller scerw fixation	exchange nailing	(-)	(+)
11	M/46	14	hypertrophic	exchange nailing	(-)	(+)
12	M/52	12	poller scerw fixation	exchange nailing	(-)	(+)

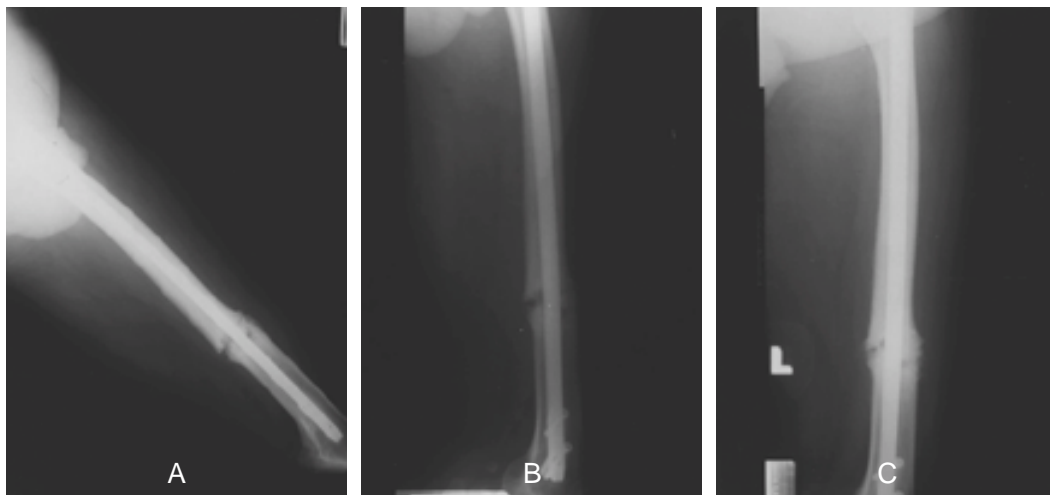
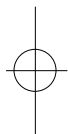

Fig 1. A 36-year-old man with interlocking intramedullary nailing of left femoral fracture for 15 months.

A. Radiographs at presentation showed a radiolucent line and a broken and loosed distal screw at the distal one-third femoral fracture site indicating hypertrophic nonunion. : femur AP, lateral

B. Radiographs immediately after exchange nailing.
: femur AP, lateral

C. Radiographs at 13 months after exchange nailing showed a radiolucent line and a loosening of distal screw at the distal one-third of femoral fracture site indicating hypertrophic nonunion.
: femur AP, lateral



16

poller

8

(Fig. 2).

5%

1,2,6,23) Brumbeck

10,11)

2%

Winguist 22,23)

0.5 - 3%

가

1/3

1940

1960

1984 Winguist 22,23)

20)

1/3

stress,


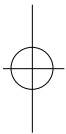


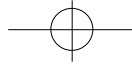
Fig 2. A 59-year-old man with interlocking intramedullary nailing of right femoral fracture for 16 months.

A. Radiographs at presentation showed a radiolucent line at the distal one-third of femoral fracture site indicating a nonunion. : femur AP, lateral

B. Radiographs immediately after exchange nailing and poller screw insertion. : femur AP, lateral

C. Radiographs at 8 months after exchange nailing and poller screw insertion showed a solid union. : femur AP, lateral





264 • / 12 2

20)

17,21)

가

6,12,16,21)

. 6 3

14)

, 3

poller

가

, unlocked nail locked nail , ,
13,17,18,19,21,22) Webb 22)

poller

가 3 2

1/3

105

96%

. McLaren & Blokker¹⁹⁾

5

80%

poller

. Steve 21) 17

. poller

가

100%

가 가

1/3

,

56

가

44

12

5cm

79%

12

6,15) poller

가

가

. poller

가

가

poller

,

40

가

1/3

1/3

6,12,20)

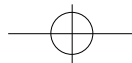
× .

1/3

가

가

가

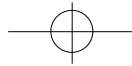


. poller

가 가

REFERENCES

- 1) , , : Interlocking nail
 , 29:591-597,
1994.
- 2) , , :
 , 29:100-110, 1994.
- 3) , , , , :
 , 28:1684-1690, 1993.
- 4) , , , :
 , 31:490-498, 1996.
- 5) , , , :
 , 11:181-189, 1998.
- 6) , , , , :
 , 24:954-960,
1989.
- 7) , , :
 , 27:1319-1327,
1992.
- 8) , :
 30:395-402, 1995
- 9) , :
 5:289-299, 1992.
- 10) **Brumback RJ, Uwagie-Ero S, Lakatos RP, Poka A, Bathon GH, Burgess AR** : Intramedullary nailing of femoral shaft fractures. *J Bone Joint Surg*, 70A:1453-1462, 1988.
- 11) **Brumback RJ** : The rationales of interlocking nailing of the femur, tibia and humerus ; an overview. *Clin Orthop*, 324:292-296, 1996.
- 12) **Bucholz RW, Ross WE and Lawrence KL** : Fatigue fracture of the interlocking nail in the treatment of fracture of the distal part of the femoral shaft. *J Bone Joint Surg*, 69A: 1391-1399, 1987.
- 13) **Chi-Chan Wu** : The Effect of dynamization on slowing the healing of femur shaft fractures after interlocking nailing. *The Journal of Trauma*, 43:263-267, 1997.
- 14) **Chi-Chuan Wu, Wen-Jer Chen** : Treatment of femoral shaft aseptic nonunions: comparison between closed and open bone-grafting Techniques. *The Journal of Trauma*, 43:112-116, 1997.
- 15) **Christian K, Peter S, Harald T** : Nonreamed interlocking nailing of closed tibial fractures with severe soft tissue injury. *Clin Orthop*, 315:34-47, 1995.
- 16) **Hannu T, Edmund YS** : Bone -healing patterns affected by loading, fracture fragment stability, fracture type, and fracture site compression. *Clin Orthop*, 293:8-17, 1993.
- 17) **Johnson RE** : Custom titanium plating for failed nonunion or delayed internal fixation failed nonunion or delayed internal fixation of femoral fractures. *Clin Orthop*, 234:195-203, 1988.
- 18) **Kessler SB, Hallfeldt KKJ, Perren SM, Schweiberer L** : The effects of reaming and intramedullary nailing on fracture healing. *Clin Orthop*, 212:18-25, 1986.
- 19) **Mclaren AC, Blokker CP** : Locked intramedullary fixation for metaphyseal malunion and nonunion. *Clin Orthop*, 265:253-260, 1991.
- 20) **Robert W.B, Robert J.B** : Fractures of the shaft of the femur. In ; *Rocwood and Green 's Fracture in adults*. 4th ed. philadelphia · New York, Lippincott-



Raven Pb : 1903-1906, 1996.

- 21) **Steve WN. Ueng, En-Kai Chao, Shiuann-Sheng Lee, Chun-Hsiung Shih** : Augmentative plate fixation for the management of femoral nonunion after intramedullary nailing. *The Journal of Trauma*, 43:640-644, 1995.

- 22) **Webb LX, Winqvist RA, Hansen ST** : Intra-

dullary nailing and reaming for delayed union of nonunion of the femoral shaft. *Clin Orthop*, 212:133-141, 1986.

- 23) **Winqvist RA, Hansen ST, Clawson DK** : Closed intramedullary nailing of femoral fractures. *J Bone Joint Surg*, 66:529-539, 1984.

