

12, 2, 1999 4

The Journal of the Korean Society of Fractures
Vol.12, No.2, April, 1999

Ender

*

가

= Abstract =

A comparison of fixation with Ender nail and sliding screw plate in intertrochanteric fractures of elderly patients

Joo-Hyoun Song, M.D., Yong-Koo Kang, M.D., Han-Yong Lee, M.D.,
Hae-Seok Koh, M.D., Kee-Won Rhyu, M.D., Kwang-Won Lee, M.D.

*Department of Orthopedic Surgery, St. Vincent Hospital,
The Catholic University of Korea*

In order to investigate the correlation between morbidity of the elderly patients and method of fixation, we analyzed 39 elderly patients had undergone internal fixation with Ender nail or sliding screw plate for the intertrochanteric fractures of the femur from January 1992 through December 1995. Among the 39 patients, 20 patients and 20 fractures were treated with Ender nail. Mean follow-up period was 26 months and average in age was 76.2 years. Remaining 19 patients, 19 fractures were treated with sliding screw plate. Mean follow-up period was 25 months and average in age was 75.4 years.

The results obtained were as follows :

1. In the cases where Ender nails were used, the average operation time took in the average of 45 minutes and whereby, in the cases where sliding screw plates were used, took in the

:

93 (442-060)

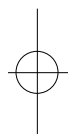
Tel : (0331) 249 - 7114 Fax : (0331) 254 - 8228



average of 110 minutes.

2. During the operation time, the amount of hemorrhage in the cases of Ender nail was about 100ml and the sliding screw plate resulted in about 350 ml. And the average amount of transfusion was 0.9 pints in cases of Ender nail and 2.3 pints in cases of sliding screw plate.
3. Among 20 patients fixed with Ender nail, only 2 patients had to be cared at ICU, but 9 of 19 patients had to be cared at ICU in the cases of sliding screw plates.
4. In the cases of Ender nail, the radiologic bony union time was about 13.4 weeks and they could walk with supports with in a week. But, in the cases of sliding screw plate the radiologic bony union time was about 16.2 weeks and they could walk with orthosis at 28.4 days postoperatively.
5. Most patients treated with Ender nail were suffered from the problem at knee and protrusion of Ender nail into the hip joint, backing out of nail through the entry, coxa valga deformity were major complications after the operation. In the cases of sliding screw plates, loosening of sliding screw with coxa vara deformity, wound infection and delayed union were major complications.
6. Despite of many complications, if the indication is chosen well, the fixation with Ender nail will result in a beneficial treatment method in the elderly patients for its advantages in general condition of the patients.

Key Words : Femur, Intertrochanteric fracture, Old age, Ender nail, Sliding screw plate.



1992 1 1995 12 가 가 가 39
, , 70 가
가 , 87%가 Singh 3
(sliding screw plate) (Table 1), 80%
Ender (Table 2).
, 3,12,18,20,22) Boyd-
, Griffin 5) 2
70% 가 (Table 3). Boyd-Griffin
가
가

Table 1. Singh index

				1992	
				Singh index	No. of cases (%)
1	1995	12	Ender		5 (12.2%)
					13 (33.3%)
					16 (41.0%)
					5 (12.2%)
			39 39		

**Table 2.** Associated diseases

Associated disease	No. of cases (%)		
	Ender	Sliding Screw Plate	Total
Cardiovascular disease	10(50%)	6(31.6%)	16(41.0%)
Pulmonary disease	5(25%)	4(21.1%)	9(23.0%)
Diabetes mellitus	3(15%)	2(10.5%)	5(12.8%)
Liver disease	0	2(10.5%)	2(5.1%)
	18(90%)	14(73.7%)	

Table 3. Type of intertrochantric fracture

Boyd-Griffin classification	No. of cases (%)
	6 (15.3%)
	27 (69.2%)
	2 (5.1%)
	4 (10.2%)

(1)

Ender
45 (35 105)
110 (40 180)

가

(P=6.22E-08).

가

(2)

Ender

Boyd-Griffin 1

가

Ender

100M(60M 140M)

350M(200M 500M)

가

(P=2.73E-11)

Ender

9

3

6

2

2

가 0.9 pint(0 2 pints),

,

70

90

2.3 pints(1 3 pints)

76.2

가 5

,

가 15

.

(P=1.51E-07).

19 19

7

3

5

2

(3)

가

3

70

88

Ender

20

75.4

,

가 6

,

가 13

.

2 (10%)

가 가

19

47.3% 9

가 가

,

가

,

가

,

5

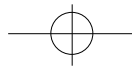
Ender

, 3

가

student-T test

5%

**Table 4.** Complications after Ender nail fixation

Complication	No. of cases (%)
Knee joint problem	15 (75%)
Backing out of nail	5 (25%)
Protrusion through femoral head	3 (15%)
Coxa valga	6 (30%)

Table 5. Complications after sliding screw plate fixation

Complications	No. of cases (%)
Coxa vara	10 (52.6%)
Wound infection	3 (15.7%)
Delayed union	2 (10.5%)

(4) 가
Ender 1 (5.7%)
28.4 (21.35%)
가 (P=2.38E-15).
가 가 .
가가
, , ,
(5)
Ender 13.4 (11.16%) , 5.7,13,33)
16.2 (12.21%)
Ender 가 Ender
(P=0.013). Boyd- 가 .
Griffin 4 Singh 2
가
Ender 16 , 20 moment arm
가
16,17)
(6)
Ender 20 15 (75%) 가
, 5 (25%)
, 3 (15%) 가 14,30,31)
6 (30%) Ender
가 21,31)
(Table 4). 19 10 4,9,10)
(52.6%) 가 bending moment가
3 (15.7%),
2 (10.5%) (Table 5). 2,9,15,25,34)
가
25).

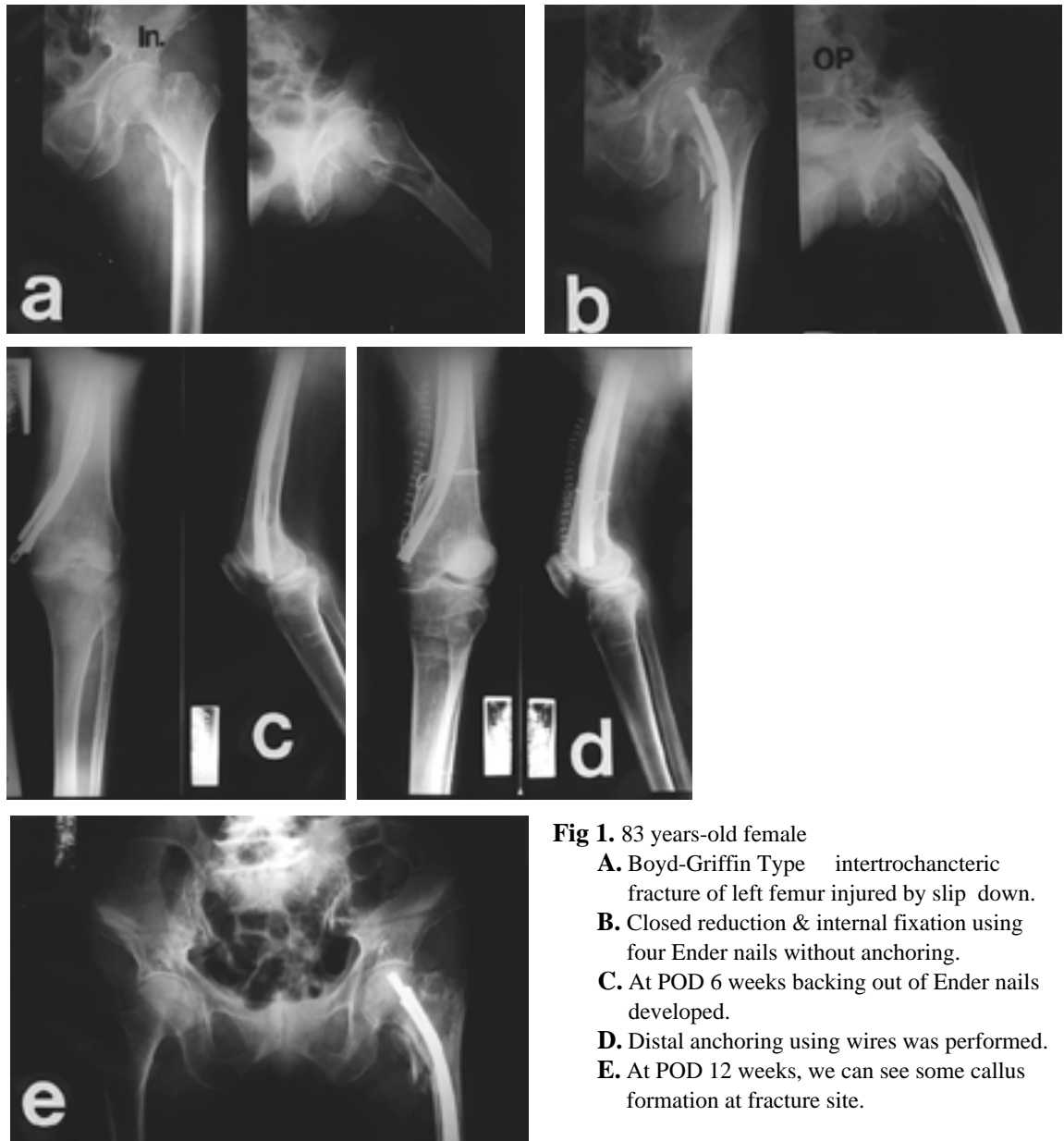


Fig 1. 83 years-old female

- A.** Boyd-Griffin Type intertrochanteric fracture of left femur injured by slip down.
- B.** Closed reduction & internal fixation using four Ender nails without anchoring.
- C.** At POD 6 weeks backing out of Ender nails developed.
- D.** Distal anchoring using wires was performed.
- E.** At POD 12 weeks, we can see some callus formation at fracture site.

Laros²³⁾
가

‘ low risk fixation ’ Ender 가

가

Ender

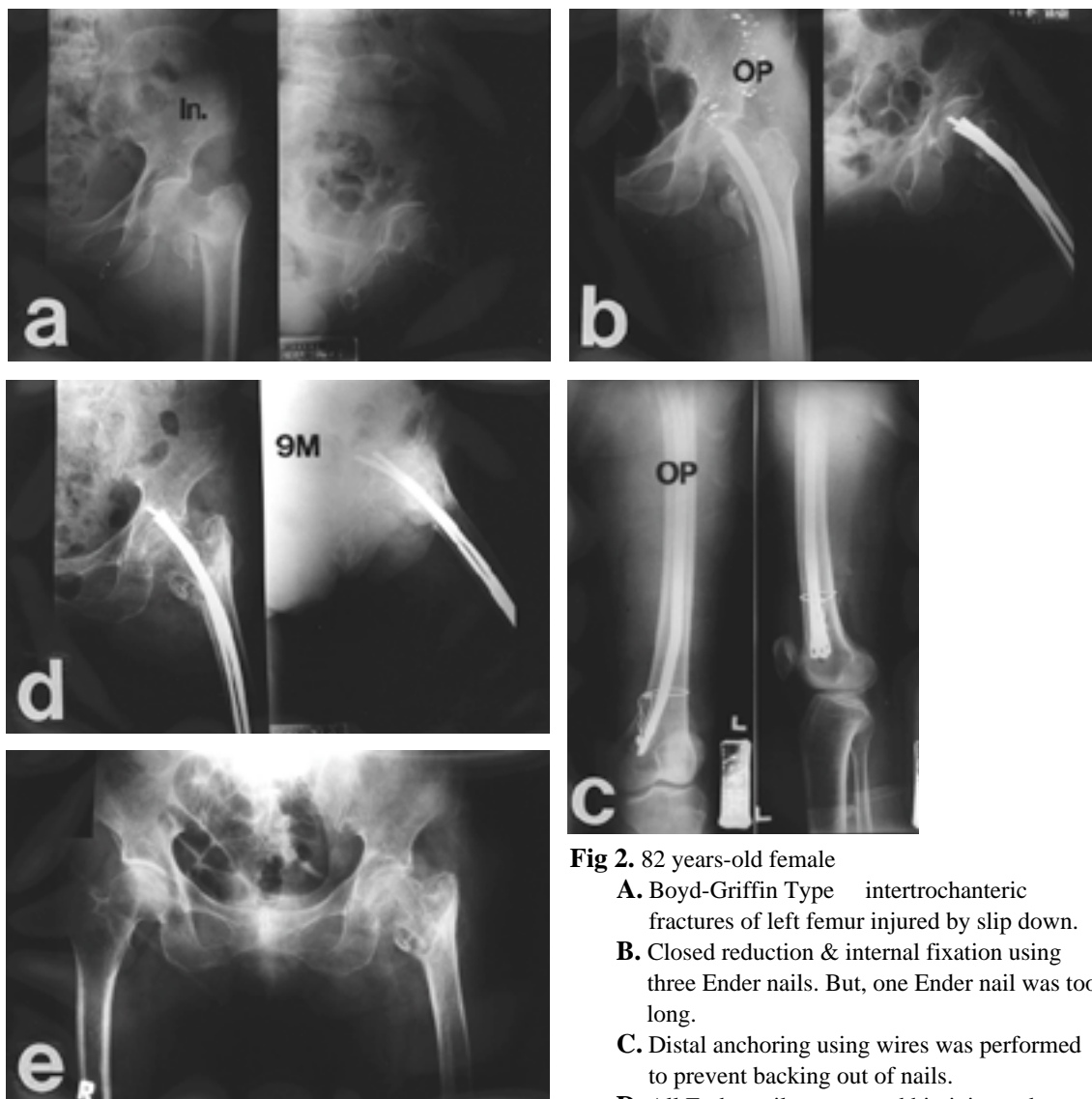


Fig 2. 82 years-old female

- A.** Boyd-Griffin Type intertrochanteric fractures of left femur injured by slip down.
- B.** Closed reduction & internal fixation using three Ender nails. But, one Ender nail was too long.
- C.** Distal anchoring using wires was performed to prevent backing out of nails.
- D.** All Ender nails penetrated hip joint and caused hip joint pain.
- E.** Ender nails were removed.

. Ender

6,8,10,19,32)

가 Ender

Ender

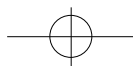
2

19,27)

75%

가

가
가



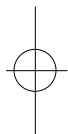
Ender 가 25% 가 40% 가 10).
 가 15% (Fig 1).
 . 가 1992 1 1995 12 가
 Ender 가 70
 Ender 가 가 , Ender
 가 Ender 3.5mm
 AO Ender 11,24,29)
 Ender 가

Ender
 (Fig 2) Fischer 11) 1cm

Ender

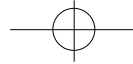
REFERENCES

- Ender
 Richmond 30)
 Olerud²⁸⁾ 25
 3 6
 Michael 26)
 Ender 13.4 ,
 16.2
 Ender
- 1) , , : , 12:147-152, 1977.
 - 2) **Aprin H and Kilfoyle RM** : Treatment of trochanteric fractures with Ender rods, *J Trauma*, 20:32-42, 1980.
 - 3) **Arsen MP and Imad ET** : Ender nailing intertrochanteric and subtrochanteric fractures of the femur. *J Bone Joint Surg*, 62-A:635-645, 1980.
 - 4) **Barrios C, Walheim G, Borstrom LA, Olson E, Stark A** : Walking ability after internal fixation of trochanteric hip fractures with Ender nail or sliding screw plates : a comparative study of gait. *Clin Orthop*, 294:197-292, 1993.
 - 5) **Boyd HB and Griffin LL** : Classification and treatment of trochanteric fractures. *Arch Surg*, 58:853-866, 1949.
 - 6) **Chapman MW, Bowman WE, Csongradi JJ, Day**





- LJ, Trafton PG, Bovill EG** : The use of Ender 's pin in extracapsular fractures of the hip. *J Bone Joint Surg*, 63-A:14-28, 1981.
- 7) **Clawson DK** : Trochanteric fractures treated by the sliding screw plate fixation method. *J Trauma*, 4:737-752, 1964.
- 8) **Cobelli NJ and Sadler AH** : Ender rods versus compression screw fixation of hip fractures. *Clin Orthop*, 201:123-129, 1985.
- 9) **Ender HG** : Treatment of peritrochanteric and subtrochanteric fractures of the femur with Ender pins in the hip : Proceedings of the sixth open scientific meeting of the hip society, *St Louis, CV Mosby* : 187-206, 1990.
- 10) **Evant CM** : Intertrochanteric fractures. Surgery of the musculoskeletal system. 2nd ed. London, *Churchil Livingstone* : 2618-2635, 1990.
- 11) **Fischer LP, Carret JP and Benjui J** : Fractures of the trochanteric region : 200 cases treated by Ender nailing. *Lyon Chiug*, 76:299-301, 1980.
- 12) **Greider JL and Horowitz M** : Clinical evaluation of the sliding compression screw in 121 hip fractures, *South Med J*, 73:1343-1348, 1980.
- 13) **Hafner RHV** : Trochanteric fractures of the femur. A review of eighty cases with a description of the " low-nail " method of internal fixation. *J Bone Joint Surg*, 33-B :513-516, 1951.
- 14) **Harris LJ** : Closed retrograde intramedullary nailing of peritrochanteric fractures of the femur with a new nail. *J Bone Joint Surg*, 62-A:1185-1193, 1980.
- 15) **Hormozan A and Richard MK** : Treatment of trochanteric fractures with Ender rods. *J Trauma*, 20:32-42, 1980.
- 16) **Jacobs RR, Armstrong HJ, Whitaker JH, Pazell J** : Treatment of intertrochanteric hip fractures with a compression hip screw and a nail plate. *J Trauma*, 16:599-603, 1976.
- 17) **Jenson JS** : Trochanteric fractures. *Acta Orthop Scand Suppl* 188:1-100, 1981.
- 18) **Jensonm JS, Sonne-Holm S, Tondevold E** : Unstable trochanteric fractures : A comparative Analysis of four methods of internal fixation. *Acta Orthop Scand*, 51:949-962, 1981.
- 19) **Jenson JS and Sonne-Holm S** : Critical analysis of Ender nailing in treatment of trochanteric fractures. *Acta Orthop Scand*, 51:817-825, 1980.
- 20) **Jenson JS, Tondevold E and Sonne-Holms** : Stable trochanteric fractures : A comparative analysis of four methods of internal fixation. *Acta Orthop Scand*, 51:811-816, 1980.
- 21) **Kunderna H, Bohler N, Pollon DJ** : Treatment of intertrochanteric and subtrochanteric fractures of femur. *J Bone Joint Surg*, 62A:635-645, 1980.
- 22) **Kyle RF, Gustilo RB and Premer RF** : Analysis of sixty hundred and twenty-two intertrochanteric hip fractures. *J Bone Joint Surg*, 61-A:216-221, 1979.
- 23) **Laros GS** : The role of osteoporosis in intertrochanteric fractures. *Orthop Clin North Am*, 11:525-537, 1980.
- 24) **Lester AR and Asho KS** : Treatment of intermedullary rods. *Clin Orthop*, 148:203-212, 1980.
- 25) **Martinek H, Egkher E, Wielke B, Spangler H** : Experimental tests concerning the biomechanical behavior of pentrochanteric osteosynthesis. *Acta Orthop Scand*, 50:675-679, 1979.
- 26) **Michael WC, William EB, John JC, Lorraine JD, Peter GT and Edwin GB Jr.** : The use of Ender 's pin in extracapsular fractures of the hip. *J Bone Joint Surg*, 63-A:14-28, 1981.
- 27) **Nungu S, Olerud C, Rehnberg L** : The treatment of intertrochanteric fractures : Comparison of Ender nails and sliding screw plates. *J Orthop Trauma*, 5:452-457, 1991.
- 28) **Olerud S, Stark A, Gilstrom P** : Malrotation following Ender nailing. *Clin Orthop*, 147:139-142, 1980.
- 29) **Pankovich AM** : Flexible intramedullary of long bone fractures : A review. *J Orthop Trauma*, 1:78-83, 1987.
- 30) **Richmond JC, Kazes JA and MacAusland WR** :



An evaluation of three current techniques of internal fixation for intertrochanteric and subtrochanteric fractures of the hip. *Orthopedics*, 4:895-898, 1981.

- 31) **Russin LA and Sonni A** : Treatment of intertrochanteric and subtrochanteric fractures with Ender 's intramedullary rods. *Clin Orthop*, 148:203-212, 1980.

- 32) **Sherk HH and Foster ML** : Hip fractures ; Condylcephalic rod versus compression screw.

Clin Orthop, 192:255-259, 1985.

- 33) **Taylor GM, Neufeld AJ and Nickel VL** : Complications and failures in the operative treatment of intertrochanteric fractures of the femur. *J Bone Joint Surg*, 37A:306-316, 1995.

- 34) **Tor SR, Andres M, Willy H, Ola H and Sven O** : Treatment of peritrochanteric and subtrochanteric fractures of the femur by Ender method. *Clin Orthop*, 138:231-237, 1979.

