



12, 1, 1999 1

The Journal of the Korean Society of Fractures
Vol.12, No.1, January, 1999

K-

.

. . . , . . .

= Abstract =

The Results of the Percutaneous K-wire Fixation for the Supracondylar Fractures of the Humerus in Children.

Chil-Soo Kwon, M.D., Jong-Kuk Ahn, M.D., Byung-Hyun Jeong, M.D.,
Yerl-Bo Sung, M.D., Dong-Soo Kim, M.D. Hyung-Jin Chung, M.D. and Ho-Cheol Rhee, M.D.

Department of Orthopedic surgery, College of Medicine, Inje University,
Sanggye Paik Hospital, Seoul, Korea

The cases of 160 patients who had a displaced supracondylar fracture of the humerus were reviewed retrospectively. According to the Flynn 's criteria, the results of treatment were excellent 33%, good 53%, fair 10%, poor 4%. No neurovascular complication was appeared. In two cases, cubitus varus deformity was appeared to be related with incorrect reduction. We believe that percutaneous k-wire fixation is excellent method in treatment of the displaced supracondylar fractures in children. There was no significant difference of clinical results among methods of percutaneous K-wire fixation but lateral 2 and medial 1 cross pinning has advantages : easy technique in insertion of lateral 2 pins, biomechanical stability and removal of medial pin in the irritation of ulna nerve without significant influence of stability.

Key Words : Humerus, Supracondylar fracture, Percutaneous K-wire Fixation

:

7 761-1 (139-207)

TEL:950-1032 FAX:934-6342



가
2

60% 가 가 ,

, ,

, ,

가

160 K-
2

1989 9 1995 5
14
K 160
1 4 10
1 4
95 (59.3%), 65 1.5:1
1 1 14 6.4
152
가 101 ,
가 51 , 가 5 , 3
(Table 1). 9

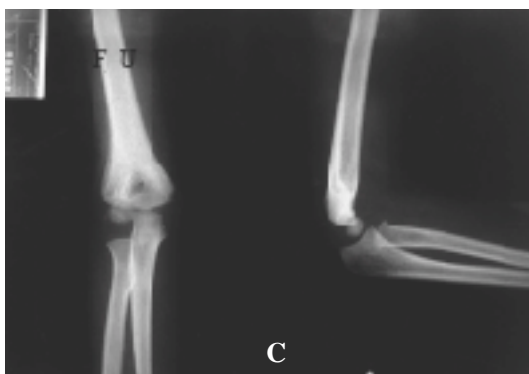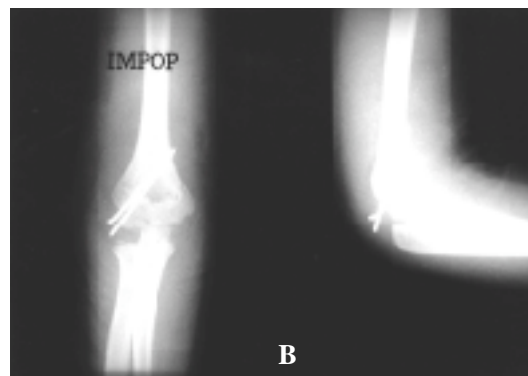
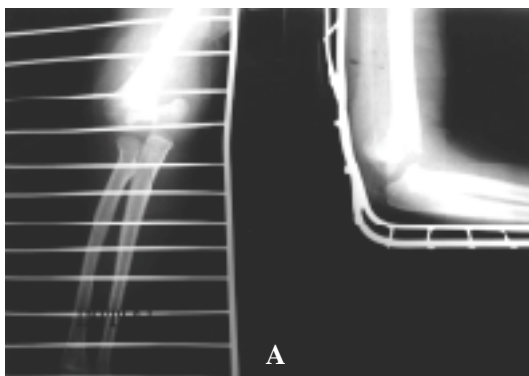
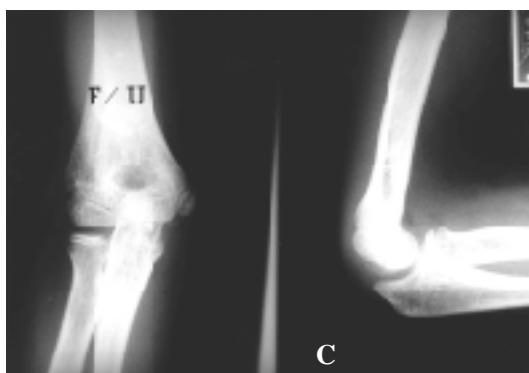
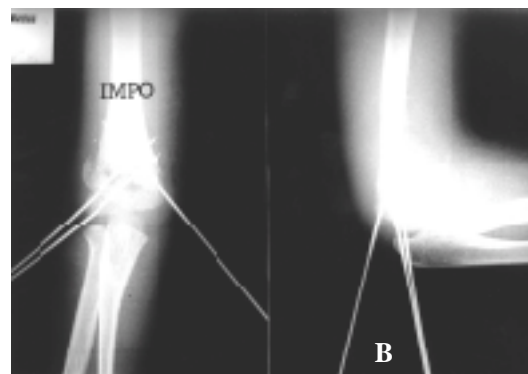
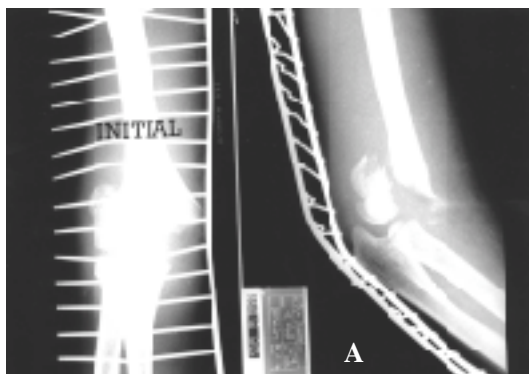


Fig 1.

- A.** initial radiograph of a 4 year-old girl who sustained right supracondylar fracture by fall
- B.** immediate postoperative x-ray
- C.** 4 months follow-up x-ray.

**Fig 2.**

- A.** initial radiograph of a 5 year-old boy who sustained right supracondylar fracture by fall from a height.
B. immediate postoperative x-ray.
C. 5 months follow-up x-ray show good bony union and acceptable Baumann 's angle.

Gartland

1 가

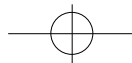
Table 1. Direction of Displacement

Direction	No. of Cases
Posteromedial	101
Posterolateral	51
Anteromedial	5
Anterolateral	3

Table 2. Mode of Pinning

Group	Pinning	No. of Cases
1	lat.(2)	81
2	lat.(2)+med.(1)	63
3	lat.(1)+med.(1)	16
Total		160

3
2
가가
(25)
12
2 3
14.7
가
1.6mm K-
45 , 10
Group 1(Figure 1),
가7
1.0
30
2



190 • / 12 1

Group 2(Figure 2), • 1 2 Group 2

Group 3 K- (Table 4).

(Table 2). K- Baumann

. 5 105

70 90 , , 5 10 47

. 32 , 15 . 10 8

30 1 7

27 . 7 .(Table 3). K-

3 5 가 7

K-

. K

Baumann 9

Flynn⁷⁾ , 가 4 3

. 6

Volkmann

9 4.6

. 52 (33%), 85

(53%), 16 (10%), 7 (4%) 160

153 (95.6%) .

14.3 , 5%

15.7 . Group 1 81 79 (97.5%) 60%가

, Group 2 63 58 (93.7%) 2) 5-9 가 62.6%

, Group 3 16 15 (93.8%) 가 7.6 , Arnold

7.3 6.4 .

Wilkins¹⁷⁾ 가 가 58.9%

58.6%, 가 59.3%

67% .

Rockwood 가 2.5% 8

5% . 가

가

Table 3. Baumann 's Angle

Angle	excellent	good	fair	poor	total
1 5 °	52	53	0	0	105
6 10 °	0	32	15	0	47
>10 °	0	0	1	7	8
Total	52	85	16	7	160

Table 4. Result in Each Group

	excellent	good	fair	poor
group 1	30	41	8	2
group 2	17	37	5	4
group 3	5	7	3	1
total	52	85	16	7

가 가



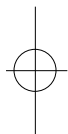
K

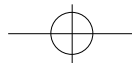
• 191

가 Baumann
5 100% . 10
9 가 95%
Pirone ¹²⁾ 96 2 K
160 9

가
Arino 2%, Prieto¹³⁾
1948 5%
Swenson¹⁵⁾ 27 9 58%, 3%
Herzenberg ¹⁵⁾ Chess ⁵⁾
2.0mm K-
. 1994 2
Zoint ²⁰⁾ Baumann 10
가 (torque) group 2 VIC
37% 80%가

2
12,20). Hadad Riordan¹¹⁾ 2
, 1 K
Fowler Kassab⁸⁾ Arino ³⁾ 2
87.5% 85%
가
가 16 75%
2
가 160 81 88% 2
63 2 97.5%
C-arm 가
2
1 가
가 83%
. Baumann
가
Worlock¹⁹⁾ 5
, Aronson Prager⁴⁾ 4 가





가

가

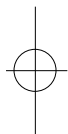
가

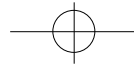
2

가

REFERENCE

- 1) , , , , , :
Baumann .
, 30 : 1658-1665, 1994.
- 2) , , , , :
, 25 : 1593-1601, 1990.
- 3) **Arino VL, Lluch EE and Ramirez AM** :
Percutaneous fixation of supracondylar fractures of
the humerus in children. *J Bone Joint Surg*, 59-A :
914-916, 1997.
- 4) **Aronson DD and Prager BI** : Supracondylar
fractures of the humerus in children : a modified
technique for closed pinning, *Clin. Orthop*, 219 :
174-184, 1985.8.
- 5) **Chess DG, Leahey JL and Hyndman JC** :
Singnificant factor, *J Pediatr Orthop*, 14 :190-192,
1994
- 6) **Cramer KE, Devito DP and Green NE** :
Comparision of closed reduction and percutaneous
pinning persus open reduction and percutaneous
pining in displaced supracondylar fractures of the
humerus in children. *J Orthop Trauma*, 6 : 407-412,
1992.
- 7) **Flynn J, Matthews J and Benoit R** : Blind pinning
of displaced supracondylar fractures of humerus in
children. Sixteen years experience with long-term
follow up. *J. Bone Joint Surg*, 56-A : 263, 1974
- 8) **Fowler JV and Kassab MT** : Displaced
supracondylar fractures of the elbow in children. A
report on the fixation of extension and flexion
fractures by two lateral percutaneous pins. *J. Bone
Joint Surg*, 56-B : 490-500, 1974
- 9) **France J and Strong M** : Deformity and function in
supracondylar fractures of the humerus in children
variously treated by closed reduction and splinting,
traction and percutaneous pinning. *J Pediatr Orthop*
12, 494-498, 1992
- 10) **Furrer M, Mard G and Rudei T** : Management of
displaced supracondylar fractures of the humerus in
children. *Injury*, 22 : 259-262, 1991.
- 11) **Haddad RJ, Saer JK and Riordan DC** :
Percutaneous pinning of the displaced supracondylar
fractures of the elbow in children. *Clin. Orthop*, 71 :
112-117, 1970.
- 12) **Pirone AM, Graham HK and Krajbich JI** :
Management of displaced extension-type
supracondylar fractures of the humerus in children.
J. Bone Joint Surg, 70A : 641, 1988.
- 13) **Prietto CA** : Supracondylar fractures of the
humerus. *J. Bone Joint Surg*, 60A : 653, 1978.
- 14) **Royce RO, Dutkowsky JP, Kasser JR and Rand
FR** : Neurologic complications after K-wire fixation
of supracondylar humerus in children. *J Pediatr
Orthop*, 11 : 191-194, 1991.
- 15) **Swenson AL** : The treatment of supracondylar
fractures of the humerus by K-wire transfixation. *J
bone Joint Surg*, 30 : 993-997, 1948.
- 16) **Uchida Y and Sugioka Y** : Ulnar nerve palsy after
supracondylar humerus fracture. *Acta Orthop
Scand.*, 61 : 118-119, 1990.
- 17) **Wilking KE** : Supracondylar fractures. In :
Rockwood CAJr, Wilkins KE and King RE ed.
Fractures in Children. 3rd Ed. pp. 596-605,
Philadelphia, J. B. Lippincott Co, 1990.
- 18) **Williamson DM, Coates CJ, Miller RK and Cole**





WG : Normal characteristics of the Baumann (Humerocapitellar) angle L An aid in assessment of supracondylar fractures. *J Pediatr Orthop*, 12 : 636-639, 1992.

19) **Worlock P** : Supracondylar fractures of the

humerus. *J. Bone Joint Surg*, 68B: 755-757, 1986.

20) **Ziont LD, McKellop HA and Hathaway R** : Torsional strength of pin configurations used to fix supracondylar fractures of humerus in children. *J Bone Joint Surg*, 76A : 253-256, 1994.

