

12, 1, 1999 1

The Journal of the Korean Society of Fractures
Vol.12, No.1, January, 1999

-

.

= Abstract =

Fracture-Dislocations of Carpometacarpal joints excluding thumb - A case report -

Hyung-Ku Yoon,M.D., Ho-Seung Jeon,M.D.,
Kye-Nam Cho,M.D. and Hong-Gweon Han,M.D.

*Department of the Orthopaedic Surgery , Sung Ae Hospital,
Seoul , Korea*

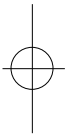
Fracture-Dislocations of the ulnar carpometacarpal joints is an uncommon injury. The priorities of management of other more extensive injuries often delay definitive treatment. If such a dislocation is diagnosed early, it can be reduced easily by closed means. We reviewed one case of fracture-dislocation of carpometacarpal joints excluding thumb with stable and pain free carpometacarpal joints in one year after closed reduction and internal fixation.

Key words: Carpometacarpal joint, Fracture-Dislocation.

:

1 451-5 (150-051)

TEL : (02) 840-7235 FAX : (02) 840-7755





가 29
(saddle joint) , , 5
가 , ,
, .
가 7,10). ,
(Fig.1-A,1-B).
5,6,8,12,13,14)
,
, (Brachial
, plexus block)
K-

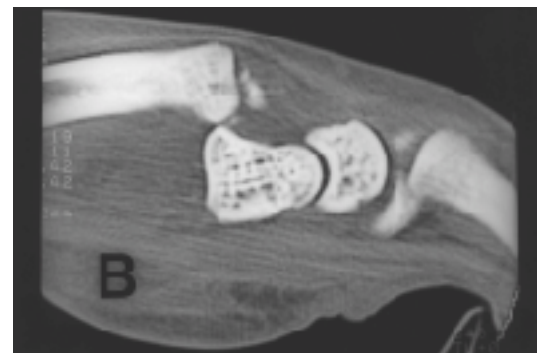
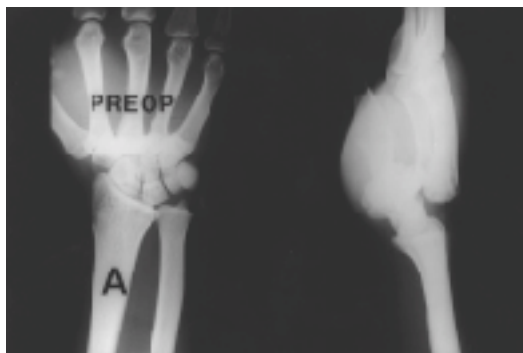


Fig. 1-A.Initial radiographs of the right wrist showing dorsal dislocation of carpometacarpal joints excluding thumb

1-B. Initial CT scan showing dorsal dislocation of carpometacarpal joints excluding thumb

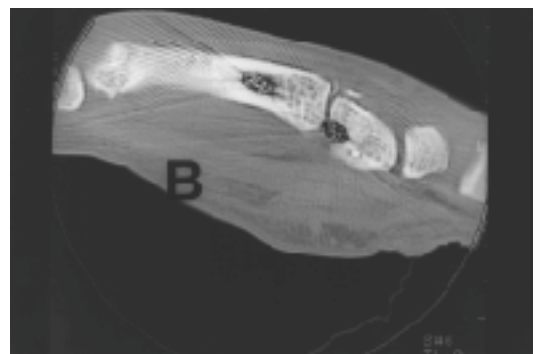
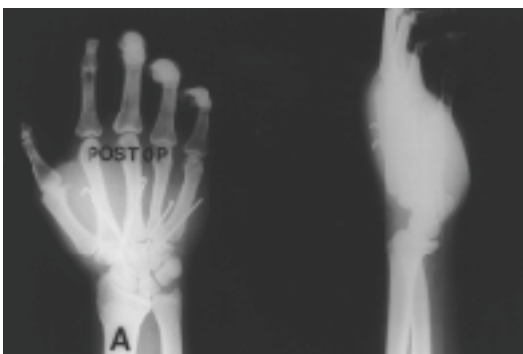
Fig. 2-A,B.Closed reduction and internal fixation of carpometacarpal joints excluding thumb(A ; Plain AP and lateral view, B ; Post operative CT scan)

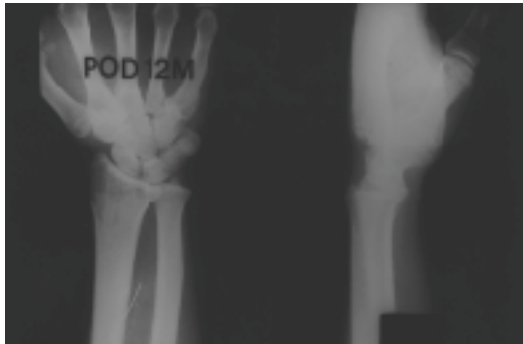
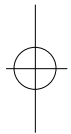


Fig. 3. Radiographs taken 1 year after the operation with congruous reduction of carpometacarpal joints excluding thumb



가 . Bunnell
가
가
(Fig.2- 가
A,2-B). 6 K- , 1 3
60. 55.
K-
(Fig.3). 가
가
13).
1,2,4,9,11,15). 1984 Fisher 가
3) 116 , 32 가
가
가 K-



REFERENCES

- 1) **Berg, E. E., and Murphy, D. F.** : Ulnopalmar Dislocation of the Fifth Carpometacarpal Joint - Successful Closed Reduction : Review of the literature and Anatomic Reevaluation. *J. Hand Surg.*, 11A:521-525, 1986.
- 2) **Bloom, M. L., and Stern, P. J.** : Carpometacarpal Joints of Fingers. Their Dislocation and Fracture-Dislocation. *Orthop. Rev.*, 12(9):77-82, 1983.
- 3) **Fisher, M. R.; Rogers, L. F.; Hendrix, R. W.; and Gilula, L. A.** : Carpometacarpal Dislocations CRC crit. Rev. Diag. Imag., 22:95-126, 1984.
- 4) **Gunther, S. F., and Bruno, P. D.** : Divergent Dislocation of the Carpometacarpal Joints : A Case Report. *J. Hand Surg.*, 10A:197-201, 1985.
- 5) **Hartwig, R. H., and Louis, D. S.** : Multiple Carpometacarpal Dislocations. A Review of Four Cases. *J. Bone and Joint Surg.*, 61-A:906-908, Sept., 1979.
- 6) **Kleinman, W. B., and Grantham, S. A.** : Multiple Volar Carpometacarpal Joint Dislocation. Case Report of Traumatic Volar Dislocation of the Medial Four Carpometacarpal Joints in a Child and Review of the Literature. *J. Hand Surg.*, 4:377-382, 1978.
- 7) **Nalebuff, E. A.** : Isolated Anterior Carpometacarpal Dislocation of the Fifth Finger. Classification and Case Report. *J. Trauma*, 8:1119-1123, 1968.
- 8) **Niechajev, I.** : Dislocated Intra-Articular Fracture of the Fifth Metacarpal : A Clinical Study of 23 Patients. *Plast. and Reconstr. Surg.*, 75:406-410, 1985.
- 9) **North, E. R., and Eaton, R. G.** : Volar Dislocation of the Fifth Metacarpal. Report of two Cases. *J. Bone and Surg.*, 62-A:657-659, June 1980.
- 10) **Petrie, P. W. R., and Lamb, D. W.** : Fracture-Subluxation of Base of Fifth Metacarpal. *Hand*, 6:82-86, 1974.
- 11) **Schutt, R. C., Jr.; Boswick, J. A., Jr.; and Scott, F. A.** : Volar Fracture-Dislocation of Carpometacarpal Joint of the Index Finger Treated by Delayed Open Reduction. *J. Trauma*, 21:986-987, 1981.
- 12) **Stephard, Edmund, and Solomon, D. J.** : Carpo-Metacarpal Dislocation. Report of Four Cases. *J. Bone and Joint Surg.*, 42-B(4):772-777, 1960.
- 13) **Waugh, R. L., and Yancey, A. G.** : Carpometacarpal Dislocations. With Particular Reference to Simultaneous Dislocation of the Bases of the Fourth and Fifth Metacarpals. *J. Bone and Joint Surg.*, 30-A:397-404, April 1948.
- 14) **Whitson, R. O.** : Carpometacarpal Dislocation. A Case Report. *Clin. Orthop.*, 6:189-195, 1955.
- 15) **Wray, R. C.** : Carpometacarpal Joint.. In *Acute Bone and Joint Injuries of the Hand and Wrist. A Clinical Guide to Management*, pp.93-119. Edited by P. M. Weeks. St. Louis, C. V. Mosby, 1981.

