

12, 1, 1999 1

The Journal of the Korean Society of Fractures
Vol.12, No.1, January, 1999

- 1 -

.

= Abstract =

Delayed Rupture of the Extensor Pollicis Longus due to Fracture of the distal radius

-A Case Report-

Soo-Jae Yim, M.D., Yeon-Cheol Jeong, M.D., Seung-Ryeol Yoon, M.D.,
Joong-Geun Choi, M.D., You-Sung Suh, M.D., Soo-Kyun Rah, M.D.

Department of Orthopedic Surgery, Soonchunhyang University Kumi Hospital

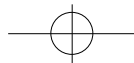
After distal radius fracture, delayed rupture of extensor pollicis longus is rare. It is known that delayed rupture of extensor pollicis longus tendon result from undisplaced distal radius fracture. We have experienced a case of rupture of the extensor pollicis longus tendon after undisplaced distal radius fracture, and treated with palmaris longus tendon graft. the result were satisfactory without complications.

Key Words : Extensor Pollicis Longus , Undisplaced Distal Radius fracture,

:

657

Tel : 02-709-9257 Fax:



4 , 2 가 . ,
 1876 ,
 Duplay³⁾ 가 가 .
 5,200
 10 15 mm/hr, 6.0 IU/ml
 1 .
 7cm 가
 Kessler
 62 10 , 4 , 6

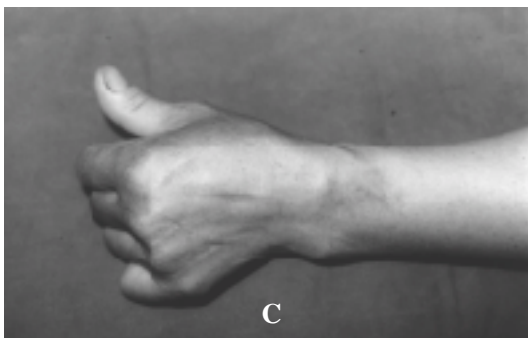
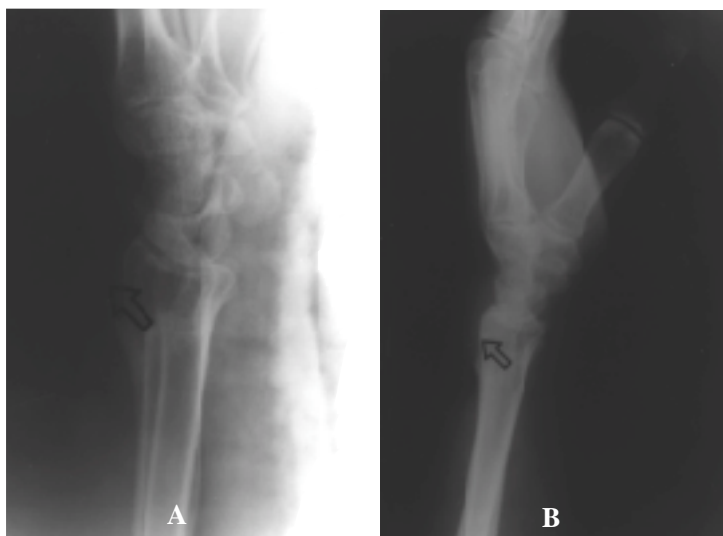
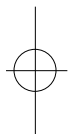


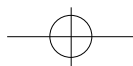
Fig 1. Preoperative lateral radiograph.

Arrowhead indicate dorsal projection of callus.

Fig 2. Postoperative lateral radiograph.

Arrowhead indicate excised site of dorsal projection of callus.

Fig 3. The photograph shows full extended thumb in 16 months after operation



164 • / 12 1

. 16
가

4).

가

가

Duplay(1876), Trevor(1950), Coovey(1980)

3),9),2). Riddell Colles

8).

, Trevor

11

9). Riddell

5),7).

. Christophpe

REFERENCE

1) **Christophe K** : Rupture of the extensor pollicis longus. *J Bone Joint Surg*, 35-A:1003-1005, 1953.

2) **Coovey WP, Dobyns JH and Linscheid MD** : Complication of Colles ' fractures. *J Bone Joint Surg*, 62-A:613-619, 1980.

3) **Duplay S** : Rupture sous-cutan e du tendon du extenseur du pouce de la main droite, au niveau de la tabaitre anatomique. Flexion permanente du pouce. R tablissement de la facult d 'extension par une op ration(suture de l 'extr mit du tendon rompu avec le premier radial externe). Bull.et M m. Soc. Chir. de Paris, 2;788-791, 1876(cited from Kenneth Christophe : Rupture of the extensor pollicis longus tendon following Colls ' fracture. *J Bone Joint Surg*, 35-A:1003-1005, 1953)

4) **Hamlim C and Littler JW** : Restoration of the extensor pollicis longus tendon by an intercalated graft. *J Bone Joint Surg*, 59A:412-414, 1977.

5) **Helal B, Chen CS and Iwegbu G** : Rupture of the extensor pollicis longus tendon I undisplaced Colles '

1).

8),9).

Christophe가

가

1), Riddell

8). Helal

Colles

가

가

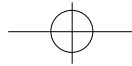
5).

가

가

가

7). Hamlin Littler가



- type of fracture. *The Hand*, 14:41-47, 1982.
- 6) **Hove LM** : Delayed rupture of the thumb extensor tendon. *Acta Orthop Scand*, 65(2):199-203, 1994.
- 7) **Raoul Tubiana** : The Hand. 1st ed. Philadelphia, WB Saunders Co :154-156, 1988.
- 8) **Riddel DM** : Spontaneous rupture of extensor pollicis longus. *J Bone Joint Surg*, 45-B:506-510, 1963.
- 9) **Trevor D** : Rupture of the extensor pollicis longus tendon after Colles' fracture. *J Bone Joint Surg*, 32-B:370-375, 1950.

