



12, 4, 1999 11

The Journal of the Korean Society of Fractures
Vol.12, No.4, November, 1999

- 1 -

• • • • *

• *

= Abstract =

Simultaneous Fracture-Dislocation of the Carpometacarpal and Metacarpophalangeal joint of the Thumb

Ho-Rim Choi, M.D., Sung-Jun Han, M.D., Sang-Seon Lee M.D.,
Chi-won Lee, M.D. and Byeong-Lok Jin M.D.*

Department of Orthopedic Surgery, Sun General Hospital, Tae-jon, Korea
Tae-jon Tongbu Orthopedic Clinic*

Simultaneous multiple dislocation of the thumb is a very rare injury. We experienced a case of simultaneous fracture-dislocation of the carpometacarpal and metacarpophalangeal joint of the thumb which was treated by closed reduction and percutaneous K-wire fixation. The clinical result was satisfactory.

Key Words : thumb, carpometacarpal joint, metacarpophalangeal joint, simultaneous fracture-dislocation, closed reduction and K-wire fixation

: Ho-Rim Choi, M.D.
Department of Orthopedic Surgery, Sun General Hospital
10-7, Mok-dong, Jung-ku, Tae-jon 301-070, Korea
Tel : (042) 220-8867, 8860
Fax : (042) 256-7246
E-mail : hrchoi@sunhospital.com



1032 •

/ 12 4

가

Noor²⁾

2 가

Moore⁴⁾ Ibrahim

(Fig.2).

K-

4

6 K-

. 1

40
가

10m

1). Green 1)

가

1

가

(

Fig.1).

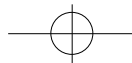
3).

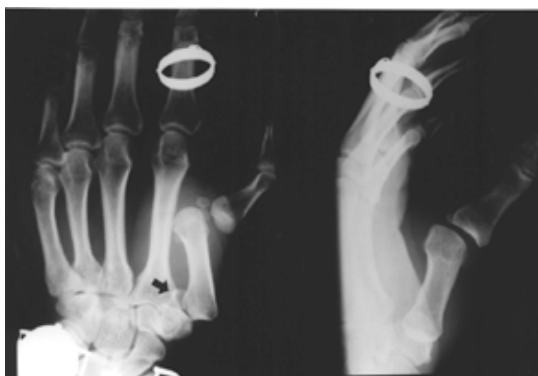

Fig 1. Initial X-ray shows simultaneous dislocation of the metacarpophalangeal and carpometacarpal joint. Chip bone fracture of the 1st metacarpal base is also seen (arrow).

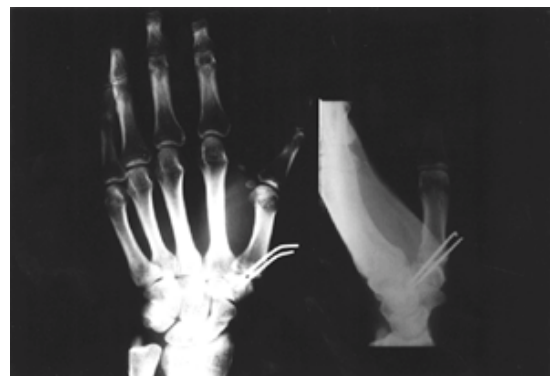

Fig 2. Postoperative X-ray shows well-reduced metacarpophalangeal and carpometacarpal joint with K-wire fixation of carpometacarpal joint.



REFERENCE

- 1) **Green DP, Butler Jr. TE** : Fractures and dislocations in the hand. In : Rockwood Jr. CA, Green DP, Bucholz RW and Heckman JD eds. Fractures in Adults. 4th ed. *Lippincott-Raven*: 707-723, 1996
- 2) **Ibrahim S, Noor MA** : Simultaneous dislocations of the carpometacarpal and metacarpophalangeal joints of the thumb. *Injury* 24:343-344, 1993
- 3) **Inoue G, Miura T** : Locked metacarpo-phalangeal joint of the thumb. *J Hand Surg* 13B:469-473, 1988
- 4) **Moore JR, Webb Jr. CA and Thompson RC** : A complete dislocation of the thumb metacarpal. *J. Hand Surg.* 3:547-549, 1978.
- 5) **Shah J, Patel M** : Dislocation of the carpometacarpal joint of the thumb. A report of four cases. *Clin Orthop* 175:166-169, 1983
- 6) **Strauch RJ, Behrman MJ, Barbara S and Rosenwasser MP** : Acute dislocation of the carpometacarpal joint of the thumb: An anatomic and cadaver study. *J Hand Surg* 19A:93-98, 1994
- 7) **Watt N, Hooper G** : Dislocation of the trapezio-metacarpal joint. *J Hand Surg* 12B: 242-245, 1987