



12, 2, 1999 4

The Journal of the Korean Society of Fractures
Vol.12, No.2, April, 1999

Kienböck

. . * . . .

= Abstract =

Scaphocapitate Fusion for Kienböck disease

Jun-Young Yang, M.D., Hyun-Dae Shin M.D., Sang-Ro Ahn, M.D. *,
Kwang-Jin Rhee, M.D., Jun-Kue Lee, M.D. and Jung-Hee Choi, M.D.

Department of Orthopaedic Surgery, School of Medicine,
Chungnam National University, United Orthopaedic Hospital*, Taejeon, Korea

We reviewed 14 patients treated with scaphocapitate fusion for Kienböck's disease (Lichtman stage) with mean follow-up of 26 months (ranging from 1 years to 5 year). There were five mens and nine womens. The mean age of patients at the time of operation was 46.1 years (ranging from thirty one to sixty). According to Lichtman's classification, All patients were stage . Clinical assessments were evaluated using by pain relief, limitation in range of motion and clinical improvement. Radiologic assessment was evaluated by carpal height ratio. The mean range of motion is flexion 30 degree, extension 41 degree preoperatively, and flexion 29 degree, extension 41 degree postoperatively. The mean carpal height ratio is 0.49 preoperatively and 0.48 postoperatively. All of cases are relief of pain. Therefore radiographic and clinical satisfactory results were obtained. In conclusion, scaphocapitate fusion appear to be a very effective method for Lichtman stage of symptomatic Kienböck's disease.

Key Word : Lunate, Kienböck disease, scaphocapitate fusion

:

640 (301-040)

Tel : (042) 220 - 7351, 7342, 7343 Fax : (042) 252 - 7098

*

1998



14 Kienböck disease ,

1894 peste

가 , 1920 Kienböck

가 ,

1-5) 가 ,

Alexander, Lichtman

1993 3 1998 3 ,

Kienböck disease

42 , Lichtman stage

18 , 1

2,3,4,8,9),

1 2 가 가 14

7,8) , 3 가 7 , 5:9

40 (salvage procedure) (Table 1).

dominant hand 가 6 , non-dominant hand 가 8 ,

Lichtman 3 Kienböck disease 2

Watson 19)

(Triscape fusion)

8

(Table 1) , 14 Litchman stage

Table 1. Scaphocapitate Fusion of Kienböck Disease

Case	Age/Sex	Follow-up	Ulnar variance	R.O.M.(degree)								Carpal height ratio	
				Pre-op				Post-op				Pre-op	Post-op
				AF	AE	UD	RD	AF	AE	UD	RD		
1	M/42	3yr	Ulnar negative	30	40	20	19	30	40	25	15	0.49	0.48
2	M/38	2yr	Ulnar negative	25	30	23	20	35	40	25	20	0.45	0.45
3	M/31	3yr	Ulnar negative	30	35	20	18	30	35	20	20	0.41	0.42
4	M/35	4yr	Ulnar negative	35	35	30	20	35	30	30	18	0.43	0.41
5	M/29	2yr	Ulnar negative	32	35	28	20	30	35	30	19	0.44	0.43
6	F/28	3yr	Ulnar positive	30	40	17	17	29	38	18	18	0.52	0.51
7	F/35	1yr	Ulnar negative	28	37	20	19	30	35	20	20	0.55	0.54
8	F/39	2yr	Ulnar neutral	30	42	19	18	30	40	19	20	0.50	0.49
9	F/42	5yr	Ulnar neutral	32	43	21	20	32	41	20	19	0.48	0.48
10	F/49	3yr	Ulnar neutral	29	40	25	19	30	40	25	20	0.45	0.46
11	F/47	3yr	Ulnar positive	32	45	23	20	30	40	20	18	0.46	0.47
12	F/40	2yr	Ulnar negative	30	40	19	19	30	40	18	18	0.54	0.53
13	F/51	2yr	Ulnar negative	33	38	21	20	35	39	20	20	0.51	0.51
14	F/55	3yr	Ulnar neutral	30	42	19	18	29	41	20	15	0.48	0.49

R.O.M.=Range of Motion, AF/AE=Active flexion/Active extension

UD/RD=Ulnar deviation/Radial deviation



448 •

/ 12 2

1

< 1>

42

18

9

K-wire

가

가

(Table 1), thumb-spica cast

8 K- 12

(Fig 1), 30 , 40 , ulnar

negative variance (carpal height ratio)

0.48 24 (Fig 2)

30 , 40

0.48 가

< 2>

38 2 3

가 (Table 1),

carpal height ratio

0.49, 0.48

(Table 1).

1

(Fig 3). 2 2

35 , 40 가

0.45 (Fig 4).

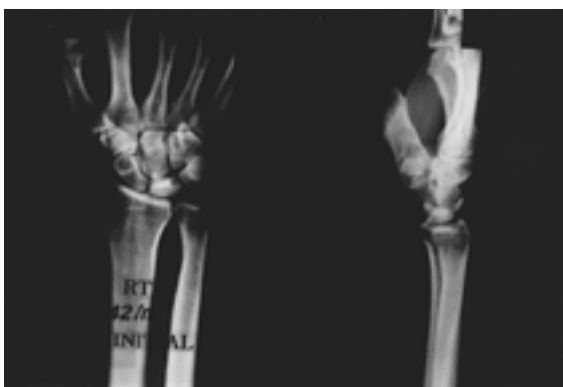

Fig 1. Anteroposterior and lateral view of wrist of 42-year-old men with Litchman stage III of Kienböck disease.

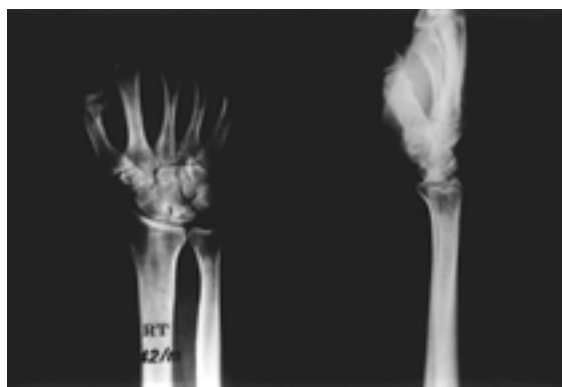

Fig 2. Anteroposterior and lateral view of wrist at 24 months after scaphocapitate fusion and good union.

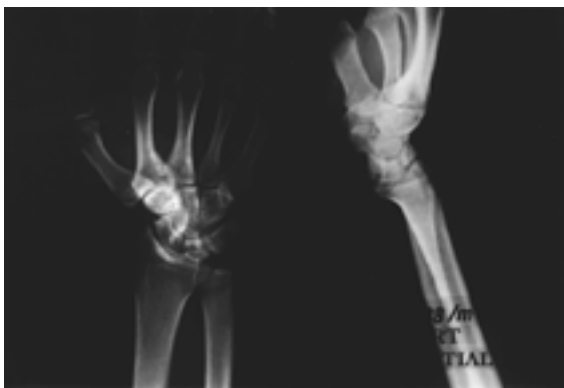


Fig 3. Anteroposterior and lateral view of wrist of 38-year-old men with Lichtman stage III of Kienbock disease. Radiograph showed sclerosis on lunate.

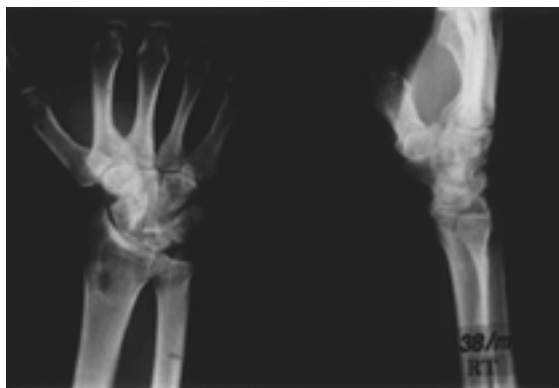


Fig 4. Anteroposterior and lateral view of wrist at 26 months after scaphocapitate fusion. Radiograph show good union.

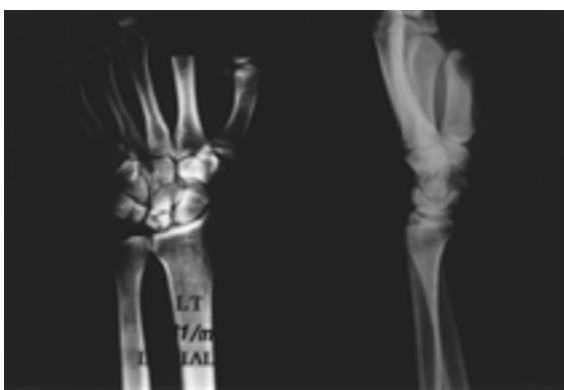

Fig 5. Anteroposterior and lateral view of wrist of 31-year-old men with Lichtman stage III of Kienbock disease.

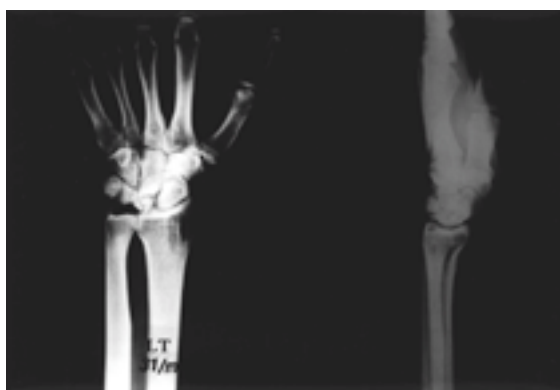


Fig 6. Anteroposterior and lateral view of wrist at 28 months after scaphocapitate fusion. Radiograph show good union.

< 3>

31

14

30

lunato- malacia, aseptic

35

Lichtman stage III

necrosis, osteochondritis, traumatic osteoporosis

(Fig 5),

28

가

30

35

0.41

(Fig 6).

가



450 • / 12 2

11) . 가 .

20 40 Lichtman stage 14

, 2

13,14) . (Table 1).

11) .

cortical ring sign Terry-Thomas sign 1993 3 1998 3

Lichtman 4 Kienböck 's disease

14

1. 가 5 , 가 9 .

2. 2

stage Revascularization, Joint leveling 3. 2 2 ,

procedure, silicon .

. Revascularization , joint 4. carpal collapse ,

leveling procedure 1 , 2

가

5. 3 Kienböck disease

가

REFERENCES

- 가 . stage
- 가 Kienböck
- 1) , : Ulnar Variance
- 가 Kienböck
- 17 2 , 277-282, 1982.
- 2) **Alexander, A.H. and Lichtamn, D.M.** : Kienböck 's disease. *Orthopedic clinics of North America.*, vol. 17, No. 3, July 1986.
- 3) **Almquist, E.E. and Burns, J.F.** : Radial shortening for the treatment of Kienböck 's disease-5-to 10 -year follow-up. *J. of Hand Surg.*, 7: 348-352, 1982.
- 4) **Armistead, R.B., Linscheid, T.L. and Dobyns, J.H. et al.** : Ulnar lengthening in the treatment of Kienböck 's disease. *J. Bone Joint Surg.*, 64A: 3~70-178, 1982.
- 5) **Beckenbaugh, R.D., Shves, T.C. and Dobyns, J.H.**
- 가
- Watson ¹⁹⁾ , ,
- (lat. columan)
- 가
- 가
- 가
- 20-23).



- et al.** : The natural history of Kienböck 's disease and consideration of lunate fracture. *Clin. Orthop.*, 149: 98-106, 1980.
- 6) **Bolhofner, B. and Besole, R.J.** : Kienböck 's disease: Current concepts in diagnosis and management. *Contemp. Orthop.*, 3: 713-720, 1981.
- 7) **Braun, R.** : The pronator pedicle bone grafting in the forearm and proximal carpal row. *Presented at the 38th Annual Meeting of the American Society for Surgery of the Hand, Anaheim, California, March 1983.*
- 8) **Braun, R.M.** : Viable pedicle bone grafts. (Abstract) What 's New and What 's True. *UC Davis Orthopedic Symposium*. March 1985, pp. 28-29.
- 9) **Erbs, G. and Bohm, E.** : *Langzeitergebnisse der os pisiforme-verlagerung bei mondbeinnerkkrose.* Handchirurgie, 16: 85-89, 1984.
- 10) **Fu, F.H. and Imbriglia, J.F.** : An anatomical study of the lunate bone in Kienböck 's disease. *Orthopedics*, 8: 483-487, 1985.
- 11) **Gelberman, R.H., Bauman, T.D. and Menon, J. et al.** : The vascularity of the lunate bone and Kienböck 's disease. *J. Hand Surg.*, 5: 272-278, 1980.
- 12) **Graner, O., Lopes, E.I. and Atlas.** : Arthrodesis of the carpal bones in the treatment of Kienböck 's disease, painful united fractures of the navicular and lunate bones with avascular necrosis, and old fracture-dislocations of carpal bones. *J. Bone Joint Surg.*, 48A: 767-774, 1966.
- 13) **Lichtman, S.H., Alexander, A.H. and Mack, G.R.** : Kienböck is disease: The role of silicone replacement arthroplasty. *J. Hand Surg.*, 7: 343-347, 1982.
- 14) **Lichtman, S.H., Mack, G.R. and McDonald, R.I. et al.** : Kienböck 's disease: The role of silicone replacement arthroplasty. *J. Bone Joint Surg.*, 59A: 899-908, 1977.
- 15) **Nahigian, S.H., Li, C.S. and Rickey, D.G et al.** : The dorsal flap arthroplasty in the treatment of Kienböck 's disease. *J. Bone Joint Surg.*, 52A: 245-251, 1970.
- 16) **Ovesen, J.** : Shortening of the radius in the treatment of lunatomalacia. *J. Bone Joint Surg.*, 63B: 231-251, 1981.
- 17) **Peste** : Cited from Nahigian, Sh.H. et al.: The dorsal flap arthroplasty in the treatment of Kienböck 's disease. *J. Bone Joint Surg.*, 52A: 245-251, 1970.
- 18) **Stahl, F.** : On lunatomalacia(Kienböck 's disease): A clinical and roentgenological study, especially on it 's pathogenesis and the late result of immobilization treatment. *Acta Chir Scand*: 126, 1947.
- 19) **Watson, H.K, Ryu, J. and BMPella, A.** : An approach to Kienböck 's disease: triscaphe arthrodesis. *J. Hand Surg.*, 10A: 179-187, 1985.
- 20) **Watson, H.K and Ryu, J.** : Evolution of arthritis of the wrist. *Clin. Orthop.*, 202: 57-67, 1986.
- 21) **Condit DP, Idler RS, Pischel IJ, et al.** : Pre-operative factors and outcome after lunate decompression for Kienböck 's disease, *J Hand Surg. /AM/* 18: 691-696.
- 22) **Fortin PT, Louis DS** : Long-term follow up of scaphoid-trapezium-trapezoid arthrodesis, *J Hand Surg /Am/* 18:675-681, 1993.
- 23) **Ishida O, Tsai TM** : Complications and results of scapho-trapezio-trapezoid arthrodesis. Presented at the 46th annual meeting of the American Society for Surgery of the Hand, Orlando, Florida, October 2 to 5, 1991.
- 24) **Lkeinman WB, Carroll C** : Scapho-trapezio-trapezoid arthrodesis for treatment of chronic static and dynamic scapho-lunate instability: a 10 year perspective on pitfalls and complications, *J Hand Surg ;Am*, 15: 408-414, 1990.