

## Intracavitary Urokinase in the Treatment of Multiloculated Liver Abscess : A Case Report<sup>1</sup>

Jeong Min Lee, M.D., Mi Suk Lee, M.D., Jin Hee Lee, M.D.<sup>2</sup>, Seong Hee Ym, M.D.<sup>2</sup>  
Chong Soo Kim, M.D.<sup>3</sup>, Young Min Han, M.D.<sup>3</sup>, Ki Chul Choi, M.D.<sup>3</sup>

Radiologically-guided percutaneous abscess drainage has been preferred as a therapeutic modality for hepatic abscesses, though where these have been septated or multilocular, its success rate has often been low. The results of several clinical and in vitro studies have recently suggested that in difficult cases, where abscesses occur in the peritoneal cavity and retroperitoneum, or multiloculated empyema of the thorax, urokinase may be useful. To our knowledge, however, there has been only one report of a case of liver abscess in which intracavitary urokinase was administered. The authors therefore report a case of multiseptated hepatic abscess occurring in a 53-year-man. Conventional percutaneous tube drainage failed, but the use of transcatheter intracavitary urokinase was successful. Diagnosis and continuing assessment involved a combination of ultrasound and CT scanning.

**Index Words :** Liver, abscess

Abscess, percutaneous drainage

Urokinase

Percutaneous drainage of a liver abscess is accepted as an effective alternative to surgical drainage, but the success rate for the drainage of septate or multilocular liver abscesses is lower than for simple abscesses (1, 2). Intrapleural fibrinolytic therapy to accelerate drainage of loculated hemothorax and empyema has been reported (3, 4), and Volgelzang et al (5) described the successful use of transcatheter intracavitary fibrolysis in the treatment of infected intraabdominal post-surgical hematomas in two patients. To our knowledge, the radiologic literature contains only one report of the application of urokinase to a liver abscess (6). We describe here the successful use of transcatheter intracavitary urokinase in the treatment of a multiloculated pyogenic liver abscess in one patient.

### Case Reort

A 53-year-old man was admitted to hospital for the evaluation of right upper quadrant pain, myalgia and a fever of 39–40 °C. Abdominal examination revealed right upper quadrant tenderness, but no rebound. He has no history of heavy alcohol intake, hepatitis or other liver disease but had undergone blood transfusions. For ten years he had suffered diabetes mellitus, without delicate control of blood sugar level, and had undergone a cholecystectomy three years due to acute calculous cholecystitis, previously. His white blood cell count was 18,500 cells/mm<sup>3</sup>, serum glucose was 251mg/dl, and routine urinalysis showed 3+ glucose.

Abdominal ultrasound revealed a well defined, hypoechoic cystic mass with some septations and an inhomogenous internal echo pattern in the right lobe of the liver (not shown). Abdominal computed tomography in this area showed a well circumscribed, low attenuated lesion, 8cm in diameter and with mutiple septations and an enhancing peripheral rim (Fig. 1A). The preliminary diagnosis was pyogenic liver abscess

<sup>1</sup>Department of Diagnostic Radiology, Namwon Medical Center

<sup>2</sup>Department of Internal Medicine, Namwon Medical Center

<sup>3</sup>Department of Diagnostic Radiology, Chonbuk National University College of Medicine

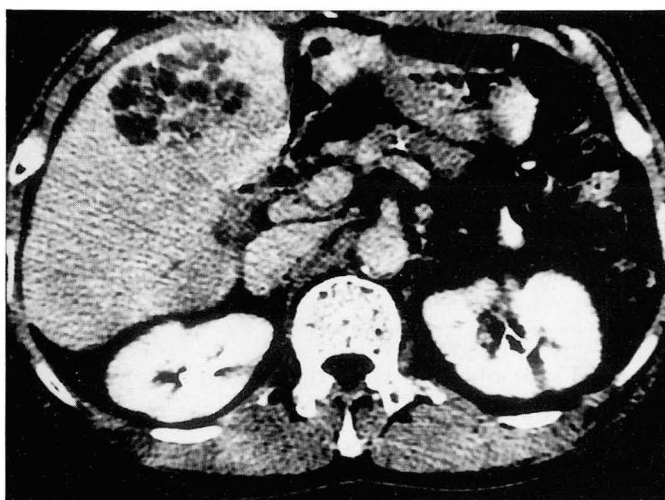Received April 14, 1997; Accepted June 13, 1997

Address reprint requests to: Jeong Min Lee, M.D., Department of Radiology, Namwon Medical Center, # 171-2, Dongchung-Dong, Namwon City, Chonbuk, 590-010 Korea. Tel. 82-671-620-1120, Fax. 82-671-32-3337

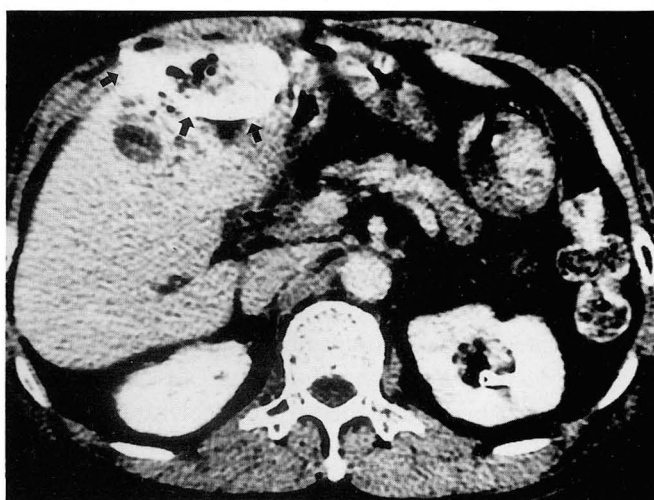
and systemic antibiotic therapy was begun soon after this was confirmed. By means of single stage, ultrasound-guided trocar insertion, a 10.3 F all purpose drainage catheter (Boston Scientific Corp., Watertown, Mass, U.S.A) was placed in the abscess pocket, and to keep the catheter lumen clear, 10–15 cc saline was injected every 8 hours. Twenty cc of purulent material was aspirated through the tube; Gram staining, cytologic examination, pus culture, and hemoculture revealed the presence of *Klebsiella pneumoniae*. During the following two days, less than 10 cc of pus was drained and the patient remained febrile for 48 hours after catheter insertion.

Follow-up CT scans obtained two days after catheter placement showed a round, low attenuated abscess with some air bubbles, and no shrinkage of the cavity (Fig. 1B). A contrast study through the catheter (sinogram) revealed a complex collection with multiple septation and filling defects (not shown). Using a modified Sheldinger technique, another 8 F drainage

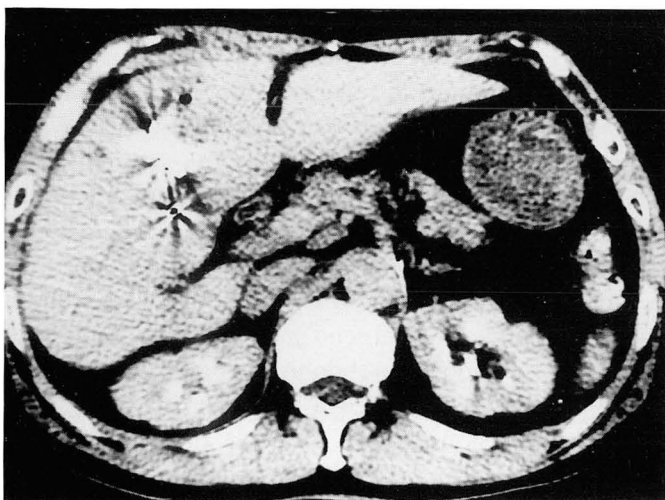catheter was inserted into the abscess pocket; during the procedure, a guide wire was used to disrupt septation or adhesion. With the catheter in place, we tried to evacuate all purulent material from the cavity, but only 10 cc, mixed with blood, was removed. We believed that this failure was due to multiloculation and the fibrinous and viscoous nature of the abscess fluid, and in an attempt to decrease the viscosity of purulent material and break any septations, intracavitary urokinase therapy was therefore instituted. 20,000 IU of urokinase (Green Cross, Seoul, Korea) dissolved in 10 ml normal saline was instilled via the tube, which was clamped for 30 min so that gravity drainage could occur. Upon withdrawal, about 50 to 70 ml of partially lysed foul-smelling, currant-jelly clot was obtained. Instillation was repeated every 8 hours and continued for three days. The evening after the first irrigation, symptomatic relief occurred; 12 hours after the procedure, the patient became afebrile, and remained so until discharge. Saline irrigation was continued for six



A



B



C

**Fig. 1.** 53-year-old man with a multiseptated liver abscess.

**A.** CT scan shows a large loculated mass with multiple septations in the right lobe of the liver.

**B.** Repeat scan after insertion of catheter shows persistent fluid with several air bubbles. Drainage catheter (arrow) is well demonstrated in the center of abscess cavity on CT after drainage.

**C.** Follow-up scans after urokinase instillation shows reduction in size of cavity with high density catheter in place.

days, and the cavity became smaller and eventually disappeared. No significant complications, including any form of hemorrhage, occurred and treatment with urokinase caused no significant changes in hematocrit, prothrombin time, partial thromboplastin time, and platelet count. Six days after urokinase instillation, repeat CT scanning showed complete obliteration of the cavity (Fig. 1C), and three days later, the catheters were removed.

## Discussion

Percutaneous catheter drainage of abscesses is a welcome advance in the treatment of a disease in which mortality was previously 60 % (8), and in recent years, a combination of CT and sonographically guided percutaneous drainage of hepatic abscesses has become a widely used, safe, and effective procedure (1, 2). Its benefits include the avoidance of general anesthesia, laparotomy, and prolonged postoperative hospitalization; cure rates, and those for morbidity and mortality, failure, and recurrences compare favorably with traditional surgery (7), and the success rate varies between 76 % and 89 % (1, 2). Failure is frequently due to multiloculation and phlegmon, fistula-associated abscesses, highly viscous content of the cavity, and improper catheter positioning (7). Complications include sepsis, contamination of the peritoneum, and empyema formation, and these occur at a rate of between 1.7 % and 7.3 %.

Although ultrasound guided needle aspiration has not gained wide popularity, and is considered by many to be suitable only for the diagnosis of hepatic abscesses, it has at some institutions been used in their treatment (8). Baek et al (8) reported that as initial treatment of a hepatic abscess, percutaneous needle aspiration combined with antibiotic therapy was safe, free from complications and effective. In their experience, its advantages over catheter drainage were that the patient suffered less discomfort, patient care was simpler, and costs were lower.

Although many hepatic abscesses are multiseptated, experience has shown that with the use of one drainage tube, many will clear completely (2). Nevertheless, multiseptation is the most difficult problem involved in the nonsurgical treatment of hepatic abscess, and is regarded as one of the significant causes of failure in percutaneous catheter drainage or needle aspiration (1, 8, 10). The most plausible explanation for the varied results with a septated abscess is that fibrin septa in such cavities may be complete or incomplete; when they are complete, drainage is poor, and when they

communicate and are incomplete, curative drainage can occur.

The rationale for using urokinase to improve the results of percutaneous drainage of abscesses and fluid collections, and its effectiveness and safety, has recently been documented in the literature (4-6, 9, 10). Park et al (9) showed that in vitro, the urokinase as compared with saline produced a considerable reduction in the viscosity of purulent material and its flow time through catheters of various sizes, and that the greatest benefit was achieved using smaller sizes of catheters. In addition, they stated that an extra theoretical benefit might be the lysis of fibrinous adhesions and loculations, which can also delay or impair drainage. The safety of urokinase in vivo was proved by Lahorra et al (10), who demonstrated that intracavitary urokinase produced an increased turnover of fibrin without any associated bleeding complication or changes in coagulation parameters. They stated, in addition, that urokinase also appeared to improve drainage of thick purulent material and to break any septations; in the above-mentioned study, all abscesses with loculations were successfully drained, as well as three infected hematomas in fungal or recurrent abscesses.

There has, however, been only one case report describing the use of urokinase for the treatment of a liver abscess; this successful procedure involved the administration of urokinase into the cavity of a multiloculated abscess, 8cm in diameter, in which previous percutaneous catheter drainage had failed (6). For one instillation, 10,000 IU of urokinase dissolved in 10ml normal saline was used; this solution was administered every 8 hours for 3 days. Lahorra et al (10) reported that their use of three different regimens to determine the effectiveness and safety of intracavitary urokinase used for the percutaneous drainage of intraabdominal abscesses. They found that among these regimens, 2500 IU of urokinase per cm of abscess diameter showed the best overall success rate. In our case, CT scanning revealed a multiloculated abscess with a diameter of 8 cm. According to the results of Lahorra et al, a total of 20,000 IU of urokinase solution was injected through the catheter into the abscess cavity during each instillation. In our case, intracavitary urokinase instillation successfully enhanced drainage and broke any septations, without the occurrence of hemorrhagic complications. We are not sure whether urokinase treatment is dose-dependent, but in our opinion, the dosage should vary according to the size of the abscess cavity. To determine the amount which most successfully improves the out-

come of percutaneous abscess drainage, a carefully controlled prospective study is required.

On the basis of this initial experience, we suggest that if drainage after catheter placement is inadequate, urokinase should be used.

## References

1. Gerzof SG, Johnson WC, Robbins AH, Nabseth DC. Expanded criteria for percutaneous abscess drainage. *Arch Surg* 1985;120:227-232
2. Johnson RD, Mueller PR, Ferrucci JT Jr, et al. Percutaneous drainage of pyogenic liver abscess. *AJR* 1985;144:463-467
3. Moulton JS, Moore PT, Mencini RA. Treatment of loculated pleural effusions with transcatheter intracavitary urokinase. *AJR* 1989;153:941-945
4. Lee KS, Im JG, Kim YH, Hwang SH, Bae WK, Lee BH. Treatment of thoracic multiloculated empyemas with intracavitary urokinase: a prospective study. *Radiology* 1991;179:771-775
5. Volgelzang RL, Tobin RS, Burstein S, Anschuetz SL, Marzano M, Kozlowski M. Transcatheter intracavitary fibrinolysis of infected extravascular hematoma. *AJR* 1987;148:378-380
6. Oh JH, Yoon Y. Case report of treatment of multiloculated liver abscess: administration of urokinase through drainage catheter. *Journal of the Korean Radiological Society* 1995;32:479-481
7. vanSonnenberg E, Mueller PR, Ferrucci JT. Percutaneous drainage of 250 abdominal abscesses and fluid collections. Part I: results, failures and complications. *Radiology* 1984;151:337-341
8. Baek SY, Lee MG, Cho KS, Lee SC, Sung KB, Auh YH. Therapeutic percutaneous aspiration of hepatic abscess: effectiveness in 25 patients. *AJR* 1993;160:799-802
9. Park JK, Kraus FC, Haaga JR. Fluid flow during percutaneous drainage procedures: an in vitro study of the effects of fluid viscosity, catheter size, and adjunctive urokinase. *AJR* 1993;160:165-169
10. Lohorra JM, Haaga JR, Stellato T, Flanigan T, Graham R. Safety of intracavitary urokinase with percutaneous abscess drainage. *AJR* 1993;160:171-174

대한방사선의학회지 1997;37:317-320

## 공동내 Urokinase주입에 의한 다방성 간농양 치료:1예 보고<sup>1</sup>

<sup>1</sup>남원의료원 진단방사선과

<sup>2</sup>남원의료원 내과

<sup>3</sup>전북대학교 의과대학 방사선과학교실

이정민 · 이미숙 · 이진희<sup>2</sup> · 임성희<sup>2</sup> · 김종수<sup>3</sup> · 한영민<sup>3</sup> · 최기철<sup>3</sup>

초음파, 방사선 투시기 또는 전산화단층촬영 등의 유도하에 시행되는 경피적 농양배액술은 간농양의 일차적인 치료방법으로 인정되고 있으나 격막이 있거나 다낭성인 농양의 경우는 성공률이 낮은 것으로 알려져 있다. 최근 다낭성의 복부농양이나 농흉의 치료에 Urokinase가 효과가 있다는 논문들이 보고되었다. 저자들이 알고 있는 바로는 간농양의 치료에 Urokinase를 사용한 보고는 단 1례의 증례보고만이 있을뿐이다. 저자들은 최근 53세 남자에서 발생한 통상적인 경피적 농양배액술에 효과가 없었던 다방성 간농양을 Urokinase를 사용하여 성공적으로 치료할 수 있었기에 이 경험을 보고한다. 다방성 간농양의 진단과 치료에 대한 평가를 위해 초음파와 CT를 이용하였다.