

MR Imaging of Cord Transection without Skeletal Injury : A Case Report¹

Seon-Kwan Juhng, M.D., See-Sung Choi, M.D., Byung-Suk Roh, M.D.
Chang-Guhn Kim, M.D., Jong-Jin Won, M.D.

Spinal cord transection in children may occur following severe trauma such as a motor vehicle accident, and often without evidence of underlying skeletal injury.

We report one case which showed cervical cord transection, where no evidence of underlying skeletal injury was seen on MR imaging, four weeks after trauma.

When a neurologic deficit is present despite normal routine plain radiographs, further MR imaging is warranted to exclude a cord transection, as demonstrated in our patient.

Index Words : Spinal cord, injuries
Spinal cord, MR

A child with spinal cord transection at the cervicothoracic junction following a motor vehicle accident and seen on magnetic resonance(MR) imaging is presented.

In contrast to adults, in whom cord injury in the absence of any fracture or dislocation is extremely rare, cord transection in children may occur in the absence of any skeletal injury.

Case Report

A 12-month-old girl was brought to the emergency room unconscious following a motor vehicle accident. Neurologic examination showed no abnormalities. The initial computed tomographic brain scan and chest and cervical spine radiographs were normal(Fig. 1A). She regained consciousness within eight hours. At that time her physician believed she had cerebral concussion and discharged her after close observation for 24 hours. Eight days after discharge she was referred to the department of urology of our hospital because of marked bladder distention and difficulties in urination ; a neurologic examination was carried out. Motor strength was normal in the upper extremities, with

intact intrinsic muscles. A sensory level was noted at T1, with flaccid lower extremities. Four weeks after the initial injury, the patient underwent MR imaging ; axial T1-weighted (TR/TE 600/15 msec), coronal T1-weighted (TR/TE 500/15 msec), sagittal T1-weighted (TR/TE 500/15 msec) and T2-weighted (TR/TE 6000/90 msec) spin-echo images were obtained. Axial and sagittal T1-weighted images after intravenous contrast injection were also obtained. Cord transection was inferred from the presence of a gap between spinal cord segments and a focal complete loss of cord signal at the C7-T1 level on all pulse sequences. Cervical alignment was normal. No extraneural soft tissue abnormalities nor abnormal contrast enhancement was noted(Fig. 1B and C). Neither follow-up neurologic or MR examination four months after the injury disclosed any change and five months after the injury the patient was readmitted to this hospital because of urinary tract infection secondary to a neurogenic bladder. At the time of this report she had been under continuing observation for six months.

Discussion

Spinal cord injury in children may occur without underlying vertebral fracture or malalignment. In 1982, Pang and Wilberger were the first to describe SCIWORCA, distinct syndrome of spinal cord injury

¹Department of Radiology, Wonkwang University School of Medicine
Received November 4, 1997 ; Accepted February 4, 1997
Address reprint requests to : Seon-Kwan Juhng, M.D., Department of Diagnostic Radiology, Wonkwang University School of Medicine, # 344-2 Shinyong-dong, Iksan-city, Chonbuk, 570-180 Korea
Tel. 82-653-50-1514 Fax. 82-653-51-4749

without radiographic abnormality (2). By definition, children with this syndrome suffer a traumatic myelopathy without identifiable fractures or subluxation on plain spine radiography, tomography, or computed tomography. This entity has been recognized increasingly since the mid-1980s. It has been postulated that the cord injury occurs when excessively elastic ligaments and other biomechanical features of the immature spine allow transient intervertebral displacements that result in cord compression or distraction(2). The inherent instability of the pediatric spine is maximal in infancy and decreases as the child reaches the second decade of life. A cadaver study of the neonatal spine revealed that elastic spinal column could be stretched 5cm without structural disruption, whereas the spinal cord, devoid of elastic elements, could stretch only 6.25mm before rupturing(3).

Total discontinuity of the spinal cord, cord transection, is at one end of the spectrum of spinal cord injury without fracture or malalignment (4), though following trauma is uncommon. In a study of 62 patients with spinal cord injuries who underwent MR, cord transection was seen in seven. In all cases the transection was accompanied by severe fracture/dislocations at the level of the cord transection(5). In children, however, cord transection may occur without skeletal injury, because immature spines are inherently more mal-

leable to deforming forces(1, 2, 4). The prevalent site of cord transection is the lower cervical and upper thoracic area; this is related to the relative resistance to stretching of the cervical enlargement and the greater vulnerability of the attenuated thoracic cord(6).

An increase in the number of motor vehicle accidents has resulted in a progressive annual increase in the number of spinal column and cord injuries, and an awareness of cord avulsion following such accidents is needed. The demonstration of cord transection in the acutely injured patient is important, and has both prognostic and therapeutic implications. Neurologic recovery is unlikely following cord transection, thus alleviating the need for exploratory surgery(1).

MR is a valuable imaging method for evaluating spinal cord injury(5). It allows us to directly and noninvasively visualize the traumatized spinal cord, and also to detect associated extraneural injuries(4, 5). In addition, it offers accurate prognostic information (4). Grabb PA and Pang D reported the MR imaging findings of seven children with SCIWORA(4). As extraneural soft tissue injuries, they found disruption of anterior and posterior longitudinal ligaments and disk herniations in three cases. As neural injuries, five patterns of cord findings on MR imaging were described: complete disruption of the cord; major cord hemorrhage; minor cord hemorrhage; edema only; no abnormality.

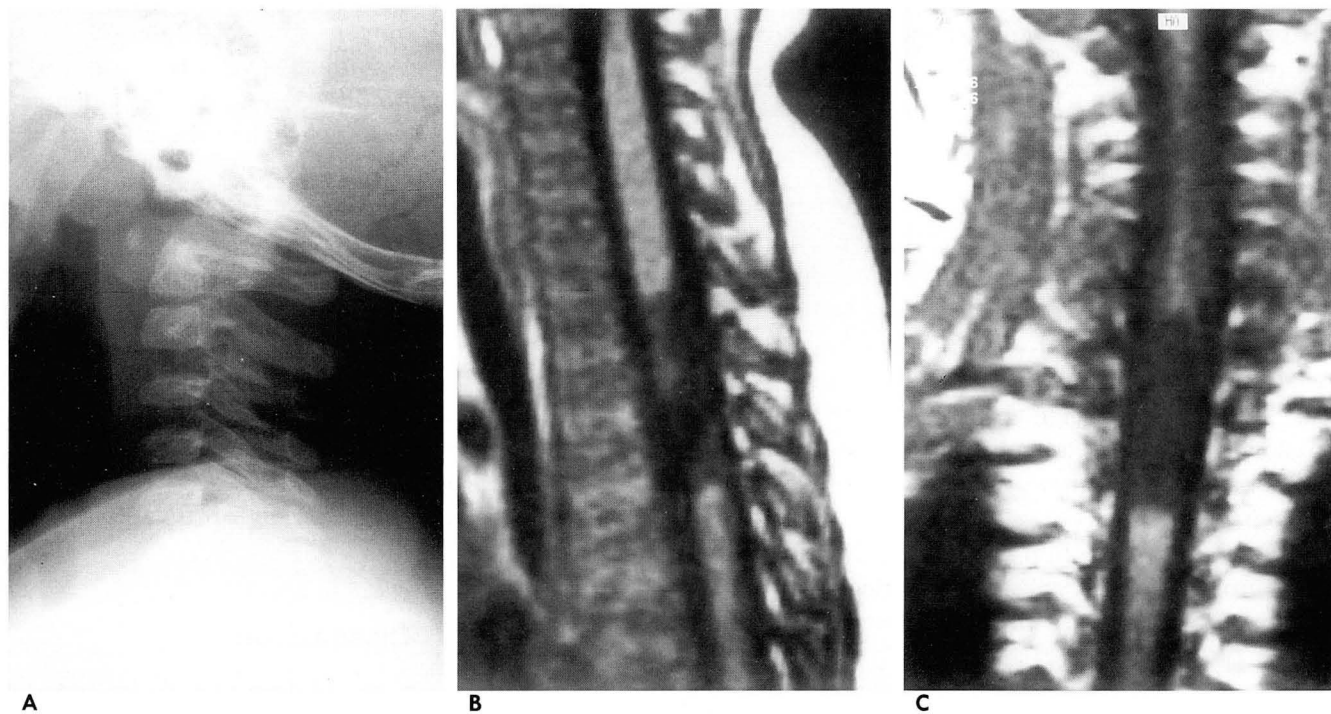


Fig. 1. A. Lateral radiograph of the cervical spine shows no abnormalities. B and C. Sagittal and coronal T1-weighted images (TR/TE = 500/15 msec) show loss of cord continuity, which is consistent with cord transection at the C7-T1 level with normal vertebral and soft tissue alignment.

Cord hemorrhage and edema are characterized on MR imaging by an altered cord signal, whereas cord transection is revealed by actual discontinuity of the cord signal and is best seen on sagittal T1-weighted images (1, 4-6). The unmistakable appearance of cord disruption on MR imaging reliably predicts a complete and permanent lesion. It also provides graphic verification of the previously made assertion that in pediatric SCIWORA, anatomical transection of the cord can in fact occur without fracture or frank rupture of the ligaments in the spinal column(4). Our patient illustrates both these points well.

It seems ironic to describe the imaging changes demonstrated by MR and still use the term SCIWORA. This term appears to be no longer valid, since the use of MR reveals significant pathologic change in patients who have no detectable fracture or dislocation. Because MR has become the preferred method of imaging the traumatized spinal cord, it is reasonable to anticipate

that further refinements in imaging will increase our ability to predict neurological outcome and recovery (4).

References

1. Mendelsohn DB, Zollars L, Weatherall PT, Girson M. MR of cord transection. *J Comput Assist Tomogr* 1990;14:909-911
2. Pang D, Wilberger JE, Jr. Spinal cord injury without radiographic abnormalities in children. *J Neurosurg* 1982;57:114-129
3. Leventhal HR. Birth injuries of the spinal cord. *J Pediatr* 1960;56:447-453
4. Grabb PA, Pang D. Magnetic resonance imaging in the evaluation of spinal cord injury without radiographic abnormality in children. *Neurosurgery* 1994;35:406-415
5. Kalfas I, Wilberger J, Goldberg A, Prostko ER. Magnetic resonance imaging in acute spinal cord trauma. *Neurosurgery* 1988;23:295-299
6. Mathis JM, Wilson JT, Barnard JW, Zelenik ME. MR imaging of spinal cord avulsion. *AJNR* 1988;9:1232-1233

대한방사선의학회지 1997;36:711-713

골손상이 동반되지않은 척수 횡절단의 자기공명영상:1예 보고¹

¹원광대학교 의과대학 방사선과학교실

정선관 · 최시성 · 노병석 · 김창근 · 원종진

소아에서는 자동차 사고같은 심한 외상후에 골손상없이 척수가 횡절단될수 있다. 저자들은 척추의 골절이나 탈골손상의 동반없이 사고후 4주에 시행한 자기공명영상에서 척수횡절단으로 진단된 1예를 보고한다. 단순촬영사진에서 정상이나 신경학적 이상이 지속될 때 척수손상의 유무를 확인하기 위하여 자기공명영상검사가 필요하다.

국제 학술대회 일정표 [II]

■ 78th Deutscher Roentgenkongress (1997/05/07-10)

venue: Wiesbaden, Germany.
contact: Beate v. Waldthausen, Deutsche Roentgenges. e. V.,
Postfach 1336, D-61283 Bad Homburg, Germany.
(tel: 49-6172-488585; fax: 49-6172-488587)

■ Annual Meeting Society for Pediatric Radiology (1997/05/13-18)

venue: St. Louis, MO, USA.
contact: Ms. Jennifer Boylan, Ex. Secr. SPR,
2021 Spring Rod, Ste 600, Oak Brook, IL 60521,
USA. (tel: 1-708-5712197; fax: 1-708-5717837)

■ The Conference on Thoracic Radiology and Radiology of the Breast (1997/05/14-15)

venue: Ivano-Frankivsk, Ukraine.
contact: Dr. V. T. Djomin,
Lomonosova atr. 33/43, Kiev, Ukraine 252022.
(tel: 380-44-2667578; fax: 380-44-2660108)

■ 35th Annual Meeting of the American Society of Neuroradiology (1997/05/16-22)

venue: Metro Toronto Conv. Ctr. Toronto, Canada.
contact: Tim Moses or, Lora Tannehill, ASNR,
2210 Midwest Road, Ste 207, Oak Brook, IL 60521,
USA. (tel: 1-708-5740220; fax: 1-708-5740661)

■ Annual Congress British Institute of Radiology with Med-Ex-Ray Exhibition (1997/05/19-21)

venue: Int. Convention Centre Birmingham, United Kingdom.
contact: Miss S. E. Nickson, Bir, 36 Portland Place,
London Win 4AT, United Kingdom.
(tel: 44-171-4367807; fax: 44-171-2553209)

■ 84th Congress & Annual Meeting of the Swiss Society for Medical Radiology (1997/05/22-24)

venue: Basel, Switzerland.
contact: Prof. W. Steinbrich, Kantonsspital Basel,
Petersgraben 4, Ch-4031 Basel, Switzerland.
(tel: 41-61-2654385; fax: 41-61-2655351)

■ 34th Annual congress European Society of Padiatric Radiology (1997/05/26-30)

venue: Lugano, Switzerland.
contact: Prof. F. Brunelle, Hop. des Enfants Malades,
149 Rue de Sevres, F-75730 Paris Cedex 15, France.
(tel: 33-1-44495173; fax: 33-1-44495170)

■ European Course in Neuroradiology-Skull Base (1997/05/31-04)

venue: Leuven, Belgium.
contact: Prof. G. Wilms, UZ Gasthuisberg,
Herestraat 49, B-3000 Leuven, Belgium.
(tel: 32-16-343771; fax: 32-16-343769)

■ Sandwichcursus (subject to be defined) (1997/06/03-04)

venue: De Jaarbeurs Utrecht, The Netherlands.
contact: Mrs. F.E. Blommendaal, NVvRd,
P.O. Box 8171, 3503 RD Utrecht, The Netherlands.
(tel: 31-30-2474294; fax: 31-30-2474439)

■ International Congress of Radiation Oncology 1997 (ICRO '97) (1997/06/04-07)

venue: Beijing, China.
contact: ISRO Office, Mrs. M. Stevens, UH Gasthuisberg,
Radiothe., Herestraat 49, B-3000 Leuven, Belgium.
(tel: 32-16-347685; fax: 32-16-347681)

■ Sandwichcursus (subject to be defined) (1997/06/05-06)

venue: De Jaarbeurs Utrecht, The Netherlands.
contact: Mrs. F.E. Blommendaal, NVvRd,
P.O. Box 8171, 3503 RD Utrecht, The Netherlands.
(tel: 31-30-2474294; fax: 31-30-2474439)

■ 5th Annual Congress European Society of Thoracic Imaging (1997/06/06-08)

venue: Conrad Hotel Brussels, Belgium.
contact: Prof. R.F. Dondelinger, Centre Hospitalo-Univ.,
Domaine de Sart Tilman-B35, 4000 Liege 1, Belgium.
(tel: 32-41-667259; fax: 32-41-667224)

■ Sandwichcursus Uroradiology (1997/06/13-14)

venue: De Jaarbeurs Utrecht, The Netherlands.
contact: Mrs. F.E. Blommendaal, NVvRd,
P.O. Box 8171, 3503 RD Utrecht, The Netherlands.
(tel: 31-30-2474294; fax: 31-30-2474439)

■ 60th Annual Scientific Meeting of the Canadian Association of Radiologists (1997/06/15-20)

venue: Westin Hotel Otawwa, Ontario, Canada.
contact: Suzanne Charette, Ex. Dir., Canadian Ass. of Radiol.,
510-5101 Buchan Street, Montreal QC H4P 2R9,
Canada. (tel: 1-514-7383111; fax: 1-514-7385199)

■ International Stent Congress (1997/06/19-22)

venue: Zoo Gesellschaft Haus Frankfurt, Germany.
contact: Dr. D. Liermann, Hosp. J.W. Goethe Univ.,
Hs23A, Theodor-Stern-Kai 7, D-60590 Frankfurt am
Main, Germany.
(tel: 49-69-63017277; fax: 49-69-63017259)

■ Int. Conf. European Society of Gastro-Intestinal & Abdominal Radiology (1997/06/25-28)

venue: Academic Medical Centre Amsterdam,
The Netherlands.
contact: Dr. J.W.A.J. Reeders, AMC,
Meibergdreef 9, 1105 Az Amsterdam, The Netherlands.
(tel: 31-20-5669111; fax: 31-20-5664440)

제공 : 대한방사선의학회 국제협력위원회