

Gastritis Caused by Ingestion of Eggs of Puffer Fish¹ : A Case Report

Dong Ho Lee, M.D., Young Tae Ko, M.D.

Tetrodotoxin is a neurotoxin, so gastrointestinal symptoms are very rare; these described in the literature are merely nausea and vomiting. Severe complications in the gastrointestinal tract caused by tetrodotoxin have not been radiologically reported. US and CT show thickening of the gastric wall and contraction of the lumen, and upper gastrointestinal series show shortening, lobulation and irregularity of the lesser and greater curvature of the body and antrum similar to the findings of corrosive gastritis.

Index Words : Gastritis
Stomach, US
Stomach, CT
Barium

Tetrodotoxin is a neurotoxin usually concentrated in the eggs of puffer fish; their accidental ingestion results in neurologic symptoms such as paresthesia and may lead to death when the amount of toxin is sufficient (1-4).

In the literature, there are a few descriptions of gastrointestinal symptoms after poisoning by tetrodotoxin (2, 3), but there has been no report concerning the radiological findings.

Several authors have attempted experimental studies concerning gastric mucosal damage by arterial infusion of tetrodotoxin and have documented the injury on gastric mucosa (5, 6); these were not, however, clinical studies.

We encountered a case of gastritis caused by ingestion of the eggs of puffer fish, and report this unusual case.

CASE REPORT

A 26-year-old man presented with vomiting and abdominal pain, symptoms which - together with nausea - he had shown since immediately after the accidental ingestion of puffer fish eggs one month earlier. Four of

six persons attending that gathering had suffered from similar acute gastrointestinal symptoms and had been admitted to another hospital, where for ten days they underwent conservative treatment for toxic symptoms. After discharge, this patient persistently complained for about two weeks of continuing abdominal pain and nausea, and was then admitted to our hospital, but the other patients recovered uneventfully.

On admission, sonography showed a distended stomach containing retained food, circumferential wall thickening, and contraction of the gastric antrum, suggesting gastric outlet obstruction (Fig. 1a). Gastroscopic findings suggested corrosive injury at the gastric mucosa and the result of gastroscopic biopsy was chronic ulcer. Abdominal CT showed diffuse wall thickening and contraction of the gastric body and antrum, and visible small perigastric lymph nodes (Fig. 1b). Examination of the upper gastrointestinal tract showed shortening of the lesser curvature of the stomach, scalloping and irregularity of the gastric body, marked narrowing of the antrum, and a deformed duodenal bulb (Fig. 1c). Staining of sputum for acid-fast bacilli was negative and a serologic test for syphilis was non-reactive. The patient was supportively cared for but the symptoms were not relieved and vomiting persisted.

He underwent subtotal gastrectomy and gastrojejunostomy. On surgery, the stomach showed diffuse contraction, especially at the lesser curvature of the body and antrum, and there were multiple diffuse superficial ulcerations. The wall of the antrum was

¹Department of Diagnostic Radiology Kyung Hee University Hospital

Received June 27, 1996; Accepted July 23, 1996

Address reprint requests to: Dong Ho Lee, M.D., Department of Diagnostic Radiology Kyung Hee University Hospital

1 Hoeki-dong, Dongdaemun-ku Seoul 130-702, Korea

Tel 82-2-958-8615 Fax 82-2-968-0787

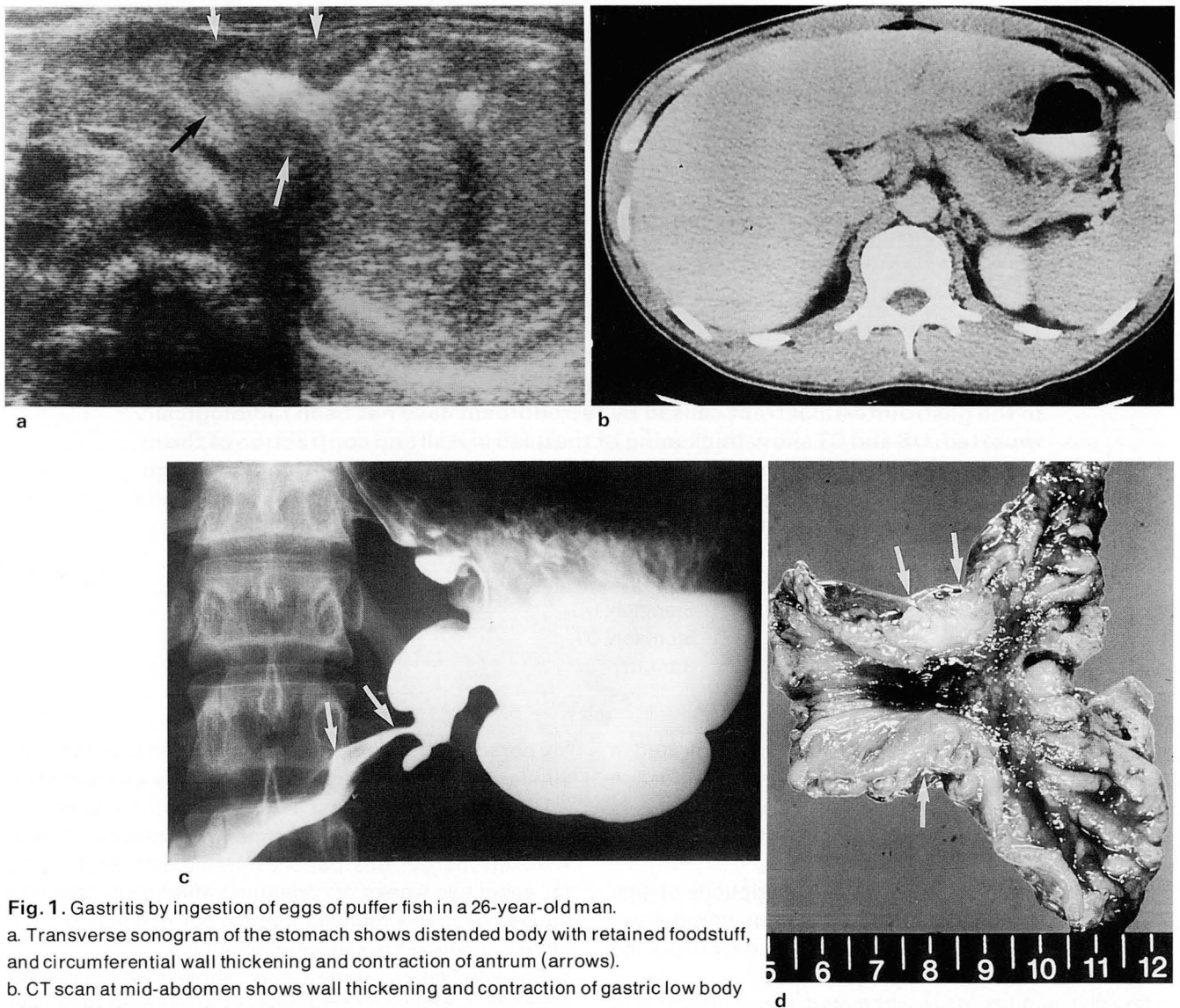


Fig. 1. Gastritis by ingestion of eggs of puffer fish in a 26-year-old man.

a. Transverse sonogram of the stomach shows distended body with retained foodstuff, and circumferential wall thickening and contraction of antrum (arrows).

b. CT scan at mid-abdomen shows wall thickening and contraction of gastric low body with small left paraaortic lymph nodes.

c. Upper gastrointestinal series show shortening, lobulation and irregularity of lesser curvature of high body and greater curvature of low body. The antrum reveals markedly narrowed lumen (arrows).

d. Pathologic specimen shows multiple mucosal ulceration with marked wall contraction. The submucosal and muscular layers of antrum are markedly thickened (arrows).

severely thickened and the pylorus was nearly obstructed. Pathologic examination of the resected specimen showed diffuse variegated mucosal ulceration with marked wall contraction; the submucosal and muscular layers were hypertrophied (Fig. 1d). Microscopic examination revealed acute ulcer with necrosis, infiltration of acute and chronic inflammatory cells, and diffuse infiltration of histiocytes with hemosiderin-laden macrophages. There was submucosal fibrosis and muscular thickening, and diagnosis based on a pathologic specimen was acute and chronic ulcers. The patient was discharged one week later and remained in good health.

DISCUSSION

Tetrodotoxin is a nonprotein, heat-stable neurotoxin, concentrated in the ovaries, kidneys, intestines and eggs of the puffer fish (1). This toxin possesses a local anesthetic property that disrupts sodium conductance by blocking the fast sodium channel during cell depolarization (2). The fish muscle during the nonreproductive season is nontoxic and in Oriental countries is considered a delicacy. Accidental ingestion of the eggs or intestines of the puffer fish produces neurologic symptoms. The signs and symptoms of tetro-

dotoxin intoxication begin with paresthesia and vomiting (2, 3), and as ascending paralysis develops, respiratory depression and cardiac dysrhythmia follow, and muscle twitching and convulsion may occur. In serious poisoning, hypotension, bradycardia, depressed corneal reflex and dilated pupil may be seen (2, 4). Mortality has been reported to be as high as 60% (2).

Tetrodotoxin is a neurotoxin, so gastrointestinal symptoms are very rare; those described in the literature are merely nausea and vomiting (2, 3). Severe complications in the gastrointestinal tract caused by tetrodotoxin have not been reported. In our case, gastritis was most likely induced by tetrodotoxin; before intoxication the patient showed no symptoms of an ulcer and gastrointestinal symptoms developed just after intoxication, as in the case of the others attending the gathering. On upper gastrointestinal examination and endoscopy, the findings were typical of corrosive gastritis. Except for eating eggs of the puffer fish, there were no other induced factors leading to gastritis. The pathologic findings were different from the usual pattern of gastric ulcer: in this case, the submucosa and muscle layers of the gastric wall were atypically hypertrophied and there was fibrosis; these findings are not usual in cases of gastric ulcer. The authors therefore concluded that this case was the first radiologically reported case of gastritis caused by the ingestion of eggs of the puffer fish.

Some authors have reported investigations of gastric mucosal damage caused by arterial infusion of tetrodotoxin (5, 6). Holzer et al. (5) explained the mechanism of gastric mucosal damage by tetrodotoxin. Disruption of the gastric mucosal barrier is quickly followed by an increase in gastric mucosal blood flow, which is thought to be a defense reaction to prevent further injury but is blocked by local arterial infusion of tetrodotoxin to the stomach. Inhibition of blood flow is

associated with exaggeration of gross and histological injury to the mucosa, and this is permanently damaged. Esplugues et al. (6) reported the role of the platelet-activating factor in the action of tetrodotoxin; the administration of this alone does not induce any detectable mucosal damage, indicating that inactivation of the mucosal neuronal mechanism does not directly disrupt the mucosa. Local intra-arterial infusion of tetrodotoxin only augments the mucosal damage induced by the platelet activating factor.

In our case, gastric mucosal damage was induced not by intravascular injection of tetrodotoxin but by eating puffer fish eggs containing tetrodotoxin. Gastric mucosal damage is therefore rather unlikely and we believe that this case of gastritis caused by ingesting the eggs of the puffer fish is very unusual.

REFERENCES

1. Mosher HS, Fuhrman FA, Buchwald HD, et al. Tarichatoxin-tetrodotoxin: a potent neurotoxin. *Science* **1964**; 144:1100-1110
2. Ellenhorn MJ, Barceloux D. *Food borne toxins*. In Ellenhorn MJ, Barceloux D, eds. *Medical toxicology: diagnosis and treatment of human poisoning*. New York: Elsevier Science Publishing Company, Inc, **1988**; 1171-1207
3. Arena JM, Drew RH. *Poisonous plants, reptiles, arthropods, insects and fish*. In Arena JM, Drew RH, eds. *Poisoning: toxicology, symptoms, treatments*. Illinois: Charles C Thomas Publisher, **1986**; 762-775
4. Sims JK, Ostman DC. Puffer fish poisoning: emergency diagnosis and management of mild human tetrodotoxigenesis. *Ann Emerg Med* **1986**; 15:1094-1098
5. Holzer P, Livingston EH, Guth PH. Sensory neurons signal for an increase in rat gastric mucosal blood flow in the face of pending acid injury. *Gastroenterol* **1991**; 101:416-423
6. Esplugues JV, Whittle BJR, Moncada S. Local opioid-sensitive afferent sensory neurones in the modulation of gastric damage induced by Paf. *Br J Pharmacol* **1989**; 97:579-585

대한방사선의학회지 1996; 35(3): 381~383

복어알에 의하여 유발된 위염¹

¹ 경희대학교 의과대학 진단방사선과학교실

이 동 호 · 고 영 태

Tetrodotoxin은 주로 신경계에 작용하는 독소이므로 복어알 섭취에 의한 증상은 대부분 신경마비이며, 위장관 이상에 관한 증상은 극히 드물고 다만 오심, 구토등이 동반될 수 있다. Tetrodotoxin에 의한 위장관의 심한 병변은 아직 방사선과학 문헌에 보고된 바가 없다. 방사선학적 소견으로는 초음파 및 CT검사상 위벽비후와 위내강의 수축을 보이고, 상부위장조영술상 위소만 및 대만의 단축, 분엽상 및 불규칙한 변연과 함께 위내강의 협착을 보여 부식성 위염때와 비슷한 양상으로 나타났다.

1997년도 서울대학교병원 진단방사선과 연수강좌 안내

날 짜	내 용	장 소	담당교수
3월 9일	Uroradiology	서울대학교병원 임상 제1강의실	김 승 협
4월 13일	Hepatobiliary Radiology	서울대학교병원 임상 제1강의실	한 준 구
5월 11일	Musculoskeletal Radiology	서울대학교병원 임상 제1강의실	강 홍 식
6월 15일	Chest Imaging	서울대학교병원 임상 제1강의실	임 정 기
8월 31일	Upper Abdominal Ultrasound	서울대학교병원 임상 제1강의실	최 병 인
10월 12일	International Symposium : Cardiovascular and Interventional Radiology	서울대학교병원 임상 제1강의실	박 재 형
11월 16일	Head and Neck Imaging	서울대학교병원 임상 제1강의실	한 문 희