

Air in Vagina : Significance in the Staging of Uterine Cervical Carcinoma¹

Seung Hyup Kim, M.D., Byung Ihn Choi, M.D., Soon Beom Kang, M.D.²,
Hyo Pyo Lee, M.D.², Man Chung Han, M.D.

PURPOSE: To evaluate the significance of vaginal air seen on CT scan in preoperative staging of uterine cervical carcinoma

MATERIALS AND METHODS: A comparison was made between CT findings of vaginal air and true vaginal involvement status in 85 patients with uterine cervical carcinoma. CT findings were analyzed in terms of the presence or absence of vaginal air, number of CT slices in which vaginal air was seen, shape of vaginal air, and relation of vaginal air to cervical mass.

RESULTS: Vaginal air was present in 35 patients and was absent in 50. Although the mere presence of vaginal air or multiplicity of CT slices showing vaginal air did not signify the presence of vaginal involvement, vaginal air with irregular margin or vaginal air adjacent to uterine cervical mass was suggestive of vaginal involvement.

CONCLUSION: These observation of vaginal air in interpreting CT may be helpful in the preoperative staging of uterine cervical carcinoma.

Index Words : Uterine neoplasms

Uterine neoplasms, CT

Uterine neoplasms, staging

Vagina, abnormalities

Vagina, CT

INTRODUCTION

Although magnetic resonance(MR) imaging has been proved to be superior to computed tomography(CT) in the evaluation of parametrial status(1-4), CT is still being used popularly for the preoperative staging of uterine cervical carcinoma. CT scan has several limitations in the staging of uterine cervical carcinoma, one of which is its unreliability in detecting vaginal involvement(5). Therefore, it has been considered that stage IIA and stage IIIA tumors were best evaluated by clinical examination(5).

The purpose of this study was to evaluate the significance of vaginal air in the preoperative staging of uterine cervical carcinoma.

MATERIALS and METHODS

Eighty-five women with histologically confirmed uterine cervical carcinoma were examined with CT at Seoul National University Hospital, Seoul, Korea. The age of the patients ranged from 27 to 76 years(mean, 49 years).

CT scan was obtained on a GE 9800 scanner(GE Medical Systems, Milwaukee). Consecutive 10-mm-thick sections were obtained from the level of the iliac crest to the symphysis pubis. Each patient received an oral dose of 1200 mL of 2% diatrizoate meglumine (Gastrografin, Schering, Berlin, Germany) hour before scanning and an intravenous bolus injection of 120 mL of 66% ioxithalamate meglumine(Telebrix 30; Laboratoire Guerbet, Aulnay-sous-Bois, France) immediately prior to the start of the scanning. A vaginal tampon was not used.

CT images were evaluated in regard to the presence or absence of the vaginal air, the number of CT slices in

¹Department of Radiology, Seoul National University College of Medicine

²Department of OB & GY, Seoul National University College of Medicine

Received June 12, Accepted August 2, 1993

Address reprint request to: Seung Hyup Kim, MD., Department of Radiology, Seoul National University Hospital, 28 Yongon-Dong, Chongno-Gu, Seoul 110-744, Korea

Table 1. Shape of Vaginal Air and Vaginal Involvement in 35 Patients with Uterine Cervical Carcinoma

Type	Shape of Vaginal Air	No. of Patients	
		Total	With Vaginal Involvement
A	Small round bubbles	9	0
MA	Type-A air adjacent to mass	11	7
B	Asymmetric curvilinear	2	0
MB	Type-B air adjacent to mass	2	2
C	Symmetric linear or curvilinear	4	2
MC	Type-C air adjacent to mass	1	1
D	Irregular-margined	2	2
MD	Type-D air adjacent to mass	2	2
E	Air within mass	2	0
Total		35	16

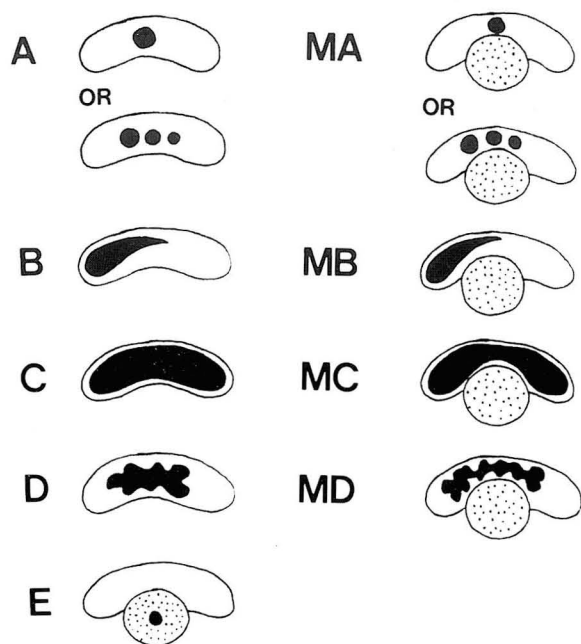


Fig. 1. Schematic drawing of types of vaginal air seen on CT in patients with uterine cervical carcinoma. a, Small round air bubbles (Fig. 2a,b). MA, Type-A air adjacent to cervical mass (Fig. 2c). b, Asymmetric curvilinear vaginal air (Fig. 2d). MB, Type-B air adjacent to cervical mass (Fig. 2e). c, Symmetric linear or curvilinear vaginal air (Fig. 2f). MC, Type-C air adjacent to cervical mass (Fig. 2g). d, Irregular margined vaginal air (Fig. 2h,i). MD, Type-D air adjacent to cervical mass (Fig. 2j). E, Air within cervical mass (Fig. 2k).

which vaginal air was seen, the contour of the vaginal air, and the relation of the vaginal air to the cervical masses. CT images were evaluated by one radiologist (Kim SH) who was blinded to the presence or absence of true vaginal involvement.

The true involvement of the vagina by uterine cervical carcinoma was determined by surgical-pathologic findings in 74 patients and by physical examination

findings in 11 patients in whom surgical exploration was not performed because of the advanced stage of the disease. Comparisons were made between CT findings of the vaginal air and the surgical-pathologic or physical-examination findings of the vagina.

RESULTS

Vaginal air was present on CT scan images in 35 patients (41%) and was absent in 50 (59%). Among 35 patients in whom vaginal air was present, vaginal involvement by uterine cervical carcinoma was present in 16 patients and was absent in 19. Among 50 patients in whom vaginal air was not seen on CT scan, true vaginal involvement was present in 14 and was absent in 36. If we regard the presence of vaginal air on CT scan as a sign of vaginal involvement, this CT finding have a sensitivity of 53%, a specificity of 65%, an accuracy of 61%, a positive predictive value of 46%, and a negative predictive value of 72% in an assessment of the vaginal involvement by uterine cervical carcinoma.

Vaginal air was present on only one CT slice in 17 patients (true involvement was present in eight and absent in nine), on two slice in 13 patients (true involvement was present in six and absent in seven), and on three slices in five patients (true involvement was present in two and absent in three). There was no definite correlation between the number of CT slices in which vaginal air was present and the true involvement of the vagina by the tumor.

The shape of the vaginal air was classified into nine types as follows (Fig. 1); A (single or multiple small round air bubbles, Fig. 2a,b), MA (type-A air adjacent to cervical mass, Fig. 2c), E (asymmetric curvilinear vaginal air, Fig. 2d), MB (type-B air adjacent to cervical mass, Fig. 2e), C (symmetric linear or curvilinear vaginal air collection, Fig. 2f), MC (type-C air adjacent to cervical mass, Fig. 2g), D (irregular-margined vaginal air, Fig. 2h,i), MD (type-D air adjacent to cervical mass, Fig. 2j), and E (air within cervical mass, Fig. 2k).

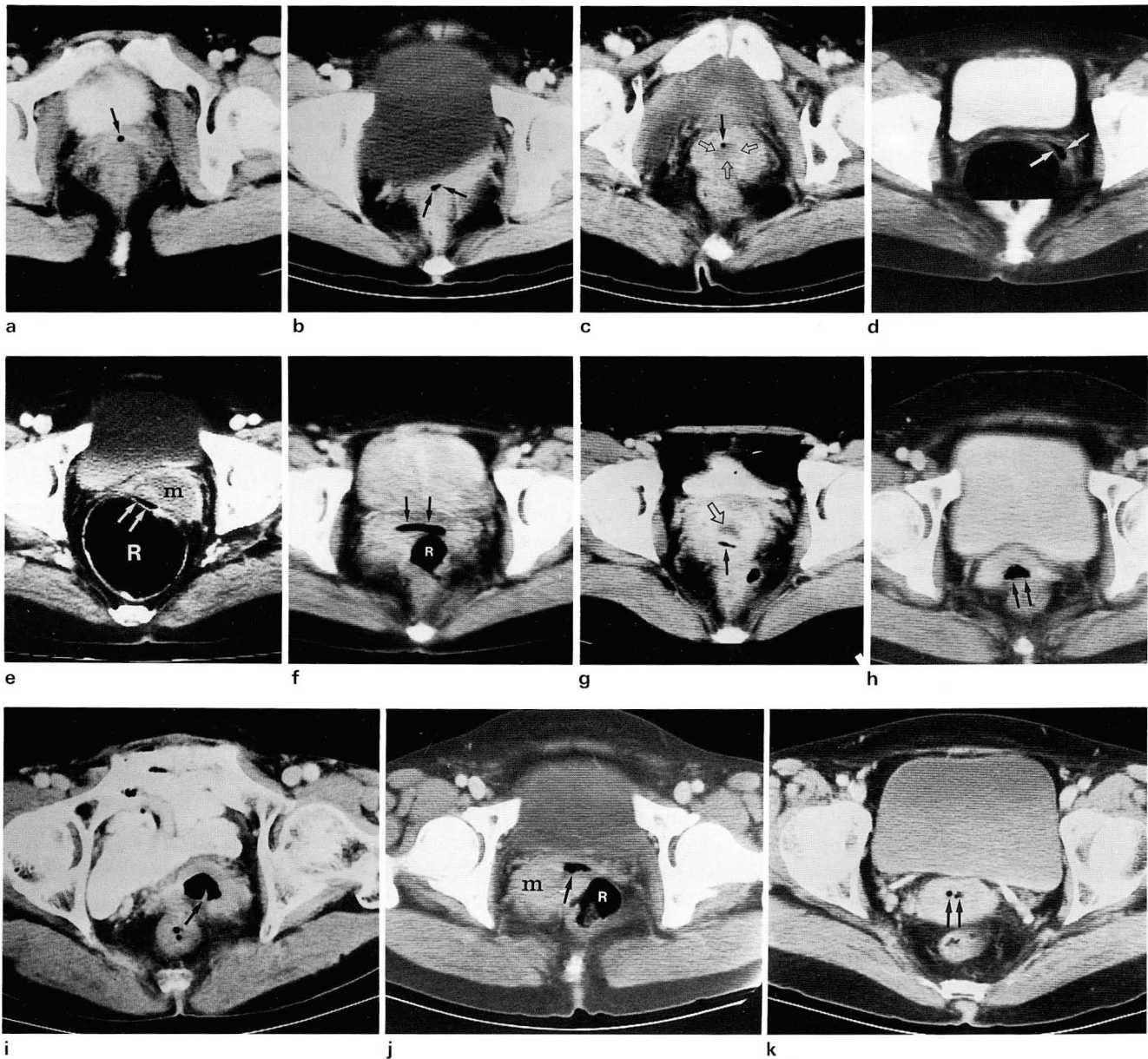


Fig. 2. Types of vaginal air seen on CT scans of pelvis in patients with uterine cervical carcinoma.

- a. Type-A; a small air bubble (arrow) in vagina in a patient without vaginal involvement.
- b. Type-A; two adjacent small air bubbles (arrows) in vagina in a patient without vaginal involvement.
- c. Type-MA; a small vaginal air bubble (arrow) adjacent to low-attenuation cervical mass (open arrows) in a patient without vaginal involvement.
- d. Type-B; asymmetric curvilinear vaginal air (arrows) in a patient without vaginal involvement.
- e. Type-MB; asymmetric curvilinear vaginal air (arrows) posterior to cervical mass (m). Left vaginal fornix was involved in this patient. R (rectum).
- f. Type-C; symmetric linear air (arrows) filling entire lumen of vagina in a patient without vaginal involvement. R (rectum).
- g. Type-MC; linear vaginal air (arrow) posterior to low-attenuation cervical mass (open arrow) in a patient with vaginal involvement.
- h. Type-D; irregular-margined vaginal air (arrows) in a patient with vaginal involvement.
- i. Type-D; irregular-margined vaginal air (arrow) in a patient with vaginal involvement.
- j. Type-MD; irregular-margined vaginal air (arrow) adjacent to cervical mass (m). In this patient, right vaginal fornix was involved by tumor. R (rectum).
- k. Type-E; two small air bubbles within cervical mass in a patient without vaginal involvement.

The results (presence or absence of the vaginal involvement) according to this classification of the vaginal air are summarized in Table 1. Vaginal involvement was absent in all 13 patients with type-A(n=9), type-B(n=2), and type-E(n=2). Vaginal involvement was present in all seven patients with type-MB(n=2), type-MC(n=1), type-D(n=2), and type-MD(n=2). In type-MA and type-C patients, the results were not definite.

DISCUSSION

To improve diagnostic accuracy in staging and identification of lymph node metastasis of uterine cervical carcinoma, CT has been used with several limitations. One of the causes of significant staging errors that arise with use of CT was that CT could not detect vaginal involvement reliably(5). CT criteria for vaginal involvement in uterine cervical carcinoma have not been well developed(4,5) and it has been considered that stage IIA (upper two-thirds vaginal involvement) and stage IIIA (lower one-third vaginal involvement) tumors were best evaluated by the clinical examination(5). However, clinical staging of stage IIA or IIIA tumors is not always easy, and sometimes pelvic examination is inaccurate or impossible to evaluate vaginal involvement by the tumor(6,7).

Nokes et al. reported that a small amount of vaginal air on only one CT slice without distention of vagina was seen in 11% of normal female patients and they suggested that this is not unlikely as the vaginal cavity is continuous with the surrounding atmospheric pressure(8). They also reported that the distention of the vagina with air and visualization of air on more than one image were found only with enterovaginal fistula and in those patients studied with a tampon in place (8). Vaginal air on CT scan also has been reported in patients with vaginitis emphysematosa(9). Recently Hadar et al. reported that a large amount of vaginal air was seen in 27 out of 2800 (less than 1%) female abdomino-pelvic CT scans(10). They also reported that 23 out of 27 patients with vaginal air suffered from pelvic malignancy and 17 had a tumor infiltrating the vaginal wall. However, they did not describe the significance of the shape of the vaginal air with regard to vaginal involvement by the tumor.

In our study, vaginal air was seen on CT scan in 41% (35 out of 85 patients), a rate much higher than 11% reported by Nokes et al(8). Among 35 patients with vaginal air in our study, true vaginal involvement was present in only 16 patients. If we exclude these 16 patients in whom vaginal air was seen on CT scan and true vaginal involvement was present, the vaginal air was seen in 28% (19 out of 69 patients), still in a very high rate. This high frequency of vaginal air in our study might be related to the following reasons. First, air may be collected in vagina if an exophytic cervical

mass distended the vaginal canal without true vaginal involvement. Second, in case of true vaginal involvement, the elasticity of the wall of the vagina may be diminished and so the vagina does not completely collapse allowing air to be collected in the vaginal canal. Third, recent pelvic examination might also be a cause of high frequency of vaginal air on CT scan in our study. However, pelvic examination was not performed within 24 hours preceding CT scan in any patient in our study.

Some reported that the use of vaginal tampon facilitated the demonstration of the tumor extension into the vagina(11). Although we did not use a vaginal tampon in pelvic CT, the observation of vaginal air may be useful in the evaluation of the vaginal involvement in uterine cervical carcinoma.

In the present study, we did not perform a statistical analysis since the sample numbers of some types of vaginal air were too small. However, we may say that the mere presence of vaginal air was not a significant sign for the presence of true vaginal involvement, but the irregular contour of the collected air or vaginal air seen adjacent to the uterine cervical mass may be suggestive of vaginal involvement by uterine cervical carcinoma. Familiarity with this CT findings of the vaginal air may be of use in the preoperative CT staging of the uterine cervical carcinoma.

REFERENCES

1. Hricak H, Lacey CG, Sandles LG, Chang YCF, Winkler ML, Stern JL. Invasive cervical carcinoma: comparison of MR imaging and surgical findings. *Radiology* 1988; 166: 623-631
2. Lee JKT. The role of MR imaging in staging of cervical carcinoma. *Radiology* 1988; 166: 895-896
3. Togashi K, Nishimura K, Sagoh T, et al. Carcinoma of the cervix: staging with MR imaging. *Radiology* 1989; 171: 245-251
4. Kim, SH, Choi BI, Lee HP, et al. Uterine cervical carcinoma: comparison of CT and MR findings. *Radiology* 1990; 175: 45-51
5. Walsh JW, Goplerud DR. Prospective comparison between clinical and CT staging in primary cervical carcinoma. *AJR* 1981; 137: 997-1003
6. Togashi K, Nishimura K, Itoh K, et al. Uterine cervical cancer: assessment with high-field MR imaging. *Radiology* 1986; 160: 431-435
7. Waggenspack GA, Amparo EG, Hannigan EV. MR imaging of uterine cervical carcinoma. *JCAT* 1988; 12: 409-414
8. Nokes SR, Martinez CR, Arrington JA, Dauito R. Significance of vaginal air on computed tomography. *JCAT* 1986; 10: 997-999
9. Jaramillo D, Allan NK, Raval B. Computed tomography of vaginitis emphysematosa. *JCAT* 1986; 10: 521-523
10. Hadar H, Kornreich M, Heifetz M, Herskovitz P, Horev G. Air in vagina: indicator of intrapelvic pathology on CT. *Acta Radiol* 1991; 32: 170-173
11. Cohen WN, Seidelmann FE, Bryan PJ. Use of a tampon to enhance vaginal localization in computed tomography. *AJR* 1977; 128: 1064-1065

CT에 보이는 질내공기 : 자궁경부암의 병기결정에서의 중요성

김승협 · 최병인 · 강순범 · 이효표 · 한만청

서울대학교 의과대학 진단방사선과학교실

목 적: 자궁경부암의 수술전 병기결정을 위한 골반강 CT에서 질내에 보이는 공기의 의의를 알아보기 위하여

대상 및 방법: 자궁경부암의 환자 85명의 CT 소견을 분석하였다. 질내공기 유무, 질내공기가 있는 경우 공기가 보이는 영상면의 수, 질내공기의 모양, 그리고 질내공기와 자궁경부종괴와의 관계에 관하여 CT 영상을 분석하였고 암상소견과 수술 및 병리소견으로 확인된 질침범 유무와 비교하였다.

결 과: 85명 중 35명에서 질내공기가 있었고 50명에서는 질내공기가 없었다. 단순히 질내공기가 있다거나 여러 영상면에서 질내공기가 보인다는 점 들은 질침범을 시사하는 소견이 될 수 없었으나, 질내공기가 불규칙한 경계를 갖거나 자궁경부종괴에 인접한 질내공기는 질침범을 시사하는 소견이었다.

결 론: 이와같은 질내공기에 관한 관찰결과는 CT를 이용하여 자궁경부암의 수술 전 병기결정을 할때 도움이 되리라고 생각한다.

1994년도 국제 학술대회 일정표 [IV]

- 1994/05/23 - 25 **5th Int. Symposium on Interventional Radiology & New Vascular Imaging**
venue: Int. Conference Hall Kyoto, Japan.
contact: Morio Sato, M.D., Wakayama Medical College,
7-27 Wakayamashi, Wakayama, 640 Japan.
(tel: 81-734-268343; fax: 81-734-244699)
- 1994/05/29 - 02 **57th Annual Scientific Meeting of The Canadian Association of Radiologists**
venue: Toronto Harbor Castle Toronto, Ontario, Canada.
contact: Suzanne Charette Ex. Dir.,
5101 Buchan St., 5th Floor, Montreal, Queb. H4P 2R9, Canada.
(tel: 1-514-7383111; fax: 1-514-7385199) [RA0010]
- 1994/05/30 - 06 **31st. Meeting European Society of Paediatric Radiology**
venue: Brussels, Belgium.
Contact: Ms. Margaux, HELLO-TIMELEL S.A.,
Rue Dautzenberg 36-38, B-1050 Brussels, Belgium.
(tel: 32-2-6492055; fax: 32-2-6496126) [DD7965]
- 1994/06/05 - 08 **41st Annual Meeting Society of Nuclear Medicine**
venue: Orange County Conv. Ctre. Orlando, FL, USA.
contact: Dept. of Meeting Services, Soc. of Nuclear Medicine,
136 Madison Avenue, 8th fl, New York, NY 10016, USA.
(tel: 1-212-8890717; fax: 1-212-5450221)
- 1994/06/05 - 09 **Cirse '94 - Cardiovascular and Interventional Radiological Soc. of Europe**
venue: Aghia Pelaghia Crete, Greece.
contact: Mrs. B. Läubli, Ex. Dir. C.I.R.S.E.,
P.O. Bos 201, 8028 Zurich, Switzerland.
(tel: 41-1-2622404; fax: 41-1-2610578) [DD4697]
- 1994/06/12 - 14 **European Congress on Medical Radiology**
venue: Kongressent. Folkets Hus Oslo, Norway.
contact: Christine B. Askim, Help Arrangement-Service,
P.O. Box 597, 1301 Sandvika, Norway.
(tel: 47-2-519012; fax: 47-2-540058)
- 1994/06/15 - 19 **27th Annual Conf. and Postgraduate Course in Head and Neck Radiology**
venue: Washington D.C., USA.
contact: Ms. Beth A. Filip, Am. Soc. Head & Neck Radiol,
2210 Midwest Road, Oak Brook, IL 60521, USA.
(tel: 1-708-5740660; fax: 1-708-5740661)

제공 : 대한 방사선의학회 국제협력위원회