

Track Seeding in a Breast Cancer Patient after a 14-Gauge Core Needle Biopsy: A Case Report¹

Su Wan Kim, M.D., Eun Sook Ko, M.D., Byung Hee Lee, M.D., Ki Hwan Kim, M.D.

US-guided large-gauge core needle biopsy has replaced fine-needle aspiration and excisional biopsy for sampling suspicious breast lesions. The core needle biopsy has many advantages: it is relatively simple, it can be done with local anesthesia, it enables accurate targeting under sonographic guidance and it leaves no scar. However, one rare disadvantage of this technique is the possible seeding of malignant cells along the needle track. We report here on a case of gross track seeding in a 76-year-old woman, and this was observed 70 days after performing a 14-gauge core needle biopsy.

Index words : Breast neoplasms

Biopsy

Needle

Neoplasm seeding

US-guided large-gauge core needle biopsy for palpable and nonpalpable breast lesions is a safe and effective alternative to fine-needle aspiration and needle-localized breast excisional biopsies (1, 2). It can reduce the need for a two-stage procedure and can improve the surgical and oncological outcomes (3). However, one disadvantage of this technique for sampling breast cancer is the possible seeding of malignant tumor cells along the needle track (4 - 6).

Many studies have examined track seeding after needle localization or biopsy, and they have reported microscopic seeding after procedures or recurrences at biopsy sites after definitive treatment (5 - 8). Yet to the best of our knowledge, gross track seeding after a 14-gauge core needle biopsy has never been reported for a breast cancer patient. We report here on a case of cancer cell seeding along the biopsy tract of mucinous carcinoma ob-

served 70 days after performing a 14-gauge core needle biopsy.

Case Report

A 76-year-old woman presented with a palpable mass in her right breast. Diagnostic mammography showed an approximately 2.6-cm, oval, circumscribed mass, with internal coarse calcification, in the subareolar area (Fig. 1A). Breast sonography revealed a 2.3-cm, irregular, hypoechoic mass in the same area (Fig. 1B). The radiological findings were prospectively assessed according to the American College of Radiology Breast Imaging Reporting and Data System (BI-RADS) (9) as BI-RADS category 4b (intermediate suspicion for malignancy). Therefore, a US-guided large-core needle biopsy was performed by an experienced breast radiologist with using a 14-gauge needle and an automated gun (Bard Urological, Covington, GA). The five firm whitish specimens obtained via needle biopsy revealed mucinous carcinoma. As the patient had other medical problems, including diabetes mellitus, uncontrolled hypertension

¹Department of Radiology, Korea Cancer Center Hospital
Received May 18, 2008 ; Accepted August 21, 2008
Address reprint requests to : Eun Sook Ko, M.D., Department of Radiology, Korea Cancer Center Hospital, 215-4 Gongneung-dong, Nowon-gu, Seoul 139-706, Korea
Tel. 82-2-970-2452 Fax. 82-2-970-2433 E-mail: esko@kcch.re.kr

and a 1.8-cm saccular aneurysm of the left middle cerebral artery, her physician suggested radiation therapy as an alternative to a curative operation. Unfortunately,

the palpable mass increased in size after radiation therapy. Approximately 70 days after the initial examination, mammography and sonography were repeated for sur-

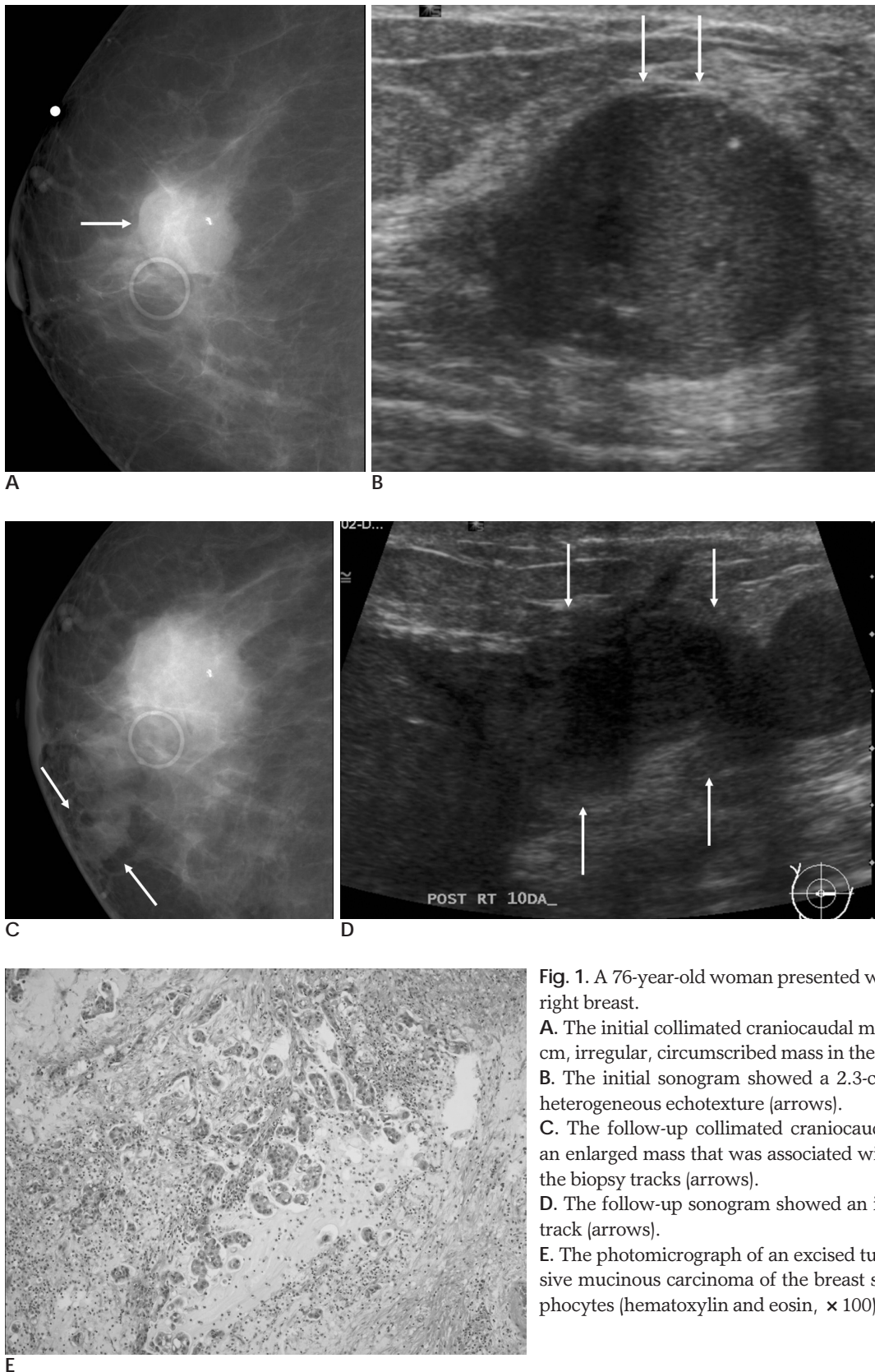


Fig. 1. A 76-year-old woman presented with a palpable mass in her right breast.

A. The initial collimated craniocaudal mammogram showed a 2.6-cm, irregular, circumscribed mass in the subareolar area (arrow).

B. The initial sonogram showed a 2.3-cm hypoechoic mass with heterogeneous echotexture (arrows).

C. The follow-up collimated craniocaudal mammogram showed an enlarged mass that was associated with tubular densities along the biopsy tracks (arrows).

D. The follow-up sonogram showed an irregular mass in a needle track (arrows).

E. The photomicrograph of an excised tubular lesion showed invasive mucinous carcinoma of the breast surrounded by many lymphocytes (hematoxylin and eosin, $\times 100$).

gical planning. The follow-up mammogram showed a 4.4-cm, irregular, ill-defined mass with newly developed tubular structures along the biopsy needle tracks (Fig. 1C), and the subsequent sonogram showed a markedly enlarged mass with two tubular masses extending to the puncture sites (Fig. 1D). Subsequently, the patient underwent a modified radical mastectomy. The pathological examination confirmed that the main mass and the lesions that were observed as tubular structures on mammography and sonography were all mucinous carcinoma (Fig. 1E).

Discussion

Displacement of tumor cells during performance of core needle biopsies for breast lesions has been demonstrated in several cases (4, 7, 8). However, the true incidence of tumor cell displacement after an automated core biopsy with using a 14-gauge needle is difficult to assess. The reported incidence varies, with some authors reporting a seeding rate of about 50% (8), which raises concerns regarding the survival of these displaced cells. Diaz et al. found that the incidence and amount of tumor cell displacement were inversely related to the interval between the core biopsy and the surgical excision (6), and they concluded that this suggests the tumor cells do not survive displacement. Conversely, Stoler et al., in a study of local breast cancer recurrence in relation to mammographically guided punctures, found that one of two patients with malignant needle track seeding developed local recurrence at 34 months postoperatively, and this implied that the displaced tumor cells were indeed viable (5). Several other studies that used similar methods have concluded that recurrence at biopsy sites provides evidence of track seeding (8, 10). However, it is difficult to distinguish between recurrence at a biopsy site after treatment and the local recurrence that's unrelated to the biopsy. Therefore, we believe that the previous reports of local recurrence at biopsy sites are somewhat questionable.

Excision of the needle tracks during breast surgery may prevent the local recurrence caused by malignant cell seeding. This is rarely a problem when performing mastectomy, although seeding might still involve the overlying skin flaps. The concern about needle track seeding is greater for breast conserving therapy because the needle tracks often extend beyond the area of the planned surgical excision. In these cases, radiotherapy may kill any displaced viable cancer cells. Thurfjell et

al. (7) found displaced tumor cells after fine needle aspiration and wire localized excision in three of 33 breast cancer patients who developed local recurrence, and none of the three had received radiotherapy.

Multiple factors can influence the occurrence of track seeding. The available data suggests that the risk of needle track seeding increases with the needle size (6). In addition, multiple-punctures appear to have an adverse effect on the incidence of needle track seeding (5). According to Diaz et al. (6), the risk of track seeding during biopsy is higher with using automated, manually guided, cutting needles than with using vacuum-assisted needles; although the difference was not statistically significant, it suggests there is a correlation between track seeding and the number of needle passes. The time interval between biopsy and surgery is also important. In that same study, Diaz et al. found that 66 (58%) of 114 patients with tumor displacement had undergone surgical excision within 2 weeks of the core biopsy, whereas only 11 patients (10%) with tumor displacement underwent surgical excision at more than 4 weeks. The decreasing incidence of tumor displacement with time after core biopsy strongly suggests that the displaced tumor cells do not survive after displacement, but they may instead be eliminated by the inflammatory reactions induced by the biopsy procedure. In our case, the interval between biopsy and surgery was 70 days, which is relatively long.

However, our report has the following limitations. First, we could not obtain coronal sections of the gross tumor, so it was hard to correlate the pathologic findings with image findings. Second, instead of spreading the tumor cells during the biopsy, preexisting microscopic malignant foci could have grown along the biopsy track, so pathologic confirmation of tumor seeding along the biopsy track is ideal, but this is impossible in actual clinical practice. We believe that mucin spillage along the biopsy track during the procedure may have caused the rapid track seeding.

In summary, we present here a case of gross malignant cell seeding along the biopsy tracks at 70 days after performance of a large-core needle biopsy, and this provides positive evidence that the displaced cancer cell did indeed survive.

References

1. Berg WA, Krebs TL, Campassi C, Maqder LS, Sun CC. Evaluation of 14- and 11-gauge directional, vacuum-assisted biopsy probes

- and 14-gauge biopsy guns in a breast parenchymal model. *Radiology* 1997;205: 203-208
2. Seoudi H, Mortier J, Basile R, Curletti E. Stereotactic core needle biopsy of nonpalpable breast lesions: initial experience with a promising technique. *Arch Surg* 1998;133: 366-372
 3. Wazer DE, DiPetrillo T, Schmidt-Ullrich R, Weld L, Smith TJ, Marchant DJ, et al. Factors influencing cosmetic outcome and complication risk after conservative surgery and radiotherapy for early-stage breast carcinoma. *J Clin Oncol* 1992;10: 356-363
 4. Harter LP, Curtis JS, Ponto G, Craig PH. Malignant seeding of the needle track during stereotaxic core needle breast biopsy. *Radiology* 1992;185: 713-714
 5. Stoler A, Skinner J, Levine EA. A prospective study of seeding of the skin after core biopsy of the breast. *Am J Surg* 2000;180:104-107
 6. Diaz LK, Wiley EL, Venta LA. Are malignant cells displaced by large-gauge needle core biopsy of the breast? *AJR Am J Roentgenol* 1999;173:1303-1313
 7. Thurfjell MG, Jansson T, Nordgren H, Bergh J, Lindgren A, Thurfjell E. Local breast cancer recurrence caused by mammographically guided punctures. *Acta Radiol* 2000;41:435-440
 8. Hoorntje LE, Schipper ME, Kaya A, Verkooijen HM, Klinkenbijl JG, Borel Rinkes IH. Tumor cell displacement after 14G breast biopsy. *Eur J Surg Oncol* 2004;30:520-525
 9. American College of Radiology. Breast Imaging Reporting and Data System (BI-RADS). 3rd ed. Reston, VA: American College of Radiology; 1998
 10. Grabau DA, Andersen JA, Graversen HP, Dyreborg U. Needle biopsy of breast cancer. Appearance of tumor cells along the needle track. *Eur J Surg Oncol* 1993;19:192-194

2008;59:275 - 278

