



60
가
1.2
HU (50 - 70 HU) (Fig. 1C).
× 1.0 × 0.4 cm
(1).
1970 Chandler (2)
(Fig. 2). 1
(Fig. 3).
(1).
가
(3).
(4)
(Fig. 1A, B).
(Hounsfield units (HU))가
(1, 3, 5).
가
(1, 3).
1970
Chandler (2) Harris (6)

, Calcaterra (7)

(1, 3).

가

가

가

(1, 4).

(3).

(1).

(1).

T1
3-7

T2

T1

T2

(1).

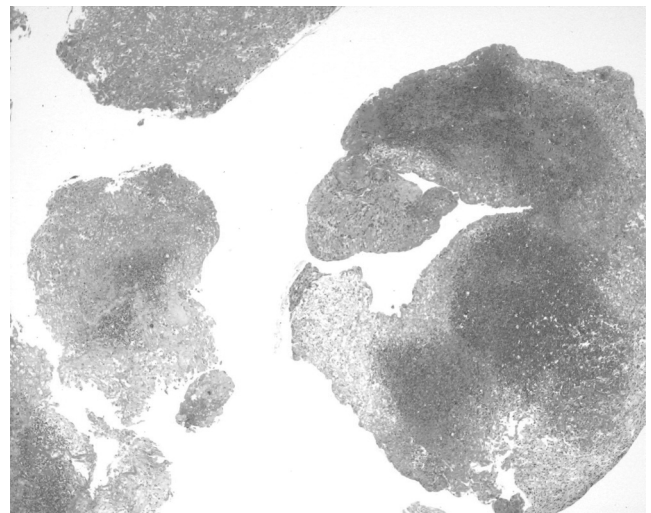


Fig. 2. Microscopically, the mass is composed of blood clots (H & E, $\times 40$).

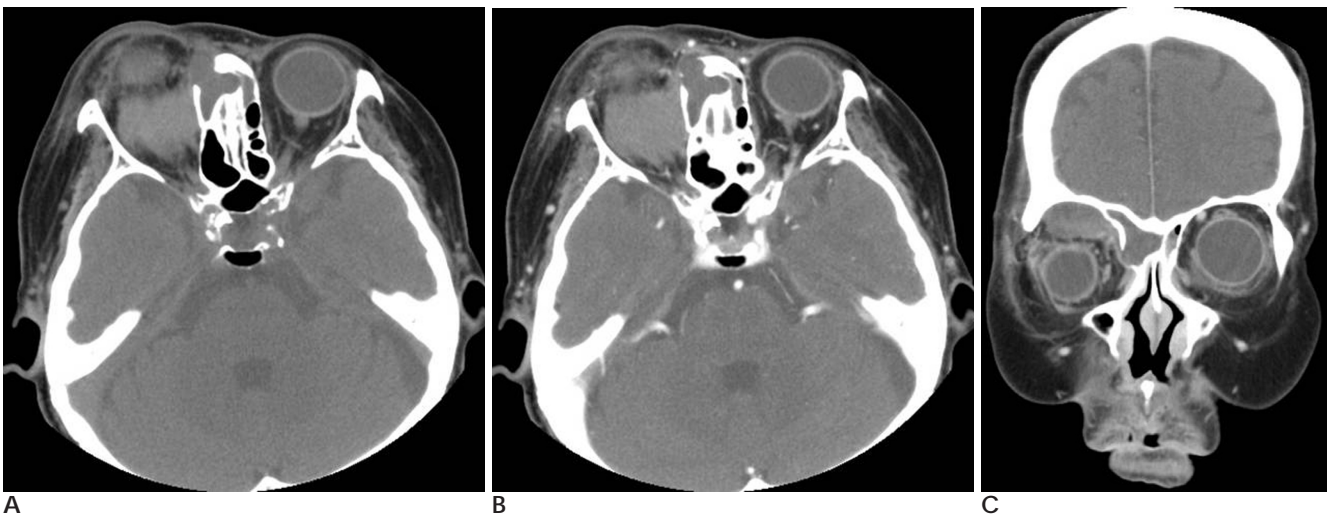


Fig. 1. A. Precontrast axial CT scan shows a homogeneous high density mass in right subperiosteal space, and a soft tissue density lesion in right ethmoid sinus with bone defect and soft tissue swelling in periorbital area. B, C. Contrast enhanced axial (B) and coronal (C) CT scan show non-enhanced high density mass in right orbit subperiosteal space with right ethmoid sinusitis and compression of right eyeball.

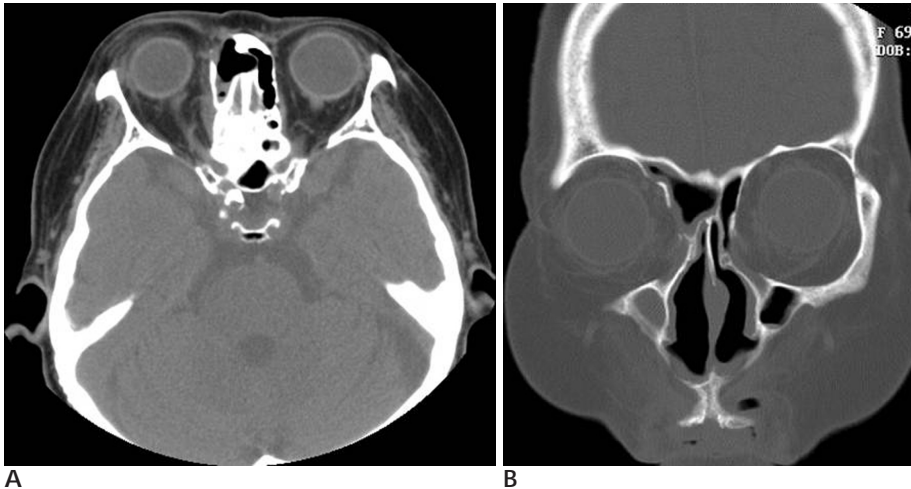


Fig. 3. Follow-up contrast enhanced axial (A) and coronal (B) CT scan after a month show disappeared right orbit subperiosteal hematoma and improved right ethmoid sinusitis.

1. Atalla ML, McNab AA, Sullivan TJ, Sloan B. Nontraumatic subperiosteal orbital hemorrhage. *Ophthalmology* 2001;108:183-189
2. Chandler JR, Langenbrunner DJ, Stevens ER. The Pathogenesis of orbital complications in acute sinusitis. *Laryngoscope* 1970;53:1414-

1428

3. Choi S, Lawson W, Urken ML. Subperiosteal orbital hematoma. An unusual complication of sinusitis. *Arch Otolaryngol Head Neck Surg* 1988;114:1464-1466
4. Woo KI, Kim YD. Subperiosteal hematoma of the orbit associated with sinusitis. *Korean J Ophthalmol* 1997;11:118-122
5. Ichino Y, Nagata M, Ishikawa T. Subperiosteal orbital hemorrhage associated with chronic sinusitis: a case report and review of the literature. *Auris Nasus Larynx* 1985;12:27-30
6. Harris GJ, Kay MC, Nilles JJ. Orbital hematoma secondary to frontal sinusitis. *Ophthalmology* 1978;85:1229-1234
7. Calcaterra TC, Trapp TK. Unilateral proptosis. *Otolaryngol Clin North Am* 1988;21:53-63

Nontraumatic Subperiosteal Orbital Hematoma Associated with Ethmoid Sinusitis: A Case Report¹

Sung-Soo Lee, M.D., Jong Kyu Han, M.D., Byoung Joon Baek, M.D.², Mee-Hye Oh, M.D.³,
Sung Shick Jou, M.D., Hyung Hwan Kim, M.D., Won Kyung Bae, M.D., Il Young Kim, M.D.

¹Department of Radiology, ²Otolaryngology, ³Pathology, Soonchunhyang University, Cheonan Hospital

Subperiosteal hematoma of the orbit is a rare disease and most of the cases occur in young adult males as a result of direct facial or orbital trauma. In the absence of direct facial or orbital trauma, nontraumatic subperiosteal orbital hematoma has rarely been reported in association with a sudden elevation of cranial venous pressure or venous congestion, systemic diseases associated with a bleeding diathesis and paranasal sinusitis. We report here on a rare case of subperiosteal orbital hematoma associated with ethmoid sinusitis, as was seen on CT imaging.

Index words : Subperiosteal hemorrhage
Ethmoid sinusitis
Paranasal sinus
Orbit, CT
Computed tomography (CT), image display

Address reprint requests to : Jong Kyu Han, M.D., Department of Radiology, Soonchunhyang University, Cheonan Hospital
23-20 Bongmyung-dong, Cheonan, Choongnam, 330-721, Korea
Tel. 82-41-570-3515 Fax. 82-41-579-9026 E-mail : mdhjk@schch.co.kr