

Efficacy of a Paclitaxel-Eluting Nitinol Stent on the Inhibition of Pseudointimal Hyperplasia in a Transjugular Intrahepatic Portosystemic Shunt: An Experimental Study in a Swine Model¹

Tae-Seok Seo, M.D., PhD², Joo-Hyeong Oh, M.D., PhD¹, Se Hwan Kwon, M.D.¹,
Young-Koo Park, M.D., PhD³, Ho-Young Song, M.D., PhD⁴, Sun-Hong Yuk, PhD⁵

Purpose: To evaluate the efficacy of a paclitaxel-eluting nitinol stent on the inhibition of pseudointimal hyperplasia in a transjugular intrahepatic portosystemic shunt.

Materials and Methods: Twelve pigs were used in this study. Two types of 10-mm diameter and 60-mm long nitinol stents were made for a transjugular intrahepatic portosystemic shunt by coating them with a polyurethane solution, with and without paclitaxel. Each transjugular intrahepatic portosystemic shunt was created successfully in the 12 swine with 7 paclitaxel-eluting stents and 5 polyurethane stents. Five swine in each group were followed-up for 14 days due to the death of 2 swine given the paclitaxel-eluting stents. The proliferation of the pseudointima was evaluated on both follow-up portograms and histopathology examinations. The mean maximum pseudointimal hyperplasia is expressed as the percentage of the stent radius.

Results: On the portograms, all the transjugular intrahepatic portosystemic shunts using the paclitaxel-eluting stents maintained patency despite there being a complete occlusion of the polyurethane stents in all the animals. The histopathology analysis revealed the mean maximum pseudointimal hyperplasia to be 25% and 76% in the paclitaxel-eluting and control stents, respectively.

Conclusion: A transjugular intrahepatic portosystemic shunt with a paclitaxel-eluting nitinol stent appears to significantly inhibit the formation of pseudointimal hyperplasia.

Index words : Interventional procedures, experimental studies
Shunts, portosystemic
Stents and prostheses
Drugs

¹Departments of Diagnostic Radiology and ³Pathology, Kyung Hee University Hospital, Seoul, Korea

²Department of Radiology, Korea University Guro Hospital, Seoul

⁴Department of Radiology, University of Ulsan, College of Medicine, Seoul

⁵Department of Polymer Science and Engineering, Hannam University, Taejeon

Supported by a grant from the Research Fund, Ministry of Health and Welfare, Republic of Korea

Received November 9, 2006 ; Accepted January 2, 2007

Address reprint requests to : Joo-Hyeong Oh, M.D., Department of Diagnostic Radiology, Kyung Hee University Hospital, Hoeki-dong #1, Dongdaemun-gu, Seoul 130-702, Korea

Tel. 82-2-958-8619 Fax. 82-2-968-0787 E-mail: ohjh6108@hanmail.net

A transjugular intrahepatic portosystemic shunt (TIPS) is a safe, effective, and commonly used method for treating the complications of portal hypertension in patients with cirrhosis of the liver. However, the follow-up data on the patency of TIPS has been disappointing because of the high rate of stenosis. Previous studies have reported the 1-year primary patency rates after the creation of a TIPS to range from 22% to 50% (1 - 4). In addition, it is often associated with the development of pseudointimal hyperplasia within the lumen of the hepatic parenchymal tract.

Restenosis is one of the problems that can occur after placing a stent in a vessel, and is mainly related to an inflammatory response to an injury from the procedure itself and a remodeling of the vessel wall that is caused by the sustained force of the stent on the arterial wall (5, 6). In Several drug-eluting stents with anti-inflammatory and immunosuppressive effects have been developed to overcome this problem, which have been applied clinically in vessels such as the coronary arteries. Recently, some studies have reported that a paclitaxel-eluting stent (PES) is effective in reducing the level of myointimal proliferation in vessels (7 - 9).

However, there are few reports on the implantation of drug-eluting stents in local drug delivery in a TIPS and no study using PES in the TIPS tract (10). We hypothesized that the paclitaxel released from PES would inhibit the pseudointimal hyperplasia in the TIPS tract and improve the patency. The PES was manufactured and an experimental study was performed using them in a swine model. The aim of this study was to evaluate the feasibility and efficacy of a paclitaxel-eluting nitinol stent in reducing the level of pseudointimal hyperplasia in the TIPS tract of a swine model with induced-portal hypertension.

Materials and Methods

Stent Construction

Self-expandable nitinol stents (Hercules vascular stent, S&G Biotech Inc.; Seongnam, Korea) were used in these experiments. When fully expanded, the stents were 60 mm long and 10 mm in diameter. A PES was created by dipping an expanded bare stent into a solution containing paclitaxel and polyurethane (PU), followed by drying in a clean room. The paclitaxel concentration in the solution was 12%. For the control study, a nitinol stent was coated in a PU solution without paclitaxel using the same method used with the PES. The PES and PU stents

were loaded again in their own introducer sets with an outer diameter of size 8-F.

In-vitro Evaluation of Paclitaxel Released from Paclitaxel-PU membrane

In order to determine the amount of paclitaxel released from the paclitaxel and PU mixture, a membrane was made from the solution, and was soaked in a tube containing a 0.1 M neutral phosphate buffer solution, and placed in a shaking incubator. The tube was continuously rotated in an incubator at 37 °C. The buffer solution was exchanged every 24 hours, and the amount of paclitaxel released in the buffer solution was measured using high performance liquid chromatography (Rainin Instrument Co.; Wolburn, MA, U.S.A.) for 2 weeks. The wavelength required to detect paclitaxel was 235 nm, which was the peak absorption point of paclitaxel on the preliminary test.

Animal Experiments

TIPS

All the experimental procedures were performed under the National Institutes of Health guidelines for the humane handling of animals and the committee on animal research at our institution approved this study.

TIPS was performed in 12 domestic swine, each weighing 20 to 25 kg, using 7 paclitaxel stents and 5 PU stents as the control. The technique used for TIPS is described elsewhere (11, 12). The swine were anesthetized with an intramuscular injection of ketamine hydrochloride (Yuhan Corporation; Seoul, Korea), and was maintained with intermittent intravenous injections, whenever needed. Under fluoroscopic guidance, the right external jugular vein was cannulated while iodinated contrast material (Ultravist, Schering Korea; Ansung, Korea) was injected through a vein in the right ear, this was followed by the insertion of a 0.035-inch guide wire (Radiofocus, Terumo; Tokyo, Japan). The tract was gradually dilated up to 9 Fr using a dilator, and a 9-F Teflon sheath (Transjugular Liver Access Set; Cook, Bloomington, IN., U.S.A.) was advanced caudally over the guide wire into the inferior vena cava and hepatic vein. The right hepatic vein was selected using a 5-F cobra catheter (Cook), and a hepatic venogram and wedge portogram was performed to visualize the portal vein. For the puncture, a sheathed 16-gauge Colapinto needle set (Cook) was placed into the right hepatic vein, and the portal vein was punctured via the intrahepatic route. The puncture of the portal vein was confirmed by the

aspiration of portal venous blood and the injection of contrast media. A guide wire was then advanced into the portal vein and the needle was removed. A cobra catheter was advanced over the guide wire into the portal vein, direct portography was performed, and the portal pressure was measured (Fig. 1A). Portal hypotension was induced using a technique described elsewhere (10). A microcatheter (Progreat, Terumo; Tokyo, Japan) was inserted into the portal vein through the cobra catheter, and an intraportal injection of N-butyl-2-cyanoacrylate and lipiodol mixture (1:3) was completed in order to induce portal hypertension. The mixture was injected until the migration of the mixture from the catheter tip to the peripheral portion of the portal vein became sluggish. The total amount of the mixture ranged from 1 to 2 ml. The portal vein was embolized,

and the occluded portal perfusion on the second portogram and increased portal pressure were confirmed (Fig. 1B). The parenchymal tract was dilated using a 10-mm diameter, 4-cm long balloon catheter, and a nitinol stent was placed in the tract. The final portogram was taken, and the portal pressure was measured again (Fig. 1C).

Follow-up and Sacrifice

After 2 weeks, the animals were anesthetized using the method employed in the TIPS procedure. In order to perform the follow-up shunt venogram, the portal vein was selected using the same method employed in the TIPS procedure for swine with a patent tract. On the other hand, in those swine with completely occluded TIPS tracts on the hepatic venograms, the portograms

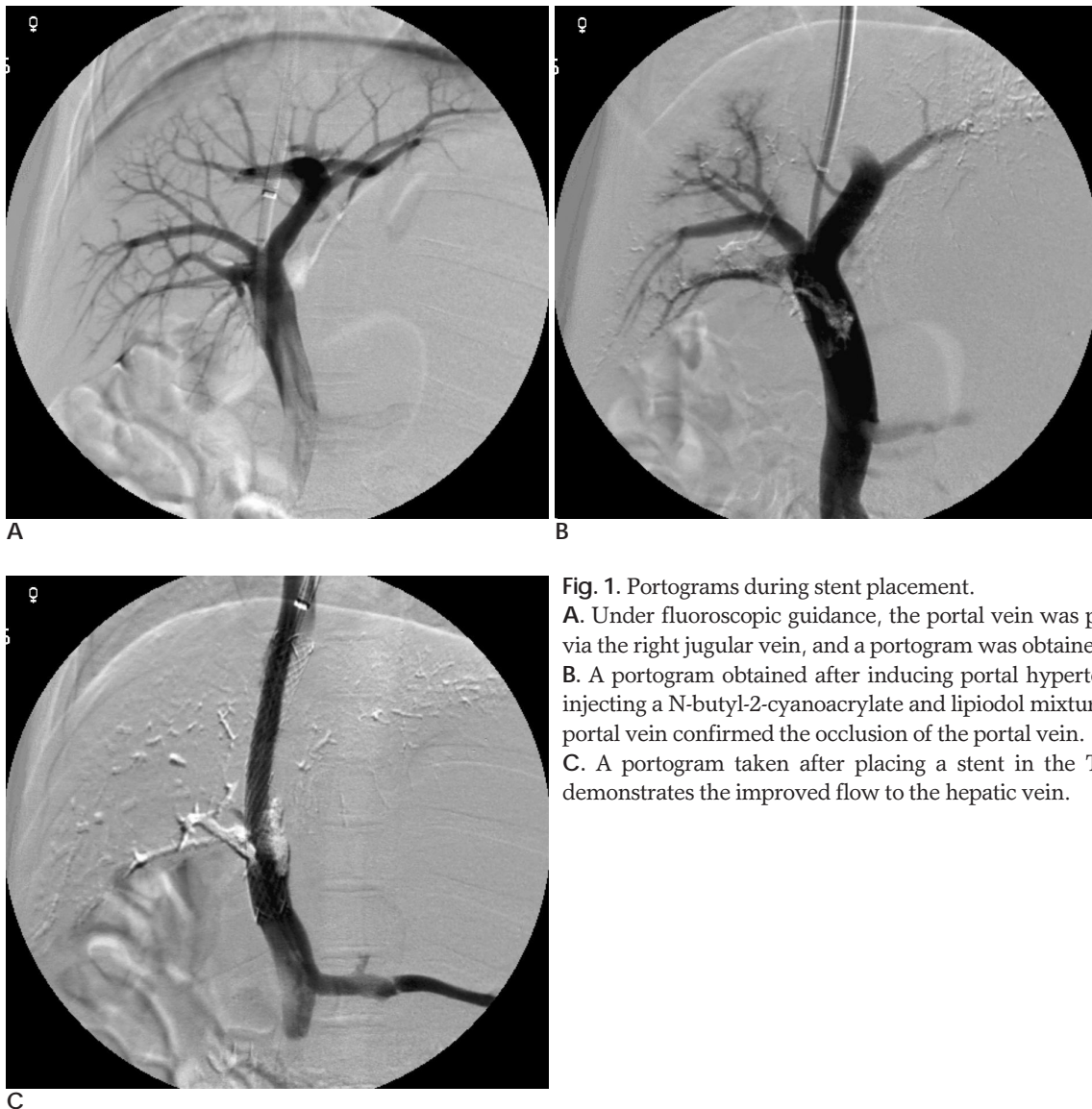


Fig. 1. Portograms during stent placement.

A. Under fluoroscopic guidance, the portal vein was punctured via the right jugular vein, and a portogram was obtained.

B. A portogram obtained after inducing portal hypertension by injecting a N-butyl-2-cyanoacrylate and lipiodol mixture into the portal vein confirmed the occlusion of the portal vein.

C. A portogram taken after placing a stent in the TIPS tract demonstrates the improved flow to the hepatic vein.

were performed by puncturing a tributary of the superior mesenteric vein after making an incision in the midline of the anterior wall of the abdomen. Each animal was euthanized with an intravenous pentobarbital sodium injection (Hanlim Pharm. Co., Ltd.; Seoul, Korea) in order to examine the histology of the tissue around the TIPS. Cross-sections of the TIPS tracts were obtained at the level of the hepatic parenchymal tract; and the specimens were evaluated by staining them with hematoxylin-eosin and Masson-trichrome. The maximum distance from the stent of pseudointimal hyperplasia in each animal was measured on the histopathology examination. The level of maximum pseudointimal hyperplasia was calculated by dividing the radius of the stent by the thickness of the pseudointimal hyperplasia not including the thrombus [10].

Results

In-vitro Evaluation of the Paclitaxel Released from the Stent

The mean increase in stent weight, which was produced by the paclitaxel and PU coating, was 15.2 milligrams. The mean amount of paclitaxel in the PES, which was calculated from the increase in stent weight and the concentration of paclitaxel in the paclitaxel and PU mixture, was 304 μ g.

The in-vitro examination showed that (ed note: this should be moved to the methodology section.) the

amount of paclitaxel released from the membrane of the paclitaxel and PU mixture during the first three days was 4%, 6%, and 4% of the loading dosage, respectively. The cumulative amounts of paclitaxel released during the first and second weeks were 31% and 44%, respectively.

Animal Experiments

TIPS

The TIPS procedures were technically successful in all the swine, and all the stents were deployed accurately without complications. After the stents had been placed, the blood flow to the hepatic vein improved without any disturbances being observed on the final portograms, and the portal pressure was decreased to below the initial pressure. The mean pressure in the portal veins before and after the N-butyl-2-cyanoacrylate injection was 21.0 cmH₂O and 33.9 cmH₂O, respectively. The latter pressure dropped immediately to 22.2 cmH₂O after the TIPS procedure.

Follow-up and Sacrifice

The results of the 2-week follow-up after the TIPS procedure were evaluated in 5 swine from each of the PES and PU stent groups because two swine had died within 3 days of the procedure. On the follow-up portograms in the 5 swine before sacrifice, all of the TIPS tracts that used PES demonstrated luminal patency despite the narrowing of the lumen in the intraparenchymal portion

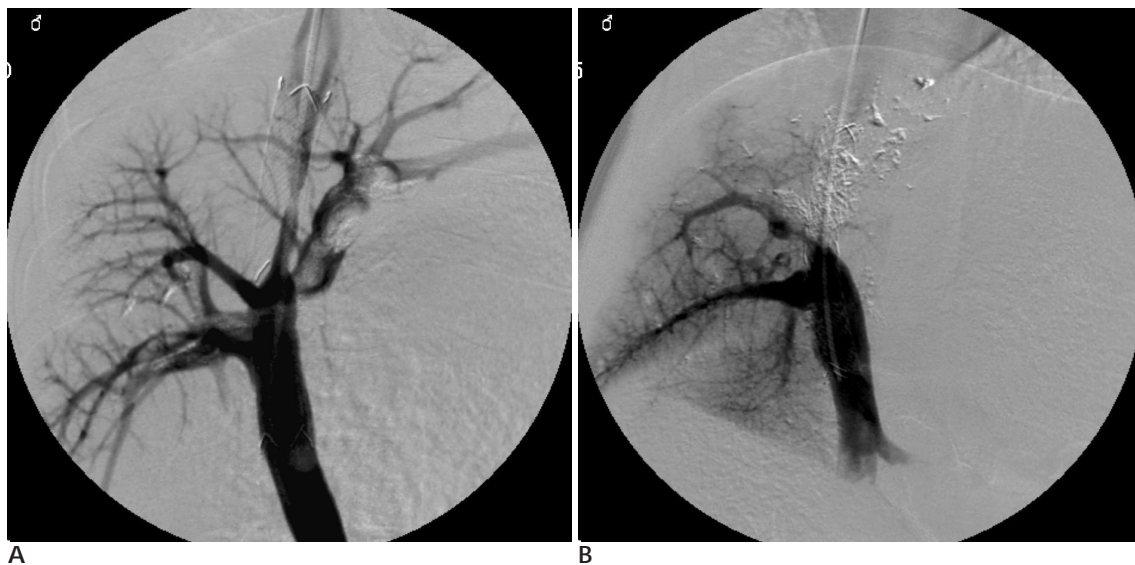

Fig. 2. Follow-up portograms taken 2 weeks after the TIPS procedure.

A. A portogram performed via the hepatic vein in the paclitaxel-eluting stent (PES) group demonstrates a patent TIPS tract, even though a filling defect can be seen within the stent lumen.

B. Portograms in the control group demonstrate the complete occlusion of the TIPS tract.

(Fig. 2A). However, all 5 swine, in which the control stent had been used, had completely occluded lumens of the TIPS tracts (Fig. 2B).

Histopathology Examination

The gross specimens in the PES group showed partial filling of the stent lumen by fibrotic tissue and thrombus, and the stents were easily separated from the tissue of the TIPS tract. However, those in the PU stent group showed the marked ingrowth of fibrotic tissue within the TIPS tracts, which made separation of the stents from the surrounding tissue difficult (Fig. 3A, B).

Histopathology analysis revealed the average maximum pseudointimal hyperplasia for the PES and PU stents to be 25.1% and 73.8%, respectively. The microscopic findings demonstrated relatively thin and uniform pseudointimal hyperplasia within the patent TIPS tracts in the PES stents, and complete occlusion of the TIPS tracts by pseudointimal hyperplasia in the PU stents (Fig. 4). The pseudointimal hyperplasia consisted of myofibroblasts, extracellular collagen matrix, and inflammatory cells infiltrating around the stent wires.

Discussion

Although TIPS is an effective method for portal decompression in patients with variceal bleeding or intractable ascites, it is complicated by portal hypertension, a high rate of restenosis of the tracts and the disappointing long-term patency (1 - 4). The important mechanisms reported to be responsible for the formation of a restenosis or occlusion of the TIPS tracts are chronic in-

flammatory reactions, inhibition of the endothelialization process, excessive proliferation of pseudointimal granulation tissue, and the ingrowth of hepatocytes into the stented lumens of the hepatic parenchymal tracts (13, 14). The layers of pseudointimal granulation tissue contain mesenchymal cells and collagen covered by a layer of endothelial cells.

Various methods and devices have been used to overcome the problems of restenosis or occlusion, and the low primary patency of the TIPS tract. Several studies of TIPS, which used stent-grafts coated with various materials, have been performed using the swine model (12, 15 - 17). Although the placement of a stent-graft in a TIPS tract significantly improved the patency after a


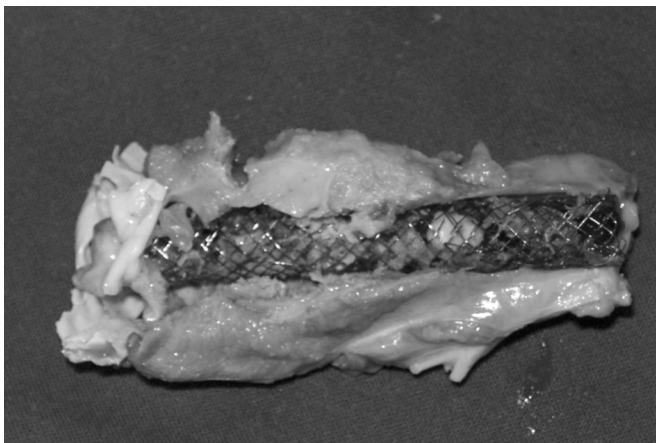
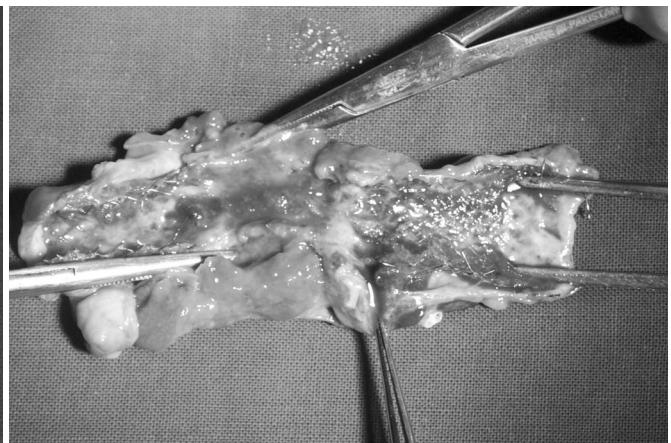


Fig. 4. Microscopic specimen ($\times 10$) stained with H-E. A. Microscopic section in the PES group demonstrates relatively thin and uniform pseudointimal hyperplasia within the patent TIPS tract.



A
Fig. 3. Gross specimen.



B

A. A stent in the PES group was separated easily from the surrounding tissue and demonstrates fibrotic tissue and thrombus within the lumen.

B. A stent in the control group could not be separated because of the marked ingrowth of fibrotic tissue within the TIPS tract.

short-term follow-up study, they caused a late shunt malfunction in certain cases and did not improve the long-term patency as a result of the increased occurrence of thrombogenicity and foreign-body reactions. There have been experimental studies on swine models that used intraluminal irradiation to prevent stenosis of the TIPS tracts. The studies were carried out by applying intraluminal irradiation to the hepatic parenchyma and venous outflow tracts at the time of TIPS placement, which was followed by the use of a radionuclide-filled balloon catheter. However, the results were inconclusive (11, 18, 19). Intraluminal irradiation has several limitations that have to be overcome before it can be used clinically. They include the complexity of the preparation of the radionuclide solution, the difficulty in maintaining the irradiation dose, and the lengthy inflation time of the balloon catheter.

Restenosis after the implantation of a stent is a problem that occurs in treated vessels, and many studies have been carried out to determine appropriate preventative measures: a drug-eluting stent being one such method. There have been many clinical applications of several drug-eluting stents using various drugs, such as paclitaxel, rapamycin, dexamethasone, and heparin, some with extremely promising results in terms of suppressing neointimal hyperplasia and dramatically reducing the rate of restenosis (7, 9, 20 - 23). In recent experimental studies, the application of drug-eluting stents was attempted in non-vascular organs, such as the bile duct and trachea (24, 25). In the TIPS tract, one study used a dexamethasone-eluting stent in a swine model and demonstrated a tendency to inhibit the development of pseudointimal hyperplasia (10).

Paclitaxel is a cytotoxic, anti-cancer drug that inhibits tumor growth through its anti-proliferative and anti-angiogenic properties (26, 27). Paclitaxel also inhibits neointimal hyperplasia in vessels through persistent fibrin deposition, inflammatory cell infiltration, and reducing the number of smooth muscle cells, which are associated with a restenosis after placing the stents (28, 29). The PES with a topical therapeutic drug within the target tissues is popular in percutaneous coronary interventions. The nine-month follow-up results of a prospective randomized study demonstrated that the lumen volumes, which were evaluated using serial volumetric intravascular ultrasound examinations, were larger in the PES group than in the bare-metal stent group, due to a decrease in the neointimal volume (30). In non-vascular organs, it was reported that paclitaxel has a potential an-

ti-proliferative effect in experimental studies using human epithelial gallbladder cells, human fibroblasts, and bladder tissues (27, 31). Shin et al performed an experimental application of the PES in non-vascular organs, using a canine urethral model, and reported that it could reduce the level of tissue hyperplasia after placing the stent (32).

In this study, the pseudointima within the patent TIPS tract in the PES group was relatively uniform and thin, which was in contrast to the histopathology findings of the complete occlusion of the TIPS tract in the control stent group. It is believed that those results were the result of a similar mechanism of paclitaxel that is observed in the arteries and other non-vascular organs. Because the pseudointima in the TIPS tract was composed of myofibroblasts and inflammatory cells, paclitaxel inhibited the proliferation of fibroblasts and the infiltration of inflammatory cells, reduced the number of smooth muscle cells, and inhibited the proliferation of the pseudointima. However, despite the inhibition of pseudointimal hyperplasia by paclitaxel, the partial thrombosis within the TIPS tract remained a problem, which might increase the rate of occlusion of the TIPS tract and decrease its patency. It was surmised that bile leakage was responsible for the thrombosis within the TIPS tract after placing the PES. Although there is still some controversy regarding the issue, the transection of the major bile ducts that occurred during the formation of the TIPS tracts and the leakage of bile from the injured ducts are related to the thrombosis in the TIPS tracts, particularly rapid and early thrombosis (33 - 35). In this study, a thrombosis within the TIPS tract that is caused by bile leakage might not be suppressed because paclitaxel does not have an anti-thrombogenic effect. Therefore, further studies will be needed to determine if the combined use of an anti-thrombotic agent can reduce the frequency of thrombosis. In addition, an evaluation of the relationship between thrombosis and the materials for the PES, such as stent metal or PU, is warranted.

There were several limitations in this study. First, there were a small number of animals and the statistical significance was not determined, even though the portography and histopathology findings were similar in each of the 5 animals in their respective group. This result was attributed to the effectiveness of paclitaxel. Second, the concentration of paclitaxel in the blood, which is a parameter for determining the amount of paclitaxel released from the PES after its placement in the

TIPS tract, was not evaluated. The release pattern of paclitaxel from PES may be different in in vitro and in vivo tests. Furthermore, the cause of the death of the two swine that expired 3 days after PES placement is unknown. This is despite a necropsy being performed. In addition, the possible toxicity of paclitaxel was not determined.

In conclusion, the paclitaxel-eluting stent showed a tendency to significantly inhibit the development of pseudointimal hyperplasia in a TIPS tract of a swine model with induced-portal hypertension. Although further study will be needed, this method has potential to improve the patency of the TIPS tract.

References

- Haskal ZJ, Pentecost MJ, Soulen MC, Shlansky-Goldberg RD, Baum RA, Cope C. Transjugular intrahepatic portosystemic shunt stenosis and revision: early and midterm results. *AJR Am J Roentgenol* 1994;163:439-444
- LaBerge JM, Somberg KA, Lake JR, Gordon RL, Kerlan RK Jr, Ascher NL, et al. Two-year outcome following transjugular intrahepatic portosystemic shunt for variceal bleeding: results in 90 patients. *Gastroenterology* 1995;108:1143-1151
- ter Borg PC, Hollemans M, Van Buuren HR, Vleggaar FP, Groeneweg M, Hop WC, et al. Transjugular intrahepatic portosystemic shunts: long-term patency and clinical results in a patient cohort observed for 3-9 years. *Radiology* 2004;231:537-545
- Zhuang ZW, Teng GJ, Jeffery RF, Gemery JM, Janne d'Othee B, Bettmann MA. Long-term results and quality of life in patients treated with transjugular intrahepatic portosystemic shunts. *AJR Am J Roentgenol* 2002;179:1597-1603
- Duda SH, Poerner TC, Wiesinger B, Rundback JH, Tepe G, Wiskirchen J, et al. Drug-eluting stents: potential applications for peripheral arterial occlusive disease. *J Vasc Interv Radiol* 2003;14:291-301
- Shofti R, Tio F, Beyar R. Neointimal vascularization and intimal thickening in response to self-expanding stents: a swine model. *Int J Cardiovasc Interv* 2004;6:61-67
- Grube E, Silber S, Hauptmann KE, Buellesfeld L, Mueller R, Lim V, et al. Two-year-plus follow-up of a paclitaxel-eluting stent in de novo coronary narrowings (TAXUS I). *Am J Cardiol* 2005;96:79-82
- Serruys PW, Sianos G, Abizaid A, Aoki J, den Heijer P, Bonnier H, et al. The effect of variable dose and release kinetics on neointimal hyperplasia using a novel paclitaxel-eluting stent platform: the Paclitaxel In-Stent Controlled Elution Study (PISCES). *J Am Coll Cardiol* 2005;46:253-260
- Werner GS, Krack A, Schwarz G, Prochnau D, Betge S, Figulla HR. Prevention of lesion recurrence in chronic total coronary occlusions by paclitaxel-eluting stents. *J Am Coll Cardiol* 2004;44:2301-2306
- Seo TS, Oh JH, Park YK, Song HY, Park SJ, Yuk SH. Efficacy of a Dexamethasone-eluting nitinol stent on inhibition of pseudointimal hyperplasia in a transjugular intrahepatic portosystemic shunt: an experimental study in a swine model. *Korean J Radiol* 2005;6:241-247
- Lessie T, Yoon HC, Nelson HA, Fillmore DJ, Baldwin GN, Miller FJ. Intraluminal irradiation for TIPS stenosis: preliminary results in a swine model. *J Vasc Interv Radiol* 1999;10:899-906
- Nishimine K, Saxon RR, Kichikawa K, Mendel-Hartvig J, Timmermans HA, Shim HJ, et al. Improved transjugular intrahepatic portosystemic shunt patency with PTFE-covered stent-grafts: experimental results in swine. *Radiology* 1995;196:341-347
- LaBerge JM, Ferrell LD, Ring EJ, Gordon RL, Lake JR, Roberts JP, et al. Histopathologic study of transjugular intrahepatic portosystemic shunts. *J Vasc Interv Radiol* 1991;2:549-556
- Terayama N, Matsui O, Kadoya M, Yoshikawa J, Gabata T, Miyayama S, et al. Transjugular intrahepatic portosystemic shunt: histologic and immunohistochemical study of autopsy cases. *Cardiovasc Interv Radiol* 1997;20:457-461
- Haskal ZJ, Brennecke LJ. Porous and nonporous polycarbonate urethane stent-grafts for TIPS formation: biologic responses. *J Vasc Interv Radiol* 1999;10:1255-1263
- Tanihata H, Saxon RR, Kubota Y, Pavcnik D, Uchida BT, Rosch J, et al. Transjugular intrahepatic portosystemic shunt with silicone-covered Wallstents: results in a swine model. *Radiology* 1997;205:181-184
- Zhuang ZW, Hoopes PJ, Koutras PC, Ebbighausen WH, Wagner RJ, Bettmann MA. Transjugular intrahepatic portosystemic shunt with an autologous vein-covered stent: results in a swine model. *J Vasc Interv Radiol* 2001;12:1333-1342
- Hausegger KA, Portugaller H, Macri NP, Tauss J, Schedlbauer P, Deutschmann J, et al. Covered stents in transjugular portosystemic shunt: healing response to non-porous ePTFE covered stent grafts with and without intraluminal irradiation. *Eur Radiol* 2003;13:1549-1558
- Pokrajac B, Cejna M, Kettenbach J, Schamp S, Fellner C, Seitz W, et al. Intraluminal 192Ir brachytherapy following transjugular intrahepatic portosystemic shunt revision: long-term results and radiotherapy parameters. *Cardiovasc Radiat Med* 2001;2:133-137
- Ahn YK, Jeong MH, Kim JW, Kim SH, Cho JH, Cho JG, et al. Preventive effects of the heparin-coated stent on restenosis in the porcine model. *Catheter Cardiovasc Interv* 1999;48:324-330
- Lincoff AM, Furst JG, Ellis SG, Tuch RJ, Topol EJ. Sustained local delivery of dexamethasone by a novel intravascular eluting stent to prevent restenosis in the porcine coronary injury model. *J Am Coll Cardiol* 1997;29:808-816
- Prasad CK, Resmi KR, Krishnan LK, Vaishnav R. Survival of endothelial cells in vitro on Paclitaxel-loaded coronary stents. *J Biomater Appl* 2005;19:271-286
- Sousa JE, Costa MA, Abizaid AC, Rensing BJ, Abizaid AS, Tnaajura LF, et al. Sustained suppression of neointimal proliferation by sirolimus-eluting stents: one-year angiographic and intravascular follow-up. *Circulation* 2001;104:2007-2011
- Lee DK, Kim HS, Kim KS, Lee WJ, Kim HK, Won YH, et al. The effect on porcine bile duct of a metallic stent covered with a paclitaxel-incorporated membrane. *Gastrointest Endosc* 2005;61:296-301
- Shin JH, Song HY, Seo TS, Yuk SH, Kim YH, Cho YM, et al. Influence of a dexamethasone-eluting covered stent on tissue reaction: an experimental study in a canine bronchial model. *Eur Radiol* 2005;15:1241-1249
- Dhanikula AB, Panchagnula R. Localized paclitaxel delivery. *Int J Pharm* 1999;183:85-100
- Kalinowski M, Alfke H, Kleb B, Durfeld F, Joachim Wagner H. Paclitaxel inhibits proliferation of cell lines responsible for metal stent obstruction: possible topical application in malignant bile duct obstructions. *Invest Radiol* 2002;37:399-404
- Drachman DE, Edelman ER, Seifert P, Groothuis AR, Bornstein DA, Kamath KR, et al. Neointimal thickening after stent delivery of paclitaxel: change in composition and arrest of growth over six

- months. *J Am Coll Cardiol* 2000;36:2325-2332
29. Heldman AW, Cheng L, Jenkins GM, Heller PF, Kim DW, Ware M Jr, et al. Paclitaxel stent coating inhibits neointimal hyperplasia at 4 weeks in a porcine model of coronary restenosis. *Circulation* 2001;103:2289-2295
 30. Weissman NJ, Koglin J, Cox DA, Hermiller J, O'Shaughnessy C, Mann JT, et al. Polymer-based paclitaxel-eluting stents reduce in-stent neointimal tissue proliferation: a serial volumetric intravascular ultrasound analysis from the TAXUS-IV trial. *J Am Coll Cardiol* 2005;45:1201-1205
 31. Song D, Wientjes MG, Au JL. Bladder tissue pharmacokinetics of intravesical taxol. *Cancer Chemother Pharmacol* 1997;40:285-292
 32. Shin JH, Song HY, Choi CG, Yuk SH, Kim JS, Kim YM, et al. Tissue hyperplasia: influence of a paclitaxel-eluting covered stent—preliminary study in a canine urethral model. *Radiology* 2005;234:438-444
 33. Jalan R, Harrison DJ, Redhead DN, Hayes PC. Transjugular intrahepatic portosystemic stent-shunt (TIPSS) occlusion and the role of biliary venous fistulae. *J Hepatol* 1996;24:169-176
 34. LaBerge JM, Ferrell LD, Ring EJ, Gordon RL. Histopathologic study of stenotic and occluded transjugular intrahepatic portosystemic shunts. *J Vasc Interv Radiol* 1993;4:779-786
 35. Saxon RR, Mendel-Hartvig J, Corless CL, Rabkin J, Uchida BT, Nishimine K, et al. Bile duct injury as a major cause of stenosis and occlusion in transjugular intrahepatic portosystemic shunts: comparative histopathologic analysis in humans and swine. *J Vasc Interv Radiol* 1996;7:487-497

2007;56:225 - 232

