

MR Imaging of Uncommon Soft Tissue Tumors in the Foot: A Pictorial Essay¹

Youn Joo Lee, M.D., Kyung Ah Chun, M.D., Jee Young Kim, M.D.,
Mi Sook Sung, M.D., Ki Tae Kim, M.D.

A large variety of masses occur in the foot. The foot is a comparatively rare site of soft tissue neoplasms. MRI has greatly improved the ability to detect and delineate soft tissue lesions and is now considered the gold-standard imaging technique in their investigation. Recently, we have encountered rare soft tissue tumors of the foot. The presented cases include benign masses such as granuloma annulare, angiomyoma, neural fibrolipoma, and giant cell tumor of tendon sheath, as well as malignant tumors such as melanoma, synovial sarcoma, rhabdomyosarcoma and extraskelatal myxoid chondrosarcoma. We wish to illustrate the MR findings of these uncommon soft tissue tumors to aid in their diagnosis.

Index words : Foot, neoplasms

Neoplasms, MR

Magnetic resonance (MR), image display

Soft tissues, neoplasms

Neoplasms, diagnosis

The foot is a relatively rare site of neoplastic and non-neoplastic soft tissue masses. Although it contains a relatively small amount of somatic soft tissue elements, the foot is rich in tendons, fasciae, retinaculae, and synovium (1). In the Armed Forces Institute of Pathology series [LKH1], 8% of benign soft-tissue tumors and 5% of malignant soft-tissue tumors occurred in the foot and ankle, suggesting an unexpectedly high incidence on a tissue volume basis. In general, benign tumors occur at least 10 times more frequently than malignant soft tissue tumors. In one series of soft-tissue tumors of the foot and ankle, 87% of lesions were benign (2).

Of all the imaging modalities, MRI demonstrates supe-

rior soft tissue characterization and is now considered the gold-standard imaging technique in their investigation. Lately, we have encountered rare benign masses and malignant soft tissue tumors of the foot. The presented cases include benign masses such as granuloma annulare, angiomyoma, neural fibrolipoma, and giant cell tumor of tendon sheath, as well as malignant tumors such as melanoma, synovial sarcoma, rhabdomyosarcoma and extraskelatal myxoid chondrosarcoma. There are few published English reports addressing the MR appearance of these masses. This pictorial essay shows MR features of uncommon soft tissue tumors of the foot with associated clinicopathologic findings.

Benign masses of the foot

Granuloma annulare

Granuloma annulare is an uncommon benign inflammatory dermatosis characterized by the formation of

¹Department of Radiology, The Catholic University of Korea

Received December 21, 2006 ; Accepted March 23, 2007

Address reprint requests to : Kyung Ah Chun, M.D., Department of Radiology, The Catholic University of Korea, Uijeongbu St. Mary's Hospital, Geumo-dong, Uijeongbu city, Gyeonggi-do 480-821, Korea.

Tel. 82-31-820-3137 Fax. 82-31-846-3080

E mail: ka1000@catholic.ac.kr

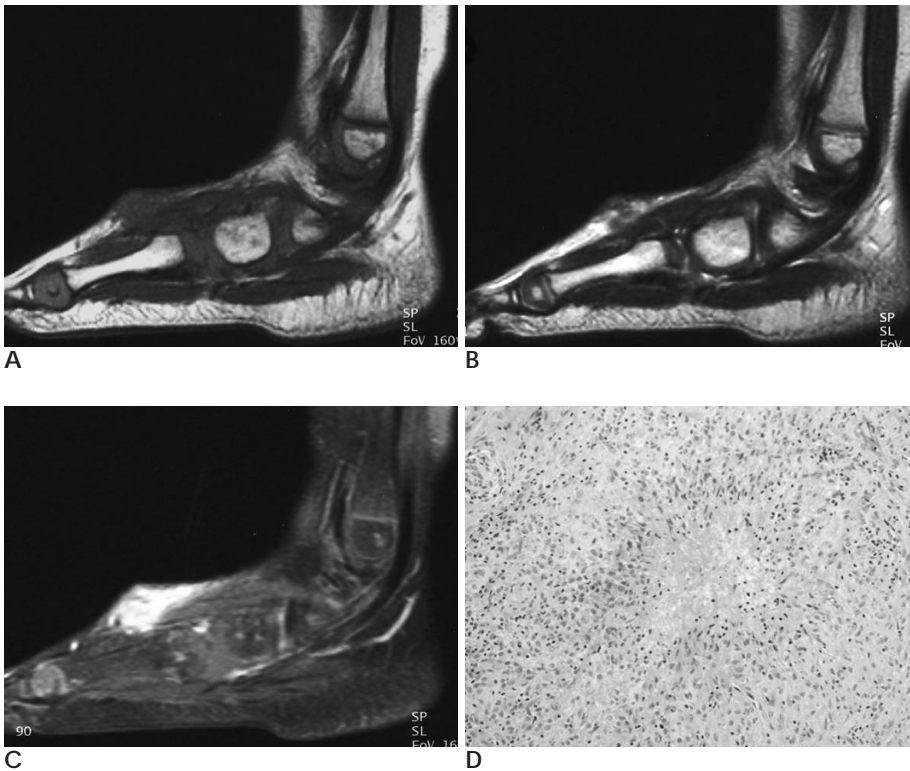


Fig. 1. Granuloma annulare in a 6-year-old boy.

A. Sagittal T1-weighted image shows a poorly-defined, isointense signal intensity subcutaneous lesion in the dorsal aspect of the foot.

B. Sagittal T2-weighted image shows heterogeneously low signal intensity.

C. Sagittal post-gadolinium T1-weighted image with fat saturation exhibits diffuse enhancement of the subcutaneous lesion.

D. Photomicrograph ($\times 100$, H & E stain) shows well-circumscribed palisaded granuloma with granular and fibrillary, slightly basophilic material (mucin) around collagen bundles in the foci of histiocytic aggregation.

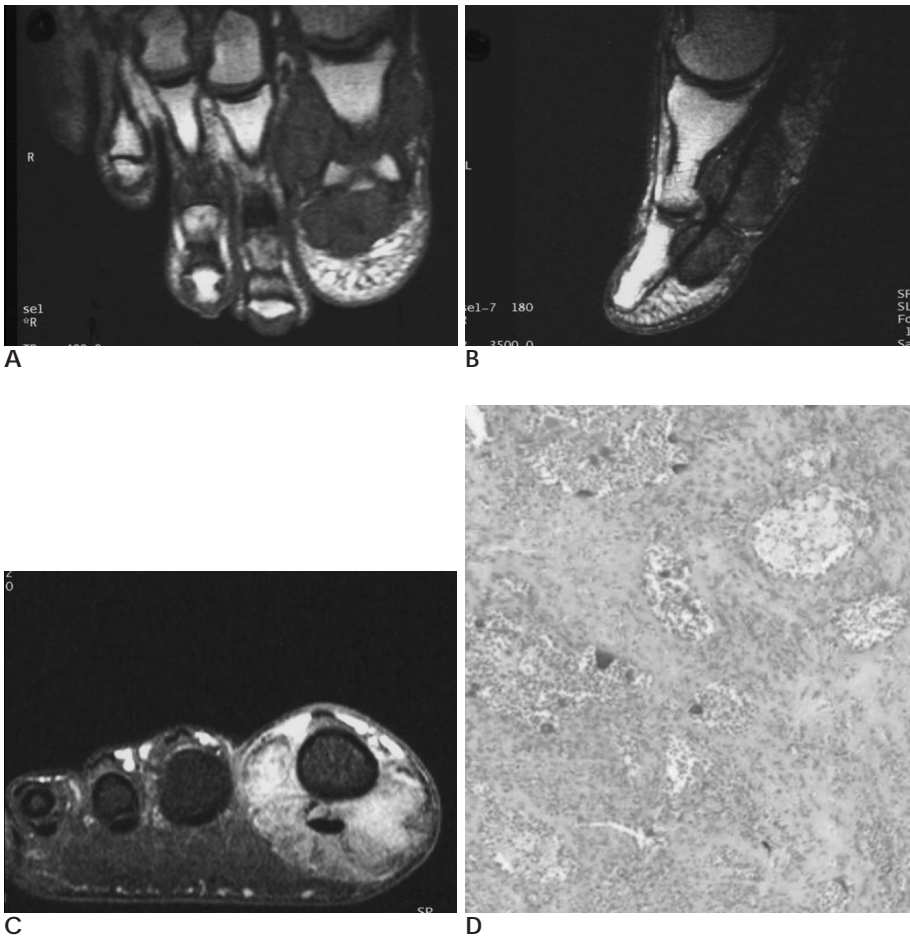


Fig. 2. Giant cell tumor of tendon sheath in a 29-year-old man

A, B. Axial T1-weighted (**A**) or sagittal T2-weighted (**B**) images show a large lobulated low signal intensity mass of the great toe.

C. Enhanced coronal fat saturated T1-weighted image shows prominent enhancement of the mass surrounding the flexor tendon.

D. Photomicrograph ($\times 100$, H & E stain) demonstrates rounded or polygonal cells with focal collections of xanthoma cells and scattered multinucleated giant cells throughout the mass.

dermal papules with a tendency to form rings (3). Granuloma annulare represents about 2% of all benign soft tissue masses (4). About 7% of granuloma annulare present in the foot and ankle. There are several clinically distinct forms: localized, generalized, perforating, and subcutaneous. The localized form is the most common type and presents as a nodular ringed skin eruption, typically on the dorsum of the hands and feet, forearms, arms, legs, and thighs. It typically presents as a rapidly growing, solitary, painless, subcutaneous nodule. It is a disease of children and young adults, with two-thirds of patients presenting by age 30. The subcutaneous form presents with rapidly growing, painless, solitary superficial nodule. Lesions are most common in the pretibial region, but may be seen in the scalp, foot, and ankle (3).

MR imaging reveals a subcutaneous mass with indistinct margin. This lesion has isointense signal intensity relative to the muscle on T1-weighted images, and low or heterogeneously hyperintense signal intensity on T2-weighted images (3). On enhanced T1-weighted images, mass shows extensive diffuse enhancement.

Giant cell tumor of tendon sheath

5 - 15% of giant cell tumors of tendon sheath present in the foot and ankle, typically in the first two toes (3). Giant cell tumor of the tendon sheath represents about 4% of all benign soft tissue masses (4). It usually occurs in adults with a peak incidence in the third to fifth

decades and predominates in females. Pathologically, giant cell tumor of tendon sheath is a highly vascular mass containing a mixture of multinucleated giant cells with deposition of intra- and extracellular hemosiderin due to repeated hemorrhage, as well as macrophages, fibroblasts, and xanthoma cells, which are the same histologic features as pigmented villonodular synovitis.

The main MR feature is a well-defined mass adjacent to the tendon. Typically the mass shows low signal intensity on both T1-weighted and T2-weighted images, due to the paramagnetic effect of hemosiderin.

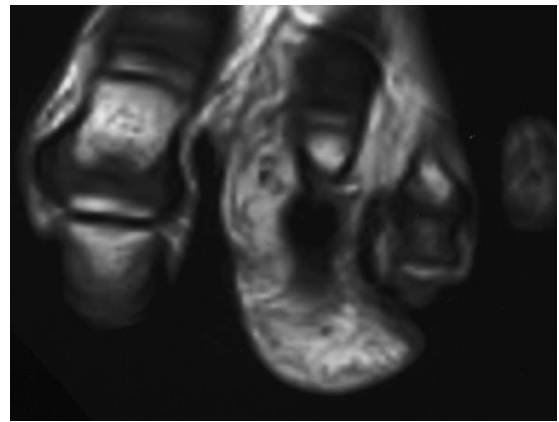


Fig. 4. Neural fibrolipoma in an 8-year-old boy. Axial T1-weighted image shows heterogeneous lipomatous mass involving the second toe. Low signal areas correspond to neural tissue, while areas of high signal represent adipose tissue.

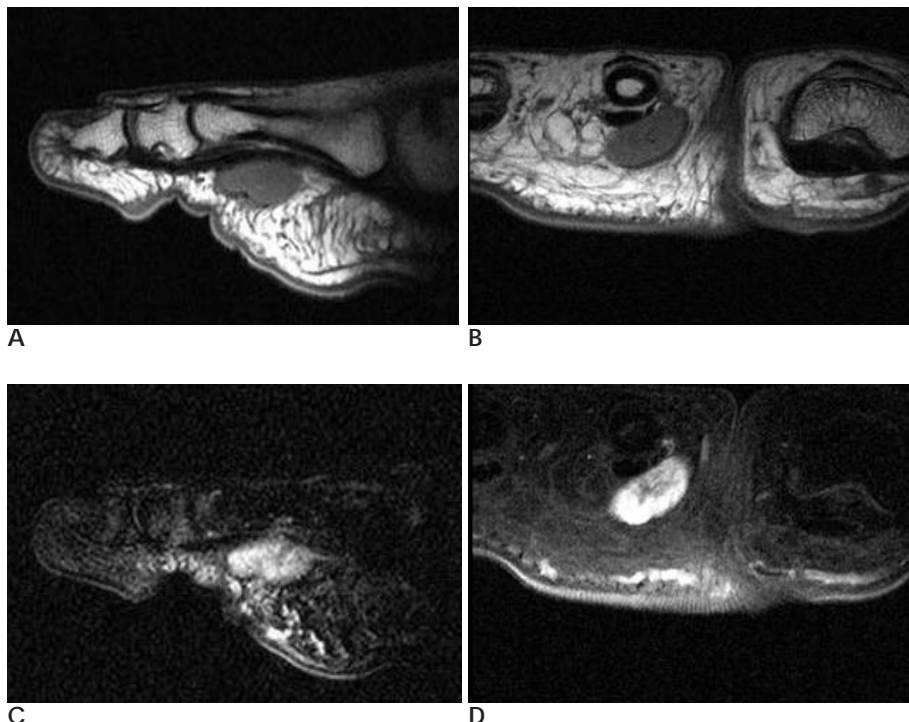


Fig. 3. Angiomyoma in a 41-year-old woman
A, B. Sagittal (A) and coronal (B) T1-weighted images show small low signal intensity mass in the plantar aspect of the foot.
C. Sagittal T2-weighted image with fat saturation shows heterogeneous high signal intensity mass.
D. Enhanced coronal fat saturated T1-weighted image demonstrates inhomogeneous strong enhancement.

Gradient-echo sequences may be helpful because of the increased magnetic susceptibility effect produced by hemosiderin. Areas with a high proportion of xanthoma cells may add regional MR characteristics of lipomatous tissue with fat-equivalent signal intensity on all pulse sequences (1). Intense enhancement is frequently observed on postcontrast image (3).

Angiomyoma

The angiomyoma is a rare form of leiomyoma that usually occurs as a solitary subcutaneous form and originates in the tunica media of vessels (1). They account for 5% of all benign soft tissue tumors. These tumors are frequent in women in their fourth to sixth decades. Angiomyomas are typically small (0.5 - 2 cm), round, or oval tumors. The main symptoms are pain and tenderness (3). Histologic features of angiomyoma are vascular channels with proliferation of smooth muscle cells.

MR shows low signal intensity on T1-weighted image and heterogeneous high signal intensity on T2-weighted image. Hyperintense regions on T2-weighted image demonstrated strong enhancement on post-contrast T1-weighted image, corresponding to bundles of smooth muscles around capillary-sized vessels. Areas with low signal intensity on T2-weighted image were related to tough fibrous tissue, with or without hyaline degeneration (1).

Neural fibrolipoma

Neural fibrolipoma, also known as lipofibromatous hamartoma, perineural lipoma, and intraneural lipoma, is a benign mass composed of hypertrophied fibrofatty tissues intermixed with nerve tissues. When it is associated with macrodactyly, it is called macrodystrophia lipomatosa. This benign condition is characterized by a unilateral, gradually enlarging mass on a distal extremity during early adulthood. The upper extremity, especially the median nerve is the site most often affected. Histologically, neural fibrolipoma is characterized by the proliferation of fibrofatty elements (5).

MR shows small, cylindrical, low signal intensities on high signal intensity background. This represents the nerve fascicles with epineural and perineural fibrosis on a background of fatty tissue.

Malignant masses of the foot

Malignant melanoma

Malignant melanoma (melanosarcoma) is a neoplasm containing fibroblast-like cells, some of which contain melanin. It can arise from the skin and produce local and distant osseous destruction. Melanomas on the foot are often detected at an advanced stage. Melanoma of the foot accounts for 3% to 15% of all cutaneous melanomas (6).

MR shows higher and relatively homogenous signal

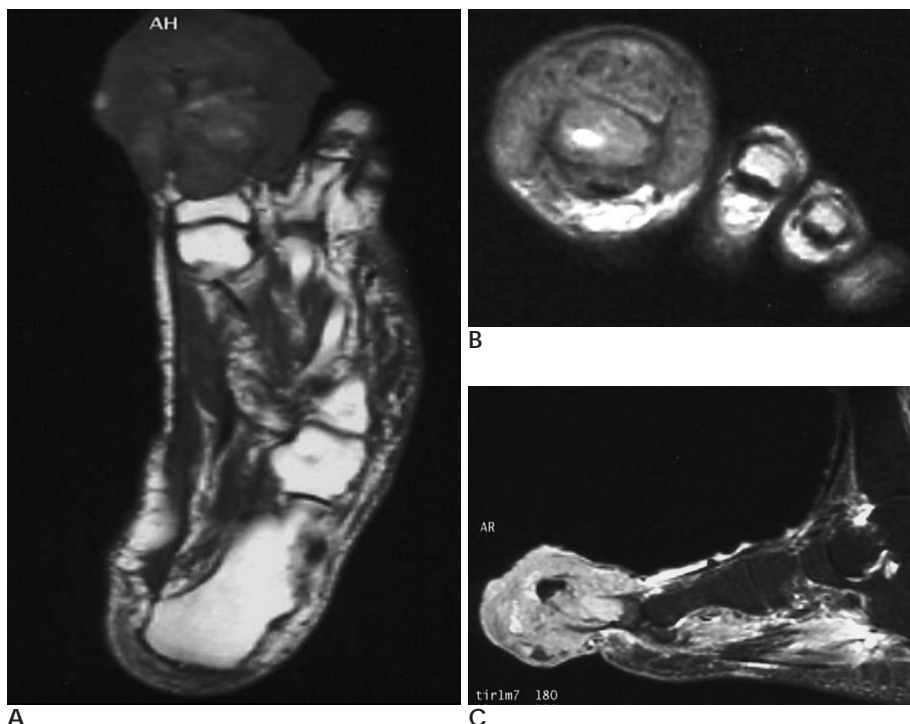


Fig. 5. Malignant melanoma in a 79-year-old woman.

A. Axial T1-weighted image shows a large lobulated intermediate signal intensity mass of the great toe with adjacent bone destruction.

B. Coronal T2-weighted image exhibits somewhat heterogeneous intermediate signal intensity mass.

C. Enhanced sagittal fat saturated T1-weighted image shows heterogeneous enhancement extending to the bone and dorsal subcutaneous tissue of the foot.

intensity compared to muscle on T1-weighted image, with lower and more heterogeneous signal intensity relative to muscle on T2-weighted image. Melanin causes shortening of T1 and T2 values, resulting in higher signal intensity on T1-weighted and lower signal intensity on T2-weighted image. Signal intensities on T2-weighted image are influenced by the cellularity and the nucleocytoplasmic index of the lesions, resulting in variable signals on T2-weighted image (1).

Rhabdomyosarcoma

Rhabdomyosarcoma was originally thought to arise from striated muscle, but is now regarded as a primary mesenchymal tumor in which rhabdomyoblastic differentiation has occurred (3). Rhabdomyosarcoma comprises approximately 20% of all soft tissue sarcomas (7). It may arise anywhere in the body, and the incidence in

the extremities is reported to be about 14% (4). Rhabdomyosarcomas vary widely in histological appearance, depending on the growth pattern, cellularity, degree of differentiation, and configuration of the individual tumor cells. Rhabdomyosarcoma is classified into three main subgroups: embryonal, alveolar, and pleomorphic. Embryonal is the most common type and occurs in the first decade of life. Embryonal rhabdomyosarcoma is composed of small cells with round or spindle-shaped hyperchromatic nuclei and varying numbers of larger cells that have eosinophilic cytoplasm, which is characteristic of rhabdomyoblasts. The alveolar subtype is more common in adolescents and young adults and is usually intramuscular. It is composed of small, round to oval cells forming nests separated by fibrous connective tissue. The pleomorphic type is typically seen in adults. Pathologic diagnosis of this type

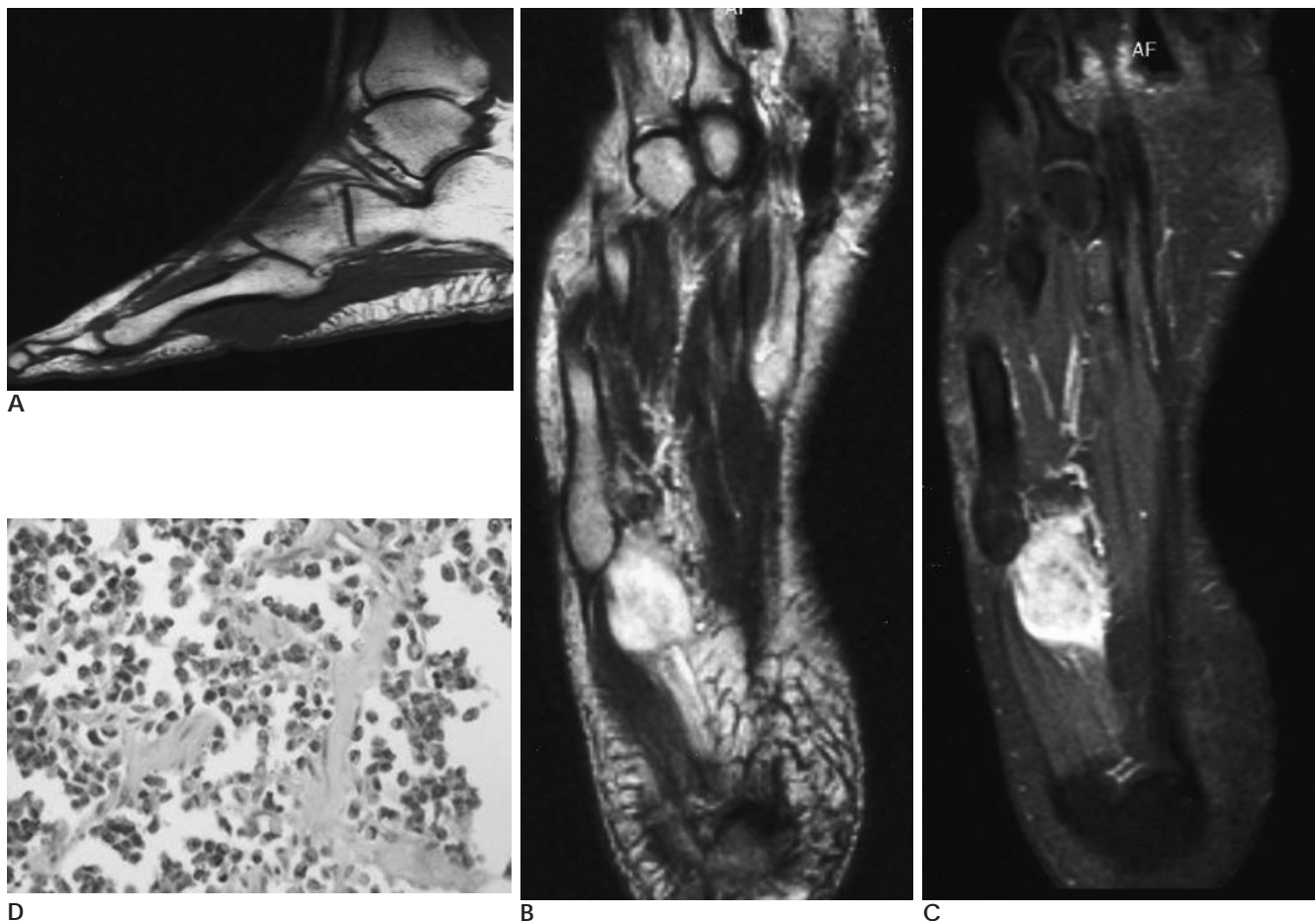


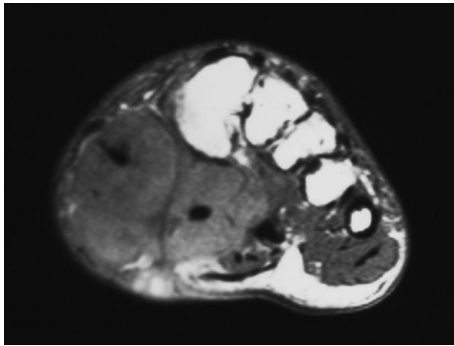
Fig. 6. Rhabdomyosarcoma in a 42-year-old woman

A. Sagittal T1-weighted image shows poorly-defined low signal intensity mass.

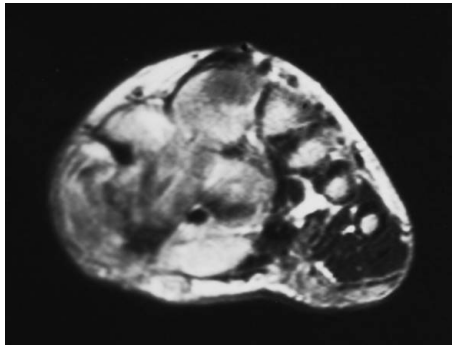
B. Axial T2-weighted image shows high signal intensity mass with low signal strand.

C. Axial post-gadolinium T1-weighted image with fat saturation reveals strong enhancement of the mass.

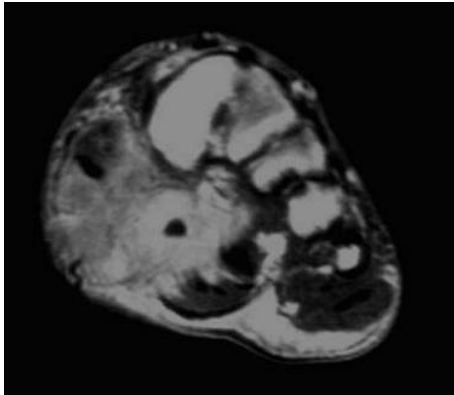
D. Photomicrograph ($\times 200$, H & E stain) shows ill-defined aggregation of poorly-differentiated round or oval cells, and formation of irregular alveolar spaces separated and surrounded by a framework of dense fibrous septa.



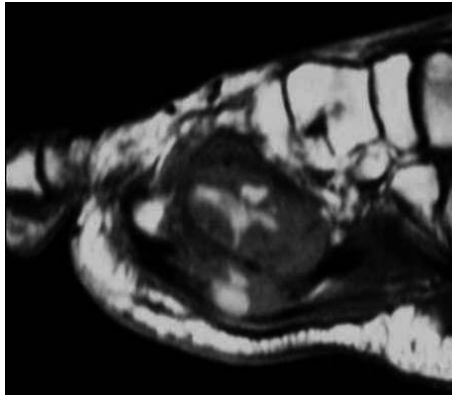
A



B



C



D

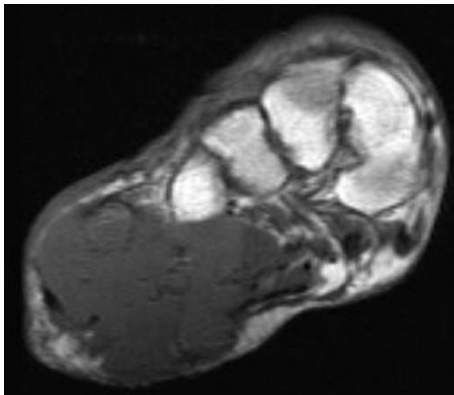
Fig. 7. Synovial sarcoma in a 38-year-old man

A. Coronal T1-weighted image represents a large low signal intensity mass with internal septum-like structures and low signal intensity foci, corresponding to calcifications.

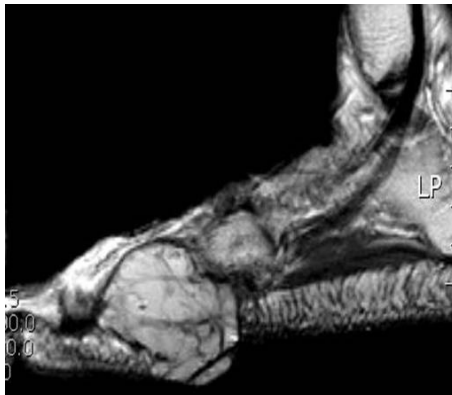B. Coronal T2-weighted image shows heterogeneous high signal intensity mass, reflecting the mixture of solid, cystic, fibrous and hemorrhagic elements.

C. Enhanced coronal T1-weighted image shows intense enhancement of the mass.

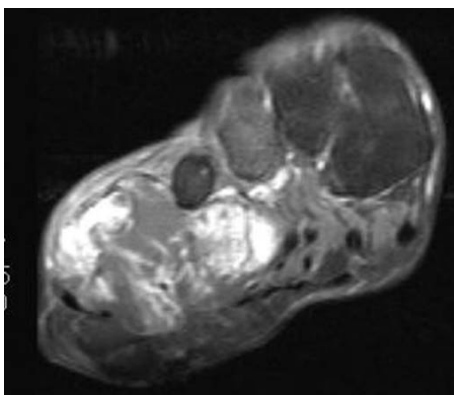
D. Sagittal T1-weighted image shows inhomogeneous signal intensity mass in the plantar aspect of the foot.



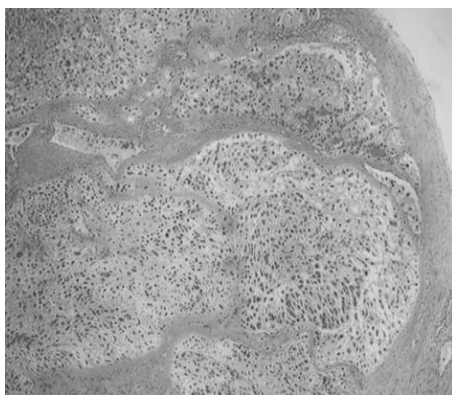
A



B



C



D

Fig. 8. Extraskeletal myxoid chondrosarcoma in a 77-year-old woman

A. Coronal T1-weighted image reveals a mass with poorly-defined intermediate signal intensity.

B. Sagittal T2-weighted image shows a lobulated mass with very high signal intensity portion and internal septae.

C. Coronal post-gadolinium T1-weighted image with fat suppression shows heterogeneous enhancement.

D. Photomicrograph ($\times 40$, H & E stain) shows multiple lobules and fibrous septae.

is difficult due to the absence of rhabdomyoblasts and the close resemblance to lesions of malignant fibrous histiocytoma and other pleomorphic sarcomas (3).

MR imaging shows nonspecific appearance, isointense to muscle on T1-weighted image, hyperintense on T2-weighted image, and marked enhancement on postcontrast image. Extremity alveolar rhabdomyosarcoma frequently shows prominent vascularity with serpentine high-flow vessels. Intralesional hemorrhage is also not unusual (3).

Synovial sarcoma

Synovial sarcoma is a well-recognized soft tissue malignancy, accounting for up to 10% of all malignant mesenchymal tumors. It is the fourth-most common soft tissue sarcoma after malignant fibrous histiocytoma, liposarcoma, and rhabdomyosarcoma. Almost 25% of all soft tissue sarcomas occur in the foot and ankle region. Synovial sarcoma is of mesenchymal origin, named for its histologic similarity to synovium (1). Since synovial sarcoma has no relationship to synovial tissue, an intra-articular location is very rare. It predominates in young adults between 20 and 40 years, typically arises in the neighborhood of tendons, tendon sheaths, and bursae, and is less frequently related to fasciae, aponeuroses and ligaments. Most synovial sarcomas present as palpable masses, but in some cases localized pain may precede the presence of a mass for many years. The prognosis is generally poor with a 5-year survival rate of 50 - 60% (8).

MR shows inhomogeneous signal intensity on T1- and T2-weighted images. The characteristic MR features are infiltrative margin, solid portions, septated areas of hemorrhage, and necrosis. Viable solid portion usually represents intense contrast enhancement. Calcifications within the tumor are frequent. MR appearance is also characterized by a peritendinous growth pattern. The tumors are commonly found in a juxta-articular location and are often large. However, particularly in smaller tumors, there is a reported tendency to present with well-defined margin and homogenous signal, possibly leading to the mistaken diagnosis of a benign lesion (1).

Extraskelatal myxoid chondrosarcoma

Extraskelatal myxoid chondrosarcoma is a rare malignant soft tissue tumor composed of abundant myxoid matrix and malignant chondroblastic cells (9). Extraskelatal chondrosarcomas are far less common than intraosseous chondrosarcomas, representing ap-

proximately 2% of all soft-tissue sarcomas. The histologic types of lesions are myxoid and mesenchymal. Extraskelatal myxoid chondrosarcoma is the most common histologic type of soft tissue chondrosarcoma (10). It predominates in adults aged 50 - 60 years, although patient ages range from 4 to 92 years (9). The vast majority of lesions are in the extremities, with the thigh being the single most common location. Pathologically, the lesions are usually surrounded by a fibrous capsule and contain fibrous septa that divide the lesion into multiple lobules, frequently with areas of cyst formation and hemorrhage. Calcification and bone formation are not typically present.

MR imaging shows a lobulated mass with hyperintense signal on T2-weighted image and variable signal on T1-weighted image. Extraskelatal myxoid chondrosarcoma, reflective of its extremely high water content, appears with very high signal intensity on T2-weighted MR image, with only mild peripheral to septal enhancement after contrast material administration (10).

Conclusion

Soft tissue masses in the foot are unusual. In this pictorial essay, we described MR imaging features of uncommon benign and malignant tumors in the foot. Correlation between the MR imaging and clinicopathologic appearance of these masses is also addressed. Unfortunately, the MRI features of a soft tissue mass are not always specific; however, there are cases where the diagnosis can be made or a clue provided to aid in the diagnosis.

References

1. Waldt S, Rechl H, Rummeny EJ, Woertler K. Imaging of benign and malignant soft tissue masses of the foot. *Eur Radiol* 2003;13: 1125-1136
2. Bos GD, Esther RJ, Woll TS. Foot tumors: diagnosis and Treatment. *J Am Acad Orthop Surg* 2002;10:259-270
3. Kransdorf MJ, Murphey MD. *Imaging of soft tissue tumors*. 2nd ed. Philadelphia: Lippincott Williams & Wilkins. 2006;299:312-321,386,563-565
4. Kransdorf MJ. Benign soft tissue tumors in a large referral population: distribution of specific diagnoses by ages, sex, and location. *AJR Am J Roentgenol* 1995;164:395-402
5. Ly JQ, Bui-Mansfield LT, SanDiego JW, Beaman NA, Ficke JR. Neural fibrolipoma of the foot. *J Comput Assist Tomogr* 2003;27: 639-640
6. Gray RJ, Pckaj BA, Vega ML, Connolly SM, DiCaudo DJ, Kile TA, et al. Diagnosis and treatment of malignant melanoma of the foot. *Foot Ankle Int* 2006;27:696-705

7. Suzuki Y, Ehara S, Shiraishi H, Nishida J, Murooka G, Tamakawa Y. Embryonal rhabdomyosarcoma of foot with expansive growth between metatarsals. *Skeletal Radiol* 1997;26:128-130
8. Nakanishi H, Araki N, Sawai Y, Kudawara I, Mano M, Ishigura S, et al. Cystic synovial sarcomas: imaging features with clinical and histopathologic correlation. *Skeletal Radiol* 2003;32:701-707
9. Tateishi U, Hasegawa T, Nojima T, Takegami T, Arai Y. MRI features of extraskeletal myxoid chondrosarcoma. *Skeletal Radiol* 2006;35:27-33
10. Murphey MD, Walker EA, Wilson AJ, Kransdorf MJ, Temple HT, Cannon FH. Imaging of primary chondrosarcoma: radiologic-pathologic correlation. *Radiographics* 2003;23:1245-1278

2007;56:585 - 592

