

Low-grade Osteosarcoma of the Spine: A Case Report¹

Young Chul Kim, M.D., Jin-Suck Suh, M.D., Myung In Kim, M.D.,
Hye-Jung Choo, M.D., Yong-Min Huh, M.D.

Low-grade osteosarcoma is not typically found in the long bone and pelvis. Most primary osteosarcomas that arise in the spine are high-grade malignancies. A low-grade osteosarcoma arising in the spine has not been previously described. We report here the clinical, radiological, and histological findings of a case of low-grade osteosarcoma that arose in the spine.

Index words : Osteosarcoma

Spine

Positron emission tomography (PET)

Low-grade osteosarcoma is a rare tumor that occurs mainly on the long bones such as the distal femur and proximal tibia. It may also develop in flat bones, such as ribs and craniofacial bones (1, 2). It is an unusual variant of an osteosarcoma, with a significantly better prognosis than a conventional osteosarcoma. It is characterized by slow growth, a low metastatic rate and prolonged survival after treatment. However, to the best of our knowledge there have been no reports on MR and positron emission tomography (PET) computed tomography (CT) findings for a low-grade osteosarcoma of the spine. We will describe the detailed radiologic findings for a low-grade osteosarcoma that is rarely encountered in spine imaging.

Case Report

A 48 year-old male complained of severe low back

pain that radiated to both lower extremities for a 5-month duration. A physical examination did not reveal any tenderness or other symptoms associated with this complaint. The alkaline phosphatase level (87 IU/L) was within the normal limit. All levels of serum tumor markers, including alfa feto protein (AFP), carcinoembryonic antigen (CEA), carbohydrate antigen 125 (CA 125) and carbohydrate antigen 19 - 9 (CA19 - 9) were within normal limits. Plain radiography of the lumbar spine did not reveal a bone lesion. CT showed a lytic bone lesion with sclerotic margins. The lesion involved the right pedicle and extended to the right transverse process and posterior vertebral body. The vertebral cortex invasion was visible (Fig. 1). A PET scan revealed a focus of FDG-tracer uptake along the L1 vertebra. MRI revealed an enhancing mass in the right posterior portion of the L1 vertebral body that involved the right pedicle and the transverse process (Fig. 2). The lesion showed low signal on sagittal T1-weighted images and strong enhancement on sagittal and axial T1-weighted post-contrast images. On sagittal T2-weighted images, the lesion exhibited predominantly low signal, but some areas of the posterior portion did exhibit some high signals. Following imaging assessment, the patient underwent a pediclectomy for tissue confirmation. The patient underwent

¹Department of Diagnostic Radiology, Severance Hospital, Research Institute of Radiological Science, Yonsei University College of Medicine, Seoul, South Korea.

Received January 2, 2007 ; Accepted February 12, 2007

Address reprint requests to : Young Chul Kim, M.D., Department of Diagnostic Radiology, Severance Hospital, Seodaemun-gu, Shinchondong 134, Seoul 120-752, South Korea

Tel. 82-2-2228-7400 Fax. 82-2-393-3035

E-mail: yochom@yumc.yonsei.ac.kr

regular follow-up without further treatment.

The histology of the tumor was described as spindle cell proliferation with woven and lamellar bone formation, resembling a fibrous dysplasia (Fig. 3). The tumor

was subsequently diagnosed as a low-grade osteosarcoma via microscopic correlation with the radiological findings.

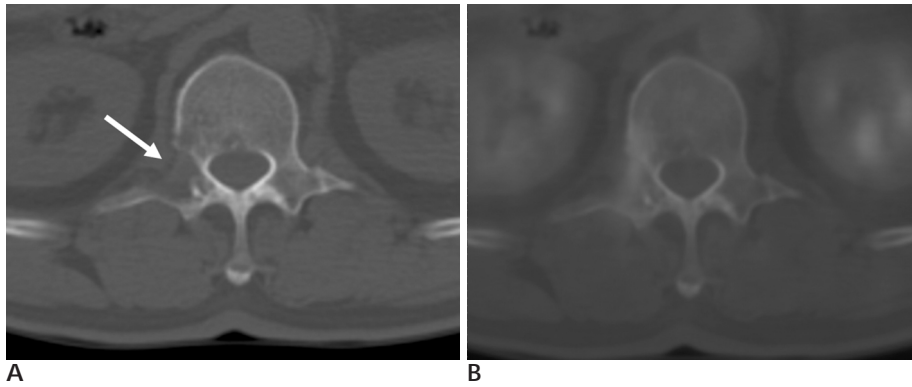


Fig. 1. CT (A), PET-CT fusion (B) images. (A) The CT scan shows the lytic lesion (white arrow) involving the pedicle and posterior body, as well as the right transverse process. The lateral cortex disruption is clearly seen. (B) Fusion images of PET and CT show that the focus of uptake corresponds to the bone destructive lesion in the L1 vertebra and Rt. transverse process. This indicates metabolic activity at the lesion.

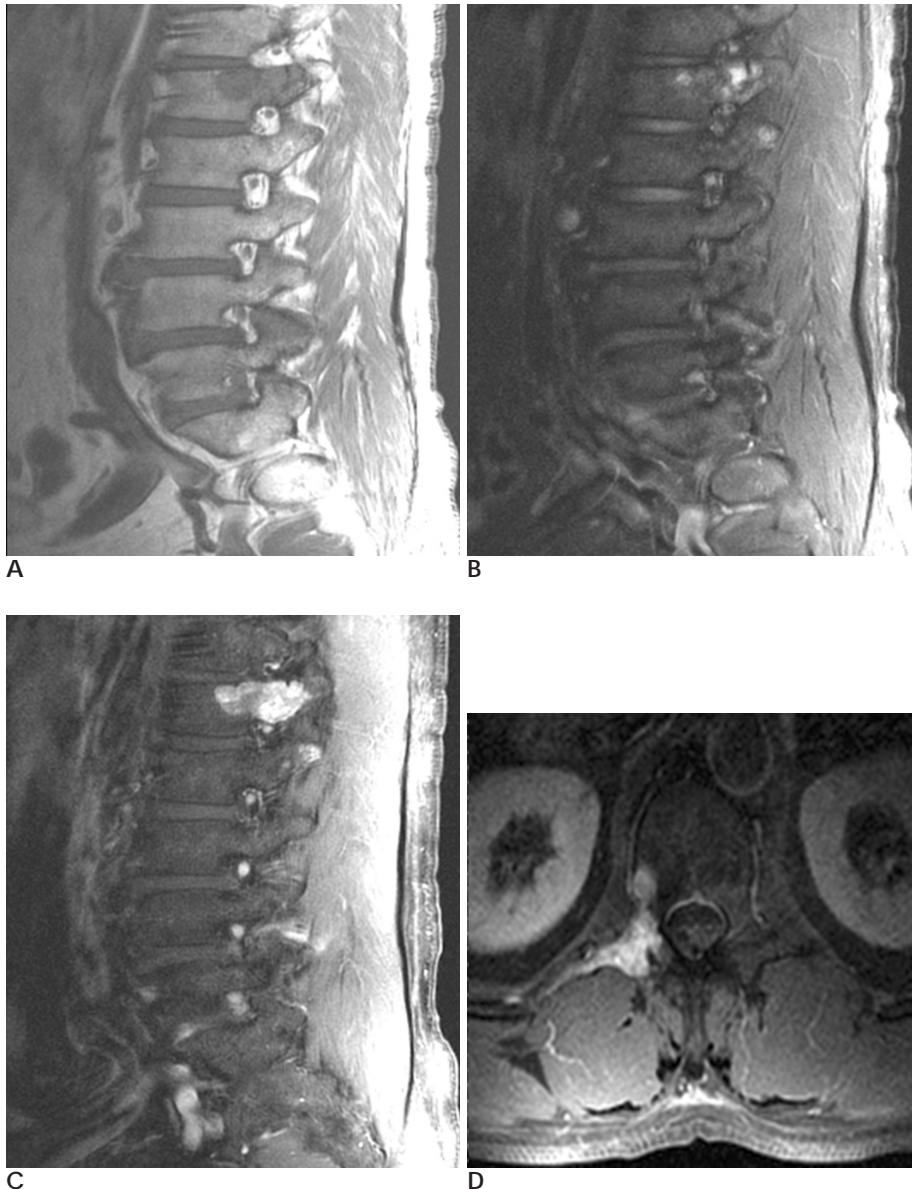


Fig. 2. MRI images (A - D). (A) The lesion shows intermediate signals on T1-weighted images and (B) heterogeneously mixed high and low signal on T2-weighted images. (C) On a post-contrast, sagittal (C) and (D) an axial T1-weighted image an intense enhanced mass centered in the L1 pedicle is seen, extending to the transverse process body and lamina. There was no protruding soft tissue mass.

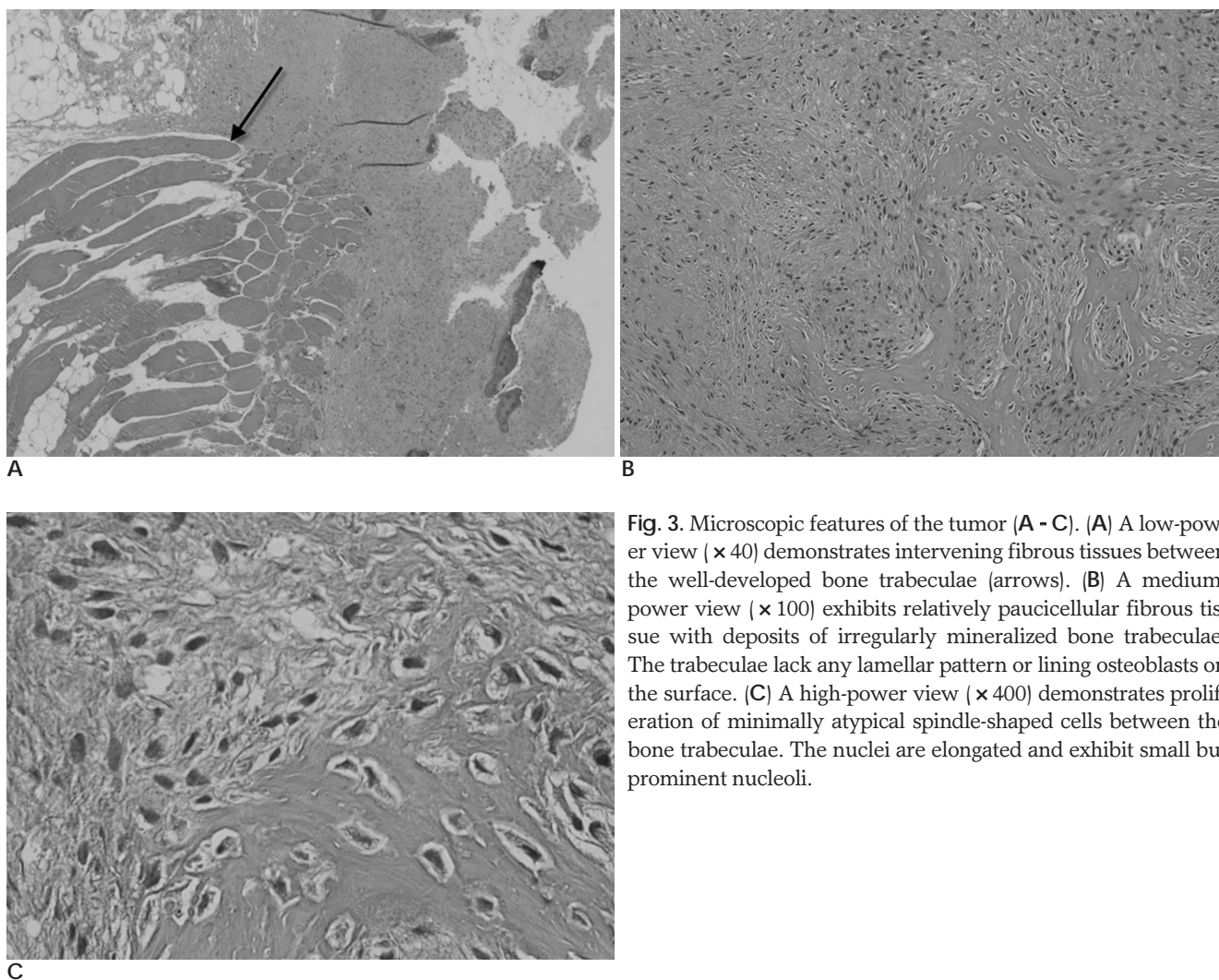


Fig. 3. Microscopic features of the tumor (A - C). (A) A low-power view ($\times 40$) demonstrates intervening fibrous tissues between the well-developed bone trabeculae (arrows). (B) A medium-power view ($\times 100$) exhibits relatively paucicellular fibrous tissue with deposits of irregularly mineralized bone trabeculae. The trabeculae lack any lamellar pattern or lining osteoblasts on the surface. (C) A high-power view ($\times 400$) demonstrates proliferation of minimally atypical spindle-shaped cells between the bone trabeculae. The nuclei are elongated and exhibit small but prominent nucleoli.

Discussion

Low-grade osteosarcoma is a rare tumor, the incidence ranging from 1 to 4 % of all osteosarcomas (3, 4). It shows a slight female predominance and occurs in the third or fourth decade of life. A low-grade osteosarcoma is typically located in the long bones, with a predilection for the distal femur and proximal tibia. These same locations are commonly affected for conventional high-grade osteosarcomas. Other bone involvement includes the other long bones (fibula, radius, humerus and ulna), short tubular bones (metatarsal bone, phalanx and clavicle) and flat bones (pelvis, rib and scapula) in rare cases (2, 3). However, no vertebral lesions have been reported previously (5). Of all primary malignant spinal tumors, osteosarcomas account for about 5% of cases. Furthermore, most primary osteosarcomas that arise in the spine are high-grade malignancies (6).

Pathologists occasionally experience difficulty in distinguishing low-grade osteosarcomas from fibrous dysplasia because their histological features overlap (7, 8). The histological features of this tumor were characterized by bundles of spindled cells with minimal cytological atypia, rare mitotic figures and a variable osteoid (7). This tumor may be frequently misdiagnosed as a fibrous dysplasia due to its minimal cytological atypia and rare mitotic figures (9). It is important to distinguish a low-grade osteosarcoma from a benign lesion, as although this tumor has a good prognosis, it poses a rare chance of recurrence when not properly eradicated by proper surgical measures (8).

Radiological findings of these tumors are variable and include sclerotic or heavily trabeculated matrix, intra-medullary involvement, localized cortical destruction, poor margins, and lack of new periosteal bone formation (5, 10). Recently, low-grade central osteosarcomas have been classified into four patterns in descending or-

der of frequency of radiological patterns: 1. lytic with varying amounts of coarse trabeculation; 2. predominantly lytic; 3. densely sclerotic; 4. mixed lytic and sclerotic without significant coarse trabeculation (5).

Most conventional osteosarcomas in the spine arise within the vertebral body, often eccentrically, and frequently extend into the posterior elements (11). However, the lesion in our case was centered at the right pedicle of the L1 vertebra, extending to the posterior body and the transverse process. CT and MRI are useful for evaluating cortical interruption and soft tissue mass formation that is suggestive of a malignancy rather than a benign lesion. Regardless of the presence of subtle mitotic figures and atypia, the features of cortical disruption or soft tissue mass seen on CT and MRI can help lead to a correct histological diagnosis. Despite the absence of a soft mass formation in this patient, a cortical interruption and increase of FDG uptake suggested a malignancy.

The differential diagnosis of this tumor includes osteoblastoma, giant cell tumor as well as fibrous dysplasia. The osteoblastoma may involve the posterior vertebral elements and frequently extends into the vertebral body. An edematous reaction within the adjacent bone marrow is seen for a osteoblastoma more frequently than for a osteosarcoma. Most of the giant cell tumors are found in the sacrum and third decades. Cystic areas as well as areas of previous hemorrhage with hemosiderin are also seen (6).

In conclusion, if aggressive radiographic findings often are subtle and the histological finding shows features of

fibrous dysplasia or another benign lesion, the possibility of low-grade osteosarcoma should be considered.

References

1. Vlychou M, Ostlere SJ, Kerr R, Athanasou NA. Low-grade osteosarcoma of the ethmoid sinus. *Skeletal Radiol* In press 2006
2. Yamaguchi T, Shimizu K, Koguchi Y, Saotome K, Ueda Y. Low-grade central osteosarcoma of the rib. *Skeletal Radiol* 2005;34:490-493
3. Bugnone AN, Temple HT, Pitcher JD. Low-grade central osteosarcoma of the foot and ankle: radiographic and pathologic features in two patients: case report and literature review. *Foot Ankle Int* 2005;26:494-500
4. Kenan S, Ginat DT, Steiner GC. Dedifferentiated high-grade osteosarcoma originating from low-grade central osteosarcoma of the fibula. *Skeletal Radiol* In press 2006
5. Andresen KJ, Sundaram M, Unni KK, Sim FH. Imaging features of low-grade central osteosarcoma of the long bones and pelvis. *Skeletal Radiol* 2004; 33:373-379
6. Erlemann R. Imaging and differential diagnosis of primary bone tumors and tumor-like lesions of the spine. *Eur J Radiol* 2006;58: 48-67
7. Fukunaga M. Low-grade central osteosarcoma of the skull. *Pathol Res Pract* 2005;201:131-135
8. Ogose A, Hotta T, Emura I, Imaizumi S, Takeda M, Yamamura S. Repeated dedifferentiation of low-grade intraosseous osteosarcoma. *Hum Pathol* 2000;31:615-618
9. Franceschina MJ, Hankin RC, Irwin RB. Low-grade central osteosarcoma resembling fibrous dysplasia. A report of two cases. *Am J Orthop* 1997;26:432-440
10. Ellis JH, Siegel CL, Martel W, Weatherbee L, Dorfman H. Radiologic features of well-differentiated osteosarcoma. *AJR Am J Roentgenol* 1988;151:739-742
11. Drevelegas A, Chourmouzi D, Boulogianni G, Sofroniadis I. Imaging of primary bone tumors of the spine. *Eur Radiol* 2003; 13:1859-1871

2007;56:575 - 578

