

pepper appearance) (Fig. 1A).

McCune Albright 가 , 가 (Fig. 1B, C).  
 , 가 (1). 1 - 1.5 cm 가  
 McCune Albright TI201  
 /Tc99m .

(adenomatous hyperplasia) .

(Fig. D).

46 가 5  
 . 16  
 10 .

(renal osteodystrophy)

10.7 mg/dL ( 8.2 - 10.2  
 mg/dL), 5.5 mg/dL( 2.5 - 4.5 mg/dL), alkaline  
 phosphatase 3388 IU/L( 96 - 254 IU/L),  
 3107 pg/mL( 15 - 65 pg/mL)  
 . 21 mg/dL,  
 3.85 mg/dL, 4.8 mg/dL, 5.1 mEq/L  
 (scout view)  
 , - (salt and  
 (osteoporosis), (osteosclerosis),  
 (osteomalacia),  
 (2). 1 -  
 hydroxylase 1,25 (OH)<sub>2</sub> - cholecalciferol  
 가 가 가  
 가 가 .  
 가 가 .

<sup>1</sup>가  
<sup>2</sup>가  
<sup>3</sup>가  
<sup>4</sup>가

2007 1 12 2007 4 10 .

(osteoclastic)  
 (subperiosteal), (cortical),  
 (subchondral), (trabecular), (endosteal),

(subligamentous)

가 가 ,

(2).

- (salt and pepper appearance)

ossea) (leontiasis (3 - 6).

(giant cell tumor), (Paget's disease)

가 2 - 3%  
가  
McCune Albright  
가

(4).

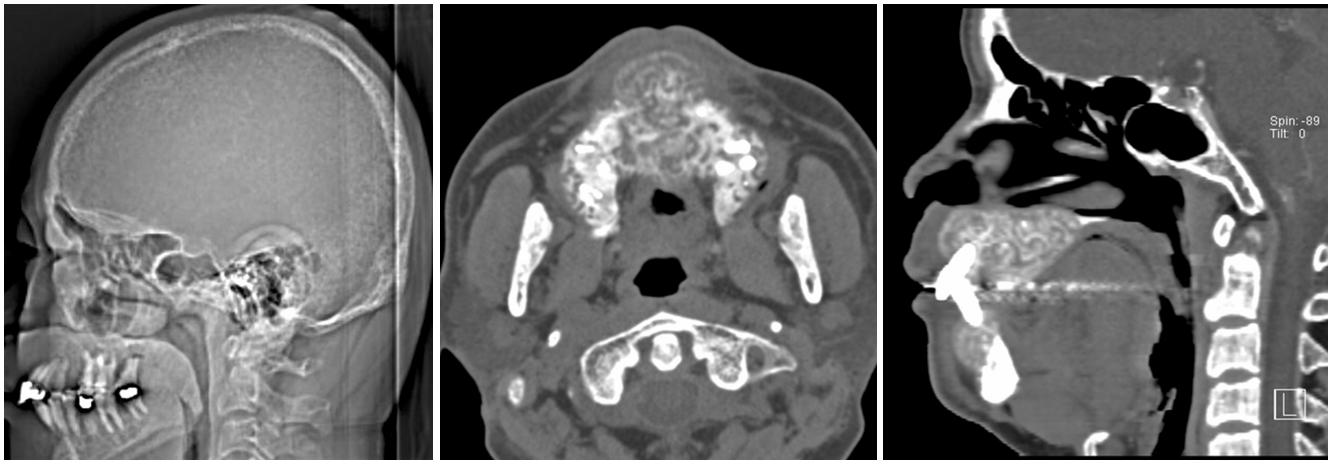
tumor) (brown (osteitis fibrosa cystica) (Cushing's syndrome)

(1).

(3 - 5), 1

가 (6).

Fraser (7) McCune Albright  
(parathyroid hormone related protein)



**Fig. 1.** Fibrous dysplasia of the jaws associated with secondary hyperparathyroidism in a 46-year-old man

**A.** Lateral CT scout scan shows loss of distinction between the inner and outer tables of the calvaria with a salt-and-pepper appearance.

**B, C.** Axial (**B**) and sagittal (**C**) CT scan displayed in bone window show expansile remodeling, cortical thinning lesion containing numerous unorganized bone trabeculae within the maxilla and mandible.

**D.** Photomicrography reveals characteristic metaplastic bone formation with no osteoblastic rimming and a proliferation of fibroblast, consistent with fibrous dysplasia (Hematoxylin-eosin stain,  $\times 100$ ).

**D**

Albright (8, 9).  
(bone - forming surface)  
(osteoblastic activity)

1. Murras N, Blizzard RM. The McCune-Albright syndrome. *Acta Endocrinol Suppl* 1986;279:207-217
2. Murphey MD, Sartoris DJ, Quale JL, Pathria MN, Martin NL. Musculoskeletal manifestations of chronic renal insufficiency.

- Radiographics 1993;13:357-379
3. Lee VS, Webb MS Jr., Martinez S, McKay CP, Leight GS Jr. Uremic leontiasis ossea: "bighead" disease in humans? Radiologic, clinical, and pathologic features. *Radiology* 1996;199:233-240
4. Aggunlu L, Akpek S, Coskun B. Leontiasis ossea in a patient with hyperparathyroidism secondary to chronic renal failure. *Pediatr Radiol* 2004;34:630-632
5. Taskapan H, Taskapan C, Baysal T, Sahin I, Ulu R, Karadag N, et al. Maxillary brown tumor and uremic leontiasis ossea in a patient with chronic renal insufficiency. *Clin Nephrol* 2004;61:360-363
6. Arik N, Biriken D, Akpolat T, Sungur C, Coskun C, Basoglu T, et al. Severe hyperparathyroidism associated with fibrous dysplasia: a case report. *Nephron* 1996;74:481-482
7. Fraser WD, Walsh CA, Birch MA, Durham B, Dillon JP, McCreavy D, et al. Parathyroid hormone-related protein in the aetiology of fibrous dysplasia of bone in the McCune Albright syndrome. *Clin Endocrinol* 2000;53:621-628
8. Braccini F, Bacciu A, Bruzzo M, Pech-Gourg F, Thomassin JM. Craniofacial fibrous dysplasia associated with primary hyperparathyroidism. *Acta Biomed Ateneo Parmense* 1999;70:5-11
9. Kim SJ, Seok JW, Kim IJ, Kim YK, Jung DS, Kim DS. Fibrous dysplasia associated with primary hyperparathyroidism in the absence of the McCune-Albright syndrome: Tc-99m MIBI and Tc-99m MDP findings. *Clin Nucl Med* 2003;28:416-418
10. Coburn JW, Henry DA. Renal osteodystrophy. *Adv Intern Med* 1984;30:387-424

# Fibrous Dysplasia of the Jaws Associated with Secondary Hyperparathyroidism: A Case Report<sup>1</sup>

Jung Hyun Whi, M.D., Young Joo Kim, M.D., Kyung Ah Chun, M.D., Ki Tae Kim, M.D., Eun Deok Chang, M.D.<sup>2</sup> Young Ok Kim, M.D.<sup>3</sup> Won Lee, M.D.<sup>4</sup>

<sup>1</sup>Department of Radiology, The Catholic University of Korea

<sup>2</sup>Department of Pathology, The Catholic University of Korea

<sup>3</sup>Department of Internal Medicine, The Catholic University of Korea

<sup>4</sup>Department of Dentistry, The Catholic University of Korea

There have been few reports on fibrous dysplasia associated with secondary hyperparathyroidism. We report a case of a hemodialysis patient with secondary hyperparathyroidism concomitant with fibrous dysplasia of the jaws causing an abnormal facial deformity.

**Index words :** Parathyroid, hyperparathyroidism  
Jaws

Address reprint requests to : Young Joo Kim, M.D., Department of Radiology, Uijongbu St. Mary's Hospital, The Catholic University of Korea  
65-1 Kumoh-dong, Uijongbu 480-130, Korea  
Tel. 82-31-820-3599 Fax. 82-31-846-3080 E-mail: violet2@catholic.ac.kr